This is a digital copy of a book that was preserved for generations on library shelves before it was carefully scanned by Google as part of a project to make the world's books discoverable online.

It has survived long enough for the copyright to expire and the book to enter the public domain. A public domain book is one that was never subject to copyright or whose legal copyright term has expired. Whether a book is in the public domain may vary country to country. Public domain books are our gateways to the past, representing a wealth of history, culture and knowledge that's often difficult to discover.

Marks, notations and other marginalia present in the original volume will appear in this file - a reminder of this book's long journey from the publisher to a library and finally to you.

Usage guidelines

Google is proud to partner with libraries to digitize public domain materials and make them widely accessible. Public domain books belong to the public and we are merely their custodians. Nevertheless, this work is expensive, so in order to keep providing this resource, we have taken steps to prevent abuse by commercial parties, including placing technical restrictions on automated querying.

We also ask that you:

+ *Make non-commercial use of the files* We designed Google Book Search for use by individuals, and we request that you use these files for personal, non-commercial purposes.

+ *Refrain from automated querying* Do not send automated queries of any sort to Google's system: If you are conducting research on machine translation, optical character recognition or other areas where access to a large amount of text is helpful, please contact us. We encourage the use of public domain materials for these purposes and may be able to help.

+ *Maintain attribution* The Google "watermark" you see on each file is essential for informing people about this project and helping them find additional materials through Google Book Search. Please do not remove it.

+ *Keep it legal* Whatever your use, remember that you are responsible for ensuring that what you are doing is legal. Do not assume that just because we believe a book is in the public domain for users in the United States, that the work is also in the public domain for users in other countries. Whether a book is still in copyright varies from country to country, and we can't offer guidance on whether any specific use of any specific book is allowed. Please do not assume that a book's appearance in Google Book Search means it can be used in any manner anywhere in the world. Copyright infringement liability can be quite severe.

About Google Book Search

Google's mission is to organize the world's information and to make it universally accessible and useful. Google Book Search helps readers discover the world's books while helping authors and publishers reach new audiences. You can search through the full text of this book on the web at `http://books.google.com/`

B 3 9015 00212 213 6
University of Michigan – BUHR

Digitized by Google



Digitized by Google

Digitized by Google



Digitized by Google

P3
S7
L8t

Digitized by Google

Digitized by Google

1235-1

TRANSACTIONS

OF THE

PATHOLOGICAL SOCIETY OF LONDON.

VOLUME THIRTEENTH.

COMPRISING THE REPORT OF THE PROCEEDINGS FOR THE SESSION 1861-62.

LONDON:

PRINTED FOR THE SOCIETY BY J. W. ROCHE, 6, KIRBY STREET.

1862.

Digitized by Google

The present publication, being the Thirteenth Volume of Transactions, constitutes the Sixteenth published Annual Report of the Pathological Society's proceedings.

The Council think it right to repeat, that the exhibitors are alone responsible for the descriptions given of the Specimens exhibited by them, the only change made in the Reports furnished by the authors being such verbal alterations as were absolutely necessary.

53, Berners Street, Oxford Street,
September, 1862.

Digitized by Google

TABLE OF CONTENTS

OF VOLUME XIII.

List of Presidents and of Officers and Members during the Session 1861-62 I

List of Specimens Exhibited during the Session 1861-62 . XIX

List of Plates XXXVII

List of Woodcuts XXXVIII

Diseases, etc., of the Nervous System 1

Diseases, etc., of the Organs of Respiration . . . 23

Diseases, etc., of the Organs of Circulation . . . 30

Diseases, etc., of the Organs of Digestion . . . 65

Diseases, etc., of the Genito-Urinary Organs . . . 126

Diseases, etc., of the Osseous System 173

Diseases, etc., of the Organs of Special Sense . . 211

Tumours, Cysts, etc. 213

Diseases, etc., of the Ductless Glands 241

Miscellaneous Specimens 250

Specimens from the Lower Animals 269

Index 275

Digitized by Google

Former Presidents.

ELECTED	
1846	CHARLES J. B. WILLIAMS, M.D., F.R.S.
1848	CHARLES ASTON KEY, Esq.
1850	PETER MERE LATHAM, M.D.
1852	CÆSAR H. HAWKINS, Esq., F.R.S.
1853	BENJAMIN GUY BABINGTON, M.D., F.R.S.
1855	JAMES MONCRIEFF ARNOTT, Esq., F.R.S.
1857	THOMAS WATSON, M.D., F.R.S.
1859	WILLIAM FERGUSSON, Esq., F.R.S.
1861	JAMES COPLAND, M.D., F.R.S.

Digitized by Google

OFFICERS AND COUNCIL

OF THE

Pathological Society of London,

ELECTED AT

THE GENERAL MEETING, JANUARY 1, 1862.

President.

JAMES COPLAND, M.D., F.R.S.

Vice-Presidents.

GEORGE HILARO BARLOW, M.D.
WILLIAM JENNER, M.D.
SIR JOHN LIDDELL, M.D., C.B., F.R.S.
THOMAS WATSON, M.D., F.R.S.
JOHN BIRKETT, ESQ.
WILLIAM COULSON, ESQ.
JAMES DIXON, ESQ.
ALEXANDER SHAW, ESQ.

Treasurer.

RICHARD QUAIN, M.D.

Council.

THOMAS A. BARKER, M.D.
GEORGE BUDD, M.D., F.R.S.
ANDREW CLARK, M.D.
WILLIAM D. CHOWNE, M.D.
GEORGE HARLEY, M.D.
WILLIAM O. MARKHAM, M.D.
CHARLES MURCHISON, M.D.
JOHN W. OGLE, M.D.
JAMES EDWARD POLLOCK, M.D.
HENRY HYDE SALTER, M.D., F.R.S.

RICHARD BARWELL, ESQ.
BERNARD E. BRODHURST, ESQ.
W. WHITE COOPER, ESQ.
WILLIAM H. FLOWER, ESQ.
J. GREGORY FORBES, ESQ.
JABEZ HOGG, ESQ.
TIMOTHY HOLMES, ESQ.
HENRY LEE, ESQ.
JOHN PYLE, ESQ.
SAMUEL J. A. SALTER, ESQ.

Honorary Secretaries.

JOHN S. BRISTOWE, M.D. | HENRY THOMPSON, ESQ.

Trustees.

THOS. BEVILL PEACOCK, M.D. | RICHARD QUAIN, M.D.
GEORGE POLLOCK, ESQ.

Digitized by Google

Digitized by Google

*** *Members are requested to indicate to the Secretaries corrections when necessary.*

LIST OF MEMBERS OF THE SOCIETY.

Honorary Members.

ANDRAL, G., M.D., Professor in the Faculty of Medicine, Paris.
CRUVEILHIER, J. C., M.D., Professor in the Faculty of Medicine, Paris.
HENLE, J., Professor of Anatomy and Physiology in the University of Zurich.
ROKITANSKY, CARL, M.D., Professor of Pathological Anatomy in the University of Vienna.
STOKES, WILLIAM, M.D., LL.D., F.R S., M.R.I.A., Regius Professor of Physic in the University of Dublin, Physician in Ordinary to the Queen in Ireland.
VOGEL, JULIUS, M.D., Professor of Clinical Medicine in the University of Giessen.

Resident and Non-Resident Members.

(C.) Present Members of Council.
† Have paid Composition Fee for Annual Subscriptions.
* Former Members of Council.
‡ Have paid Composition Fee for Transactions.

GENERAL LIST OF MEMBERS.

Elected Session.

1858-59 Acland, Henry Wentworth, M.D., F.R.S., Physician to the Radcliffe Infirmary, Oxford.
**Orig. Memb.* Adams, William, Esq., Surgeon to the Royal Orthopædic Hospital, 5, Henrietta-street, Cavendish-square.
1858-59 Adams, William, Esq., 37, Harrington-square.
1847-48 Aikin, Charles A., Esq., 7, Clifton-place, Sussex-square, Hyde-park.
1857-58 Alison, S. Scott, M.D., Physician to the Hospital for Consumption, Brompton, 80, Park-street, Grosvenor-square.
1859-60 Andrew, Edwyn, M.D., Windsor-house, Shrewsbury.
1857-58 Anstie, Francis E., M.D., Assistant-Physician to the Westminster Hospital, 15, Onslow-square, Brompton.
**Orig. Memb.* Arnott, James Moncrieff, Esq., F.R.S. (formerly President), 2, New Burlington-street.
1851-52 Ashton, T. J., Esq., 31, Cavendish-square.
1857-58 Avent, Nicholas, Esq., Modbury, Devonshire.

Digitized by Google

Elected Session

Orig. Memb. Babington, Benjamin Guy, M.D., F.R.S. (formerly President), 31, George-street, Hanover-square.

1856-57 Balding, Daniel Barley, Esq., Royston, Herts.

*1849-50 Ballard, Thomas, Esq., 10, Southwick-place, Hyde-park.

*1851-52 Barclay, A. Whyte, M.D., Physician to St. George's Hospital, 23A, Bruton-street, Berkeley-square.

1860-61 Barker, Edgar, Esq., Jun., 5, Albion-place, Hyde-park.

1855-56 Barker, T. A., M.D. (C.), Senior Physician to St. Thomas's Hospital, 71, Grosvenor-street.

Orig. Memb. Barker, Thomas Herbert, M.D., Harpur-place, Bedford.

Orig. Memb. Barlow, George Hilaro, M.D. (V.P.), Physician to Guy's Hospital, 5, Union-street, Southwark.

1852-53 Bartlett, William, Esq., Surgeon to the Kensington Dispensary, Ladbroke Lodge, Ladbroke-square, Notting-hill.

1852-53 Barwell, Richard, Esq. (C.), Assistant-Surgeon to the Charing Cross Hospital, 22, Old Burlington-street.

1857-58 Basham, William R., M.D., Senior Physician to the Westminster Hospital, 17, Chester-street, Grosvenor-place.

1861-62 Bastian, H. C., Esq., M.A., 14, Burton-crescent.

*1851-52 Beale, Lionel S., M.B., F.R.S., Physician to King's College Hospital, 61, Grosvenor-Street.

1855-56 Bealey, Adam, M.D., M.A., 27, Tavistock-square.

1852-53 Beck, Thomas Snow, M.D., F.R.S., 9A, Langham-place.

*1849-50 Beith, Robert, M.D., Deputy Inspector-General of Jamaica Hospitals.

1846-47 Bennet, James Henry, M.D., Physician-Accoucheur to the Royal Free Hospital, Weybridge, Surrey.

Orig. Memb. Bennett, James Risdon, M.D. (formerly V.P.), Physician to St. Thomas's Hospital and to the City of London Hospital for Diseases of the Chest, 15, Finsbury-square.

‡1856-57 Bickersteth, Edward R., Esq., Surgeon to the Liverpool Royal Infirmary, 2, Rodney-street, Liverpool.

*1848-49 Bird, James, M.D., Lecturer on Military Surgery at St. Mary's Hospital, 27, Hyde-park-square.

1855-56 Bird, W., Esq., Surgeon to the West of London Hospital and the St. George's and St. James's Dispensary, 24, George Street, Hanover-square.

*1849-50 Birkett, Edmund Lloyd, M.D., Physician to the City of London Hospital for Diseases of the Chest, 48, Russell-square.

Orig. Memb. Birkett, John, Esq., (V.P.), Surgeon to Guy's Hospital, 59, Green-street, Grosvenor-square.

1853-54 Black, Cornelius, M.D., Physician to the Chesterfield Dispensary, St. Mary's-gate, Chesterfield.

1849-50 Blagden, Robert, Esq., Stroud, Gloucestershire.

1859-60 Bloomenthal, Theodore, Esq., 13, Dorset-terrace, Clapham-road.

1855-56 Borham, W. H., Esq., 19, Cambridge-terrace, Hyde-park.

1861-62 Bower, Richard Norris, Esq., 14, Doughty-street, Mecklenburgh-square.

Digitized by Google

Elected Session

*1850-51 Bowman, William, Esq., F.R.S., Surgeon to the Royal Ophthalmic Hospital, 5, Clifford-street.

*1846-47 Brinton, William, M.D., Physician to St. Thomas's Hospital, 24, Brook-street, Grosvenor-square.

1856-57 Briscoe, John, Esq., 12, Broad-street, Oxford.

*†1850-51 Bristowe, John S., M.D. (Hon. Secretary), Physician to St. Thomas's Hospital, 3, St. Thomas's-street, Southwark.

1859-60 Broadbent, William Henry, M.B. Lond., Assistant-Physician to the London Fever Hospital, 23, Upper Seymour-street, Portman-square.

1851-52 Brodhurst, Bernard E., Esq. (C.), Assistant-Surgeon to the Royal Orthopædic Hospital, 20, Grosvenor-street.

*1846-47 Brooke, Charles, M.B., F.R.S., Surgeon to the Westminster Hospital, 16, Fitzroy-square.

**Orig. Memb.* Browne, Joseph Hullett, M.D., Physician to the St. Pancras Royal General Dispensary, 55, Gordon-square.

1854-55 Browne, Robert Cave, M.D., Armley-lodge, Barnet, Herts.

1859-60 Browning, Charles, Esq., 13A, Portsdown-road, Maida-hill.

1859-60 Browning, George, M.D., 10, St. Stephen's-crescent, Westbourne-park.

1855-56 Bryant, T., Esq., Assistant-Surgeon to Guy's Hospital, 2, Finsbury-square.

1854-55 Buchanan, George, M.D., Physician to the London Fever Hospital, and to the Hospital for Sick Children, 75, Gower-street, Bedford-square.

1861-62 Buchanan, Albert, Esq., M.B. Lond., 11A, Myddelton Square.

1858-59 Buckland, Francis, Esq., Surgeon to the 2nd Regiment of Life Guards, Windsor (Knightsbridge Barracks).

1858-59 Budd, George, M.D., F.R.S. (C.), 20, Dover-street, Piccadilly.

1850-51 Bullock, Henry, Esq., 61, Cumberland-street, Bryanston-square.

1859-60 Burton, Alfred, Esq., 13, Dover-street, Piccadilly.

1852-53 Burton, John M., Esq., Lee-park, Blackheath.

**Orig. Memb.* Busk, George, Esq., F.R.S. (late V.P.), Surgeon to the Seamen's Hospital-ship, "Dreadnought," 15, Harley-street, Cavendish-square.

*1856-57 Buzzard, Thomas, M.B., 41, Great Marlborough-street.

1856-57 Callender, G. W., Esq., Assistant-Surgeon to St. Bartholomew's Hospital, 47, Queen Anne-street, Cavendish-square.

†**Orig. Memb.* Camps, William, M.D., 40, Park-street, Grosvenor-square.

*1849-50 Canton, Edwin, Esq., Surgeon to the Charing Cross Hospital, 30, Montague-place, Russell-square.

‡1854-55 Carpenter, Alfred, Esq., M.D., High-street, Croydon.

1848-49 Carpenter, William Guest, Esq., Amersham, Bucks.

1861-62 Carr, William, Esq., F.R.C.S., Lee, Blackheath.

1855-56 Carter, H. V., M.D., Professor of Anatomy and Physiology, Grant Medical College, Bombay.

*1848-49 Chalk, William Oliver, Esq., 3, Nottingham-terrace, Regent's-park.

Digitized by Google

Elected Session

Orig. Memb. Chevers, Norman, M.D., India.

‡1858-59 Child, Gilbert W., M.D., Physician to the Radcliffe Infirmary, 61, St. Giles', Oxford.

1851-52 Childs, George Borlase, Esq., Surgeon to the Metropolitan Free Hospital, and to the City Police Force, 11, Finsbury-place South.

1854-55 Cholmeley, William, M.D., Physician to the Great Northern Hospital, 40, Russell-square.

1851-52 Chowne, William D., M.D. (C.), Physician to the Charing Cross Hospital, 8, Connaught-place West, Hyde-park.

1860-61 Clapton, Edward, M.D., 8, Wellington-street, London-bridge.

1853-54 Clark, Andrew, M.D. (C.), Assistant-Physician to the London Hospital, 23, Montague-place, Russell-square.

*1849-50 Clarke, John, Esq., L.R.C.P., Physician-Accoucheur to the British Lying-in Hospital, 42, Hertford-street, May-fair.

Orig. Memb. Cock, Edward, Esq. (late V.P.), Surgeon to Guy's Hospital, 11, St. Thomas's-street East, Borough.

1857-58 Cockerton, Richard, Esq., Surgeon to the Kensington Dispensary, 12, Petersham-terrace, Gloucester-road, South Kensington.

1855-56 Cockle, John, M.D., M.A., Physician to the Royal Free Hospital, 63, Brook-street, Hanover-square.

Orig. Memb. Cohen, Daniel Whitaker, M.D.

1858-59 Cooke, Robert Thomas, Esq., Surgeon to the Scarborough Dispensary, 15, St. Nicholas Cliff, Scarborough, Yorkshire.

1849-50 Cooper, George F., M.D., Surgeon to the Brentford Dispensary, Brentford.

1850-51 Cooper, William White, Esq. (C.), Ophthalmic Surgeon to St. Mary's Hospital, and Surgeon to the North London Eye Infirmary, 19, Berkeley-square.

Orig. Memb. Copland, James, M.D., F.R.S. (President), Consulting-Physician to the Royal Infirmary for Children, 5, Old Burlington-street.

1853-54 Cornish, William Robert, Esq.

1858-59 Coulson, Walter J., Esq., Assistant-Surgeon to the Lock Hospital, 34, Finsbury-circus.

Orig. Memb. Coulson, William, Esq. (V.P.), Senior Surgeon to St. Mary's Hospital, 1, Chester-terrace, Regent's-park.

1861-62 Couper, John, Esq., Assistant-Surgeon to the London Hospital, 33, Finsbury Circus.

1852-53 Cousins, Edward, Esq., 49, Camden-road-villas, Camden-town.

Orig. Memb. Crisp, Edwards, M.D., 278, King's-road, Chelsea.

*1848-49 Critchett, George, Esq. (formerly Honorary Secretary), Surgeon to the London Hospital, and Surgeon to the Royal London Ophthalmic Hospital, Moorfields, 46, Finsbury-square.

1855-56 Croft, John, Esq., Surgeon to the Surrey Dispensary, 4, St. Thomas's-street, Southwark.

1860-61 Crosby, Thomas Boor, Esq., 23, Finsbury-place.

1853-54 Cross, Robert, M.D., Physician to the Brewer's-court Dispensary, 20, New-street, Spring-gardens.

Digitized by Google

Elected Session

1857-58 Cumberbatch, Laurence T., Esq., 25, Cadogan-place, Sloane-street.

1854-55 Curgenven, J. Brendon, Esq., 11, Craven-hill-gardens, Bayswater.

*1854-55 Curling, Thomas Blizard, Esq., F.R.S., Surgeon to the London Hospital, and Examiner in Surgery at the University of London, 39, Grosvenor-street.

*Orig. Memb. Davies, Herbert, M.D., Consulting-Physician to the Infirmary for Asthma, &c., and Physician to the London Hospital, 23, Finsbury-square.

*1846-47 Davis, John Hall, M.D., Physician to the Royal Maternity Charity, 11, Harley-street, Cavendish-square.

‡1859-60 Davis, Francis William, Esq., R.N., 11 and 12, Love-lane, Aldermanbury.

*Orig. Memb. Day, George E., M.D., F.R.S., Chandos Professor of Anatomy in the University of St. Andrews.

1857-58 Delima, Teofilo, M.D., Caracas, South America.

1851-52 Devenish, Samuel Weston, M.B., 7, Billiter-square.

1861-62 Diamond, W. H., L.R.C.P., Edinb., Resident-Physician of the Lunatic Asylum, Brixton.

1855-56 Dick, H., M.D., 59, Wimpole-street, Cavendish-square.

1858-59 Dickinson, W. H., M.D., Curator of the Pathological Museum at St. George's Hospital, and Assistant-Physician to the Hospital for Sick Children, 11, Chesterfield-street, May-fair.

*Orig. Memb. Dixon, James, Esq. (V.P.), Surgeon to the Royal London Ophthalmic Hospital, Moorfields, 2, Portman-square.

1855-56 Druitt, R., L.R.C.P., Medical Officer of Health for St. George's, Hanover-square, 37, Hertford-street, May-fair.

1851-52 Drury, James Samuel, M.D., 13, Radnor-place, Hyde-park.

1846-47 Dudgeon, Robert E., M.D., 82, Gloucester-place, Portman-square.

1851-52 Duff, George, M.D., High-street, Elgin.

1860-61 Dunn, Robert William, Esq., 31, Norfolk-street, Strand.

1858-59 Durham, Arthur Edward, Esq., Assistant-Surgeon to Guy's Hospital, 30, Brook-street, Grosvenor-square.

1848-49 Eden, Thomas E., Esq., Surgeon-Dentist to the Farringdon General Dispensary, 45, Threadneedle-street.

1854-55 Edwards, George N., M.D., Assistant-Physician to St. Bartholomew's Hospital, and to the City of London Hospital for Diseases of the Chest, 1, Finsbury-square.

1846-47 Ellis, Joseph, Esq., Sudbrook-park, Richmond, Surrey.

*1846-47 Erichsen, John, Esq., Surgeon to University College Hospital, 6, Cavendish-place, Cavendish-square.

1853-54 Evans, Conway, M.D., Assistant-Physician to King's College Hospital, and Physician to the Public Dispensary, Lincoln's-inn.

‡1858-59 Ewens, John, Esq., Milton-Abbas, Blandford, Dorset.

Digitized by Google

Elected Session

1861-62 Farquharson, Robert, M.D., Assistant-Surgeon, Coldstream Guards.

*1847-48 Fergusson, William, Esq., F.R.S. (formerly V.P., late President), Surgeon to King's College Hospital, 16, George-street, Hanover-square.

*1846-47 Fincham, George T., M.D., Physician to the Westminster Hospital, 2, Eccleston-terrace South, Eccleston-square.

1853-54 Fisher, W. Webster, M.D., Downing Professor of Medicine, Cambridge.

1859-60 Fisher, Alexander, M.D., Assistant-Surgeon, R.N., Her Majesty's ship "Dragon," Chatham.

1855-56 Flower, William H., Esq. (C.), Conservator of the Museum, Royal College of Surgeons, Lincoln's-inn Fields.

1851-52 Forbes, J. Gregory, Esq. (C.), Surgeon to the Metropolitan Convalescent Institution, 9, Devonport-street, Hyde-park.

1849-50 Foreman, Robert Clifton, M.D., Resident Physician to the Asylum for Imbecile Children of the Upper Classes, Church-hill House, Brighton.

*†*Orig. Memb.* Forster, John Cooper, Esq., Assistant-Surgeon to Guy's Hospital, Surgeon to the Royal Infirmary for Children, 11, Wellington-street, Southwark.

1859-60 Foster, Michael, Jun., M.D., Huntingdon.

1858-59 Francis, Charles Richard, M.B., Bengal Medical Establishment, Indian Army.

1853-54 Freeman, William Henry, Esq., 21, Spring-gardens.

Orig. Memb. Frere, J. C., Esq., Trinity College, Cambridge.

*1846-47 Fuller, Henry W., M.D., Physician to St. George's Hospital, 13, Manchester-square.

‡1858-59 Gairdner, William Tennant, M.D., Physician to the Royal Infirmary, 45, Northumberland-street, Edinburgh.

1860-61 Galton, Robert Cameron, M.D. Camb., 48, Harley-street.

1855-56 Gamgee, Joseph Sampson, Esq., Surgeon to the Queen's Hospital, Birmingham, 20, Broad-street, Birmingham.

1855-56 Gamgee, J., Esq., New Veterinary College, Edinburgh.

1850-51 Garrett, Mark Brown, Esq., 3, New-road, St. George's East.

*1846-47 Garrod, Alfred Baring, M.D., F.R.S., Physician to University College Hospital, 84, Harley-street, Cavendish-square.

1858-59 Gascoyen, George Green, Esq., Assistant-Surgeon to the Lock Hospital, and Lecturer on Anatomy at St. Mary's Hospital, 48, Queen Anne-street, Cavendish-square, W.

1855-56 Gaskoin, George, Esq., 3, Westbourne-park, Paddington.

**Orig. Memb.* Gay, John, Esq., Senior Surgeon to the Great Northern Hospital, King's-cross, 10, Finsbury-place South.

1854-55 Gibb, George Duncan, M.D., F.G.S., Physician to the West London Hospital, 19A, Portman-street, Portman-square.

1853-54 Gibbon, Septimus, M.D., 3, Finsbury-square.

‡1857-58 Godfrey, Benjamin, M.D., Carlton-house, Enfield.

Digitized by Google

Elected Session

1854-55 Goodfellow, Stephen Jennings, M.D., Physician to the Middlesex Hospital, 5, Savile-row, Burlington-gardens.

1856-57 Goolden, R. H., M.D., Physician to St. Thomas's Hospital, 41, Sussex-gardens, Hyde-park.

1857-58 Gowlland, Peter Y., Esq., 34, Finsbury-square.

1846-47 Gream, George T., M.D., 2, Upper Brook-street, Grosvenor-square.

1856-57 Greenhalgh, Robert, M.D., Physician-Accoucheur to St. Bartholomew's Hospital, Physician to the Samaritan Free Hospital for Women and Children, 76, Grosvenor-street.

‡1854-55 Greenhill, William Alexander, M.D., Carlisle-parade, Hastings.

1860-61 Gueneau de Mussy, Henri, M.D., 4, Cavendish-place, Regent-street.

1858-59 Gunn, Theophilus Miller, Esq., 40, York-place, Portman-square.

1851-52 Hacon, E. Dennis, Esq., Mare-street, Hackney.

†1851-52 Halley, Alexander, M.D., 7, Harley-street, Cavendish-square.

1851-52 Hansard, Richard James, Esq., 25, North Audley-street, Grosvenor-square

*1847-48 Hare, Charles John, M.D., Physician to University College Hospital, 41, Brook-street, Grosvenor-square.

†1855-56 Harley, George, M.D. (C.), Professor of Medical Jurisprudence in University College, London, 77, Harley-street.

1859-60 Harris, Francis, M.D., Assistant-Physician to St. Bartholomew's Hospital, and to the Hospital for Sick Children, 24, Cavendish-square.

†1857-58 Hart, Ernest, Esq., Junior Surgeon to the North London Ophthalmic Infirmary, 69, Wimpole-street.

†1859-60 Hastings, Cecil William, M.B., Demonstrator of Anatomy at St. George's Hospital, 7, Hertford-street, May-fair.

**Orig. Memb.* Hawkins, Cæsar H., Esq., F.R.S. (formerly President), Consulting-Surgeon to St. George's Hospital, 26, Grosvenor-street.

1856-57 Hawksley, Thos., M.D., Physician to the Margaret-street Dispensary for Consumption, 26, George-street, Hanover-square.

1856-57 Heath, Christopher, Esq., Assistant-Surgeon to the Westminster Hospital, 31, Sackville-street, Piccadilly.

1861-62 Henderson, Joseph, Esq., Deptford.

*1848-49 Henry, Mitchell, Esq. (formerly Hon. Secretary), Surgeon to the Middlesex Hospital, and to the North London Eye Infirmary, 5, Harley-street, Cavendish-square.

**Orig. Memb.* Hewett, Prescott G., Esq. (formerly V.P.), Surgeon to St. George's Hospital, 1, Chesterfield-street, May-fair.

1854-55 Hewitt, Graily, M.D., Physician to the British Lying-in-Hospital, and Lecturer on Midwifery and Diseases of Children at St. Mary's Hospital, 36, Berkeley-square.

1859-60 Hill, Matthew Berkeley, M.B. Lond., Heath-house, Stapleton, Bristol.

1854-55 Hillier, Thomas, M.D., Physician to the Hospital for Sick Children, Medical Officer of Health for St. Pancras, 21, Upper Gower-street, Bedford-square.

Digitized by Google

Elected Session

*Orig. Memb. Hillman, William Augustus, Esq., Senior Assistant-Surgeon to the Westminster Hospital, 1, Argyll-street, Regent-street.

*Orig. Memb. Hilton, John, Esq., F.R.S., Surgeon to Guy's Hospital, 10 New Broad-street, City.

1855-56 Hinton, J., Esq., 9, Philip-terrace, Tottenham.

*1850-51 Hodgson, Joseph, Esq., F.R.S., 60, Westbourne-terrace.

1852-53 Hogg, Jabez, Esq. (C.), Assistant-Surgeon to the Westminster Ophthalmic Hospital, 1, Bedford-square.

1846-47 Holman, H. Martin, M.D., Hurstpierpoint, Sussex.

1854-55 Holmes, Timothy, Esq. (C.), Assistant-Surgeon to St. George's Hospital, and Surgeon to the Hospital for Sick Children, 22, Queen-street, May-fair.

*1849-50 Holt, Barnard Wight, Esq., Senior Surgeon to the Westminster Hospital, 14, Savile-row.

*Orig. Memb. Holthouse, Carsten, Esq., Surgeon to, and Lecturer on Anatomy at the Westminster Hospital, 2, Storey's Gate, St. James's Park.

1853-54 Hood, William Charles, M.D., Resident Physician, Bethlem Hospital.

1858-59 Hooper, W., Esq., late Resident Assistant Obstetric Officer at St. George's Hospital.

1850-51 Hore, Henry A., Esq., Surgeon to the Bristol Royal Infirmary, 31, Park-street, Bristol.

1857-58 Hornidge, Thomas King, Esq., 15, Charles-street, Westbourne-terrace.

†1855-56 Hudson, John, M.D., 11, Cork-street.

1854-55 Hulke, John Whitaker, Esq., Assistant-Surgeon to the Middlesex Hospital, 10, Old Burlington-street.

1854-55 Hulme, Edward Charles, Esq., Surgeon to the Central London Ophthalmic Hospital, 19, Gower-street, Bedford-square.

1852-53 Humby, Edwin, Esq., 83, Hamilton-terrace, St. John's-wood.

*1852-53 Hutchinson, Jonathan, Esq., Assistant-Surgeon to the London Hospital, and to the Royal London Ophthalmic Hospital, Moorfields, Surgeon to the Metropolitan Free Hospital, 4, Finsbury-circus.

†1860-61 Ingram, Charles, M.D., Physician to the Royal General Dispensary, Aldersgate, 11, New Cavendish-street, Portland-place.

‡1856-57 Jackson, Henry, Esq., Senior Surgeon to the Sheffield Infirmary, St. James's-row, Sheffield.

1859-60 Jackson, Thomas Carr, Esq., Surgeon to the Great Northern Hospital, 3, Weymouth-street, Portland-place.

‡1853-54 Jardine, John Lee, Esq., Capel, near Dorking, Surrey.

1846-47 Jay, Edward, Esq., 51, Park-street, Grosvenor-square.

*Orig. Memb. Jeaffreson, Henry, M.D. (formerly V.P.), Physician to St. Bartholomew's Hospital, and Consulting Physician to the City of London Hospital for Diseases of the Chest, 8, Finsbury-square.

Digitized by Google

Elected Session

Orig. Memb. Jenner, William, M.D. (V.P.), Physician to the Hospital for Sick Children, and to University College Hospital, 8, Harley-street.

1861-62 Jephson, John Holmes, M.D., Physician to the Great Northern Hospital, 1, Conduit-street West, Hyde-park.

1854-55 Johnson, Athol A. W., Esq., 20, Regency-square, Brighton.

1854-55 Johnson, Edward, M.D., 19, Cavendish-place, Cavendish-square.

Orig. Memb. Johnson, George, M.D., Physician to King's College Hospital, 11, Savile-row.

*1846-47 Johnson, Henry Charles, Esq., Surgeon to St. George's Hospital, 6, Savile-row.

*†*Orig. Memb.* Jones, Henry Bence, M.D., F.R.S. (formerly V.P.), 31, Brook-street, Grosvenor-square.

1853-54 Jones, Sydney, M.B., Assistant-Surgeon to St. Thomas's Hospital, 15, St. Thomas's-street.

1861-62 Jones, Thomas, Esq., St. George's Hospital.

1858-59 Jones, William Price, M.D., Surbiton, Kingston.

1859-60 Jones, Walter, Esq., College-yard, Worcester.

1861-62 Junker, Ferdinand Ethelbert, M.D., 56, Gower-street, Bedford-square.

1846-47 Kent, Thomas J., Esq., 27, Holles-street, Cavendish-square.

1852-53 Kershaw, W. Wayland, M.D., Kingston-on-Thames.

1859-60 Kiallmark, Henry Walter, Esq., 46, Princes-square, Westbourne-grove.

1851-52 Kingdon, J. Abernethy, Esq., Surgeon to the City Dispensary, and to the City of London Truss Society, 2, New Bank-buildings.

‡1856-57 Kingsley, Henry, M.D., Physician to the Stratford Infirmary, Stratford-on-Avon, Warwickshire.

1854-55 Kirby, Edmund A., M.D., 1, Taviton-street, Gordon-square.

1854-55 Kirkes, William Senhouse, M.D., Assistant-Physician to St. Bartholomew's Hospital, 2, Lower Seymour-street.

*1850-51 Langmore, John C., M.B., 20, Oxford-terrace, Hyde-park.

1857-58 Lankester, Edwin, M.D., F.R.S., Medical Officer of Health for St. James's, Westminster, 8, Savile-row.

*1849-50 Latham, Peter Mere, M.D. (formerly President), late Physician to St. Bartholomew's Hospital, 36, Grosvenor-street.

1856-57 Laurence, John Z., Esq., Surgeon to the St. Marylebone General Dispensary, 30, Devonshire-street, Portland-Place.

1853-54 Lawrence, Henry John Hughes, Esq., Assistant-Surgeon, Grenadier Guards (St. John's-wood Barracks).

1858-59 Lawson, George, Esq., Assistant-Surgeon to the Royal London Ophthalmic Hospital, Moorfields, Surgeon to the Great Northern Hospital, 63, Park-street, Grosvenor-square.

1857-58 Leared, Arthur, M.B., Physician to the Royal Infirmary for Diseases of the Chest, 12, Old Burlington-street.

1851-52 Lee, Henry, Esq. (C.), Assistant-Surgeon to St. George's Hospital, and Senior Surgeon to the Lock Hospital, 9, Savile-row.

Digitized by Google

Elected Session

1852-53 Leggatt, Alfred, Esq., 13, William-street, Lowndes-square.

1861-62 Lichtenberg, George, M.D., 10, Finsbury-place.

*1849-50 Liddell, Sir John, C.B., M.D., F.R.S. (V.P.), Director-General of the Medical Department of the Navy, 72, Chester-square, Belgravia.

*1848-49 Little, William John, M.D. (formerly V.P.), Physician to the London Hospital, 34, Brook-street, Grosvenor-square.

‡1860-61 Lund, George, M.D., Madeira.

1858-59 Mackay, Allan Douglas, M.B., Stony-Stratford, Bucks.

1857-58 Marcet, William, M.D., Assistant-Physician to the Westminster Hospital, 4, George Street, Hanover Square.

1851-52 Markham, William O., M.D. (C.), Physician to St. Mary's Hospital, 33, Clarges-street, Piccadilly.

*1846 47 Marshall, John, Esq., F.R.S., Surgeon to University College Hospital, 10, Savile-row.

‡1860-61 Martin, John, Esq., Cambridge House, Portsmouth, and Keydell, near Horndean, Hants.

1856-57 Martin, Robert, M.D., Assistant-Physician to St. Bartholomew's Hospital, 19, Queen Anne-street.

1852-53 Martyn, S., M.D., Senior Physician to the Bristol General Hospital, 26, Park-Street, Bristol.

1858-59 Martyn, William, Esq., 6, Trevor-terrace, Rutland-gate, Brompton.

1860-61 Mason, Francis, Esq., Assistant-Surgeon to King's College Hospital, 10, Conduit-street.

†1858-59 Maunder, C. F., Esq., Assistant-Surgeon to the London Hospital, 29, New Broad-street.

‡1851-52 May, George, Junr., M.B., Surgeon to the Royal Berkshire Hospital, Reading.

1857-58 Meller, Charles James, Esq.

1859-60 Messer, John Cockburn, M.D., Assistant-Surgeon, R.N., Her Majesty's ship "Edinburgh," Queensferry, N.B.

1854-55 Miles, Charles, Esq., 13, Conduit-street West, Hyde-park.

1858-59 Montefiore, Nathaniel, Esq., 36, Hyde-park-gardens.

1860-61 Montgomery, Edmund, M.D., St. Thomas's Hospital.

1861-62 Morehead, Charles, M.D., 20, Chapel-street, Grosvenor-square.

*1846-47 Morgan, John, Esq., 3, Sussex-place, Hyde-park-gardens.

1852-53 Moseley, George, Esq., 23, Priory-road, Kilburn.

1859-60 Moxon, Walter, M.B., Demonstrator of Anatomy at Guy's Hospital, 6, Finsbury-circus.

1854-55 Murchison, Charles, M.D. (C.), Assistant-Physician to the Middlesex Hospital, and Senior Physician to the London Fever Hospital, 79, Wimpole-street.

Mussy, *see* Gueneau de Mussy.

1860-61 Nelson, Duckworth John, Esq., 7, Marlborough-road, St. John's-wood.

1856-57 Nunn, Thomas William, Esq., Assistant-Surgeon to the Middlesex Hospital, 8, Stratford-place, Oxford-street.

Digitized by Google

Elected Session

‡1858-59 Nunneley, Thomas, Esq., Senior Surgeon to the Leeds Eye and Ear Infirmary, Leeds.

*1850-51 Obré, Henry, Esq., Surgeon to the St. Marylebone Eye and Ear Institution, 1, Melcombe-place, Dorset-square.

1852-53 O'Connor, William, M.D., Physician to the Royal Free Hospital, 30, Upper Montagu-street, Montagu-square.

*1850-51 Ogle, John W., M.D. (C., late Hon. Secretary), Assistant-Physician to St. George's Hospital. 13, Upper Brook-street, Grosvenor-square.

‡1855-56 Oldfield, Edmund, Esq., Boscomb Lodge, Finchley-road.

1859-60 Orange, William, Esq., Surrey County Lunatic Asylum, near Tooting.

1857-58 Ord, William Miller, M.B., Lecturer on Comparative Anatomy, at St. Thomas's Hospital, Brixton-hill.

‡1859-60 Paget, Edward H., Esq., Friar-lane, Leicester.

1853-54 Parkinson, George, Esq., 16, Hereford-street, Park-lane.

1853-54 Part, James, M.D., 7, Camden-road-villas, Camden-town.

**Orig. Memb.* Partridge, Richard, Esq., F.R.S.(formerly V.P.), Surgeon to King's College Hospital, 17, New-street, Spring-gardens.

**Orig. Memb.* Peacock, Thomas Bevill, M.D. (late V.P. and Hon. Secretary), Physician to St. Thomas's Hospital, and Physician to the City of London Hospital for Diseases of the Chest, 20, Finsbury-circus.

1860-61 Pocock, William, Esq., 1, St. John's-villas, Brixton-road.

**Orig. Memb.* Poland, Alfred, Esq., Surgeon to Guy's Hospital, and to the Eye Infirmary attached, 10, Bolton-row, Curzon-street, May-fair.

*1846-47 Pollock, George D., Esq. (formerly Hon. Secretary), Surgeon to St. George's Hospital, 27, Grosvenor-street.

1850-51 Pollock, James Edward, M.D. (C.), Physician to the Hospital for Consumption and Diseases of the Chest, Brompton, 52, Upper Brook-street.

1861-62 Pollock, Arthur Julius, M.D., 21, Montague-place, Russell-square.

1858-59 Potter, Henry, Esq., 56, Maddox-street, Hanover-square.

1854-55 Potts, William, Esq., 12, North Audley-street, Grosvenor-square.

1856-57 Price, Peter Charles, Esq., Surgeon to the Great Northern Hospital, King's-cross, and to the Metropolitan Institution for Scrofulous Children, at Margate, 7, Green-street, Grosvenor-square.

1856-57 Priestley, William Overend, M.D., Physician-Accoucheur to the Middlesex Hospital, and to the St. Marylebone Infirmary, 17, Hertford-street, May-fair.

*†1848-49 Purnell, John James, Esq., Surgeon to the Royal General Dispensary, Woodlands, Streatham-hill.

1850-51 Pyle, John, Esq. (C.), 56, Oxford-terrace, Hyde-park.

**Orig. Memb.* Quain, Richard, M.D. (Treasurer, formerly Hon. Secretary), Physician to the Hospital for Consumption and Diseases of the Chest, Brompton, 56, Harley-street, Cavendish-square.

Digitized by Google

Elected Session

1859-60 Radcliffe, Charles Bland, M.D., Physician to the Westminster Hospital, 4, Henrietta-street, Cavendish-square.

1855-56 Rae, James, Esq., Surgeon, R.N., Haslar Hospital.

**Orig. Memb.* Ramsbotham, Francis H., M.D. (formerly V.P.), Physician-Accoucheur to the London Hospital, 8, Portman-square.

1856-57 Ramskill, J. Spence, M.D., Physician to the National Hospital for the Paralysed and Epileptic, 5, St. Helen's-place, Bishopsgate-street.

1847-48 Randall, John, M.D., Medical Officer, St. Marylebone Infirmary, 14, Portman-street, Portman-square.

1856-57 Ranke, Henry, M.D., Munich.

1846-47 Ray, Edward, Esq., Dulwich.

1858-59 Reed, Frederick George, M.D., 46, Hertford-street, May-fair.

1854-55 Reynolds, J. Russell, M.D., Physician to University College Hospital, 38, Grosvenor-street.

**Orig. Memb.* Ridge, Joseph, M.D., 39, Dorset-square.

1855-56 Roberts, John Henry, Esq., 10, Finchley-road, St. John's-wood.

1856-57 Robinson, Thomas, M.D., 64, Lamb's Conduit-street.

1859-60 Robinson, Frederick, M.D., Battalion Surgeon, Scots Fusilier Guards, Wellington Barracks.

**Orig. Memb.* Roe, George Hamilton, M.D., Senior Physician to the Hospital for Consumption and Diseases of the Chest, Brompton, 57, Park-street, Grosvenor-square.

1858-59 Rolleston, George, M.D., F.R.S., 5, Broad-street, Oxford.

1851-52 Rooke, H. T., M.D., Surgeon to the Seamen's Hospital-ship, "Dreadnought."

1858-59 Rose, Henry Cooper, Esq., High-street, Hampstead.

1858-59 Rouse, James, Esq., Assistant-Surgeon to the Royal Ophthalmic Hospital, 56, Maddox-street, Hanover-square.

1860-61 Rutter, Joseph, Esq., West-Hill, Wandsworth.

1852-53 Salter, Henry Hyde, M.D., F.R.S. (C.), Assistant-Physician to the Charing-cross Hospital, 6, Montague-street, Russell-square.

1853-54 Salter, Samuel James A., M.B. (C.), Surgeon-Dentist to Guy's Hospital, 17, New Broad-street, City.

1852-53 Sanderson, Hugh James, M.D., Physician to the Hospital for Women, 26, Upper Berkeley-street.

1854-55 Sanderson, John Burdon, M.D., Assistant-Physician to the Hospital for Consumption, Medical Officer of Health for Paddington, 9, Gloucester-place, Hyde-park.

1857-58 Schulhof, Maurice, M.D., Physician to the Royal General Dispensary, Bartholomew-close, 14, Brook-street.

1853-54 Scott, John, Esq., Surgeon to the Hospital for Women, Soho-square, 65, Harley-street, Cavendish-square.

‡1858-59 Scratchley, George, M.D., B.L.S., Member of the University of France, New Orleans, Louisiana, U.S.

*1846-47 Seaton, Edward C., M.D., Rochester-house, Surbiton.

Digitized by Google

Elected Session

1856-57 Sedgwick, William, Esq., Surgeon to the St. Marylebone Provident Dispensary, 12, Park-place, Upper Baker-street.

*1852-53 Semple, Robert Hunter, M.D., Physician to the Northern Dispensary, 8, Torrington-square.

**Orig. Memb.* Shaw, Alexander, Esq. (V.P., formerly Treasurer), Surgeon to the Middlesex Hospital, 22A, Cavendish-square.

1856-57 Shillitoe, Buxton, Esq., Surgeon to the Islington Dispensary, 34, Finsbury-circus.

1855-56 Sibley, Septimus W., Esq., Medical Registrar to the Middlesex Hospital, 12, New Burlington-street.

*1848-49 Sibson, Francis, M.D., F.R.S., Physician to St. Mary's Hospital, 40, Brook-street, Grosvenor-square.

*1847-48 Sieveking, Edward H., M.D., Physician to St. Mary's Hospital, 17, Manchester-square.

**Orig. Memb.* Simon, John, Esq., F.R.S. (formerly V.P.), Surgeon to St. Thomas's Hospital, 44, Cumberland-street, Bryanston-square.

**Orig. Memb.* Smith, Ebenezer Pye, Esq., 7, Billiter-square.

1854-55 Smith, Edward, M.D., F.R.S., Assistant-Physician to the Hospital for Consumption and Diseases of the Chest, Brompton, 16, Queen Anne-street, Cavendish-square.

1846-47 Smith, Protheroe, M.D., Physician to the Hospital for Women, 25, Park-street, Grosvenor-square.

1851-52 Smith, W. Tyler, M.D., Physician-Accoucheur to St. Mary's Hospital, 7, Upper Grosvenor-street.

1855-56 Smith, Spencer, Esq., Surgeon to St. Mary's Hospital, 48, Sussex-gardens, Hyde-park.

1856-57 Smith, Thomas, Esq., Surgeon to the Great Northern Hospital, 9, Bedford-row.

1854-55 Squire, William, Esq., 6, Orchard-street, Portman-square.

1860-61 Squire, Alexander Balmanno, Esq., 12, York-gate, Regent's-park.

*1847-48 Solly, Samuel, Esq., F.R.S., Surgeon to St. Thomas's Hospital, 18, St. Helen's-place, Bishopsgate-street.

1857-58 Stallard, Joshua Harrison, L.R.C.P., 2, Buckingham-villas, Ladbroke-road, Notting-hill.

1854-55 Stewart, William Edward, Esq., Surgeon to St. Marylebone Provident Dispensary, 12, Weymouth-street, Portland-place.

†1853-54 Streatfeild, J. F., Esq., Assistant-Surgeon to the Royal London Ophthalmic Hospital, Moorfields, and to the Eye Infirmary in University College Hospital, 15, Upper Brook-street.

†1850-51 Sutherland, Alexr. John, M.D., F.R.S., 6, Richmond-terrace, Whitehall.

1858-59 Swete, Benjamin L., Esq., Surgeon to the British Orphan Asylum, Clapham-rise, 7, Park-road, Stockwell.

‡1856-57 Symonds, Frederick, Esq., Surgeon to the Radcliffe Infirmary, 32, Beaumont-street, Oxford.

Orig. Memb. Tamplin, R. W., Esq., Surgeon to the Royal Orthopædic Hospital, 33, Old Burlington-street.

Digitized by Google

Elected Session

‡1855-56 Tapp, W. Denning, Esq., Senior Surgeon to the Dorset County Hospital, Dorchester.

*1850-51 Tatum, Thomas, Esq., Surgeon to St. George's Hospital, 3, George-street, Hanover-square.

1851-52 Taylor, Robert, Esq., Surgeon to the Central London Ophthalmic Hospital, 10, George-street, Hanover-square.

1860-61 Teevan, William Frederic, Esq., 10, Portman-square.

1852-53 Thompson, Henry, Esq. (Honorary Secretary), Consulting-Surgeon to the St. Marylebone Infirmary, and Assistant-Surgeon to University College Hospital, 16, Wimpole-street, Cavendish-square.

‡1861-62 Thompson, Joseph, Esq., Surgeon to the Nottingham General Hospital, Oxford-street, Nottingham.

1856-57 Tomes, J., Esq., F.R.S., Surgeon-Dentist to the Middlesex Hospital, 37, Cavendish-square.

**Orig. Memb.* Toynbee, Joseph, Esq., F.R.S., Aural Surgeon to St. Mary's Hospital, 18, Savile-row.

1851-52 Trotter, John W., Esq., Assistant-Surgeon, Coldstream Guards.

1859-60 Truman, Edwin Thomas, Esq., Surgeon-Dentist in Ordinary to Her Majesty's Household, 23, Old Burlington-street.

1857-58 Tudor, John, Esq.

*1847-48 Tuke, T. Harrington, M.D., Manor-house, Chiswick.

1852-53 Tulloch, James S., M.D., 1, Pembridge-place, Bayswater.

1857-58 Turtle, Frederick, Esq., Lamberhurst, Surrey.

1856-57 Tyrrell, Walter, Esq., Surgeon to the National Truss Society, 1, St. Helen's-place, Bishopsgate-street.

1854-55 Vasey, Charles, Esq., Surgeon-Dentist to St. George's Hospital, 5, Cavendish-place, Cavendish-square.

1859-60 Venning, Edgcombe, Esq., 24, Belgrave-square.

Orig. Memb. Waite, Charles D., M.D., Senior Physician to the Westminster General Dispensary, 3, Old Burlington-street.

1859-60 Walters, John, M.B. Lond., Assistant-Surgeon attached to Second Battalion, 17th Regiment.

**Orig. Memb.* Walton, Henry Haynes, Esq., Surgeon to the Central London Ophthalmic Hospital, and Surgeon to St. Mary's Hospital, 69, Brook-street, Hanover-square.

‡*Orig. Memb.* Ward, Joseph, Esq., Epsom, Surrey.

*1846-47 Ward, T. Ogier, M.D., Cowbridge, Glamorganshire.

1857-58 Wardell, John Richard, M.D., 4, Belmont, Tunbridge Wells.

1855-56 Watson, Thomas, M.D., F.R.S. (V.P.), Consulting-Physician to King's College Hospital, 16, Henrietta-street, Cavendish-square.

1860-61 Way, John, M.D., 13, St. George's-road, Eccleston-square.

1854-55 Webb, Francis Cornelius, M.D., 22, Woburn-place, Russell-square.

1857-58 Weber, Hermann, M.D., Physician to the German Hospital, 49, Finsbury-square.

1860-61 Wells, John Soelberg, 16, Savile-row.

Digitized by Google

Elected Session

1853-54 Wells, Thomas Spencer, Esq., Surgeon to the Samaritan Free Hospital for Women and Children, 3, Upper Grosvenor-street.

*1850-51 West, Charles, M.D., Physician to the Hospital for Sick Children, 61, Wimpole-street, Cavendish-square.

1858-59 White, Frederick, Esq., 20, Oxford-terrace, Hyde-park.

1856-57 Wilkin, Herbert C., Esq., 39, Connaught-terrace, Hyde-park.

*1854-55 Wilks, Samuel, M.D., Assistant-Physician and Demonstrator of Morbid Anatomy at Guy's Hospital, 11, St. Thomas's-street, Southwark.

**Orig. Memb.* Williams, C. J. B., M.D., F.R.S. (formerly President, late V.P.), Consulting-Physician to the Hospital for Consumption and Diseases of the Chest, Brompton, 49, Upper Brook-street, Grosvenor-square.

‡1858-59 Williams, Charles, Esq., House-Surgeon to the Norfolk and Norwich Hospital, Norwich.

1859-60 Williamson, George, M.D., Fort Pitt, Chatham.

1858-59 Wilson, Edward Thomas, M.B., Montpelier-terrace, Cheltenham.

1859-60 Wilson, Robert James, Esq., 24, Grand Parade, St. Leonards-on-Sea.

‡1861-62 Windsor, Thomas, Surgeon to the Salford Royal Hospital, 65, Piccadilly, Manchester.

*1850-51 Wood, John, Esq., Assistant-Surgeon to King's College Hospital, 4, Montague-street, Russell-square.

1854-55 Wood, William, M.D., Physician to St. Luke's Hospital, 54, Upper Harley-street.

1853-54 Wordsworth, John C., Esq., Assistant-Surgeon to the Royal London Ophthalmic Hospital, 50, Queen Anne-street.

1859-60 Wotton, William Gordon, Esq., King's Langley, Herts.

1852-53 Wright, Edward John, Esq., 13, Montague-place, Clapham-road.

1858-59 Wynter, Hugh B., Esq., 1, St. George's-place, Hyde-park Corner.

Digitized by Google

Digitized by Google

LIST OF SPECIMENS

EXHIBITED AT THE MEETINGS OF THE SOCIETY DURING THE SESSION 1861-2.

DISEASES, ETC., OF THE NERVOUS SYSTEM.

		Page
1. Meningeal apoplexy.	Mr. J. Wood . . .	1
2. Cerebral apoplexy from rupture of an aneurism of the right middle cerebral artery.	Dr. Murchison . . .	2
3. Waxy or amyloid tumour of the brain.	Dr. Murchison . . .	3
4. Cysts of echinococcus scoliciparíens in the brain.	Dr. R. Bennett . . .	5
5. Case of extensive extravasation of blood into the centre of the brain, with a cavity in the left middle lobe containing the remains of an old coagulum.	Mr. J. Gregory Forbes .	7
6. Syphilitic disease of the cranium and dura mater. Meningeal apoplexy.	Dr. Dickinson . . .	8
7. Red softening of the brain from obstruction of the minute arteries by fibrine, which had been carried from one of the valves of the heart during an attack of acute rheumatism.	Dr. Dickinson . . .	10
8. On the condition of the nerve-trunks in anæsthetic leprosy.	Mr. T. Holmes for Dr. H. V. Carter . .	13

Digitized by Google

		Page
9. Fibrous tumours of the dura mater.	Dr. Little, for Dr. Mackenzie . .	16
10. Fibroid tumour in the left hemisphere of the brain, associated with disease of the petrous portion of the temporal bone.	Dr. Goodfellow . .	17
11. Chorea. Softening of the brain and spinal cord.	Dr. Goodfellow . .	19

DISEASES, ETC., OF THE ORGANS OF RESPIRATION.

1. Epithelial cancer of the left side of the interior of the larynx, communicating with an abscess in the neck.	Dr. Gibb for Dr. McOscar . . .	23
Report on the above specimen.	Dr. Gibb	24
2. Vomica of the lung partially lined with bone.	Mr. Browning . . .	25
3. Portion of bone inhaled into the trachea, and expectorated four months afterwards.	Mr. Jonathan Hutchinson	26
4. Enchondroma of the lung.	Dr. Samuel Wilks . .	27
5. Dilatation of the bronchial tubes.	Dr. Samuel Wilks . .	28
6. Cancer of the larynx and œsophagus.	Mr. Christopher Heath .	28

DISEASES, ETC., OF THE ORGANS OF CIRCULATION.

1. Acute pericarditis, associated with great cardiac hypertrophy, the heart weighing forty-six ounces and a-half.	Dr. Gibb for Dr. David . . .	30
2. Extreme hypertrophy of heart.	Dr. Bristowe . . .	32

Digitized by Google

		Page
3. Aneurism of the common iliac artery, showing fissures of the internal coat.	Dr. Wilks	33
4. Case of aneurism of the arch of the aorta, terminating fatally by ulceration of the trachea.	Dr. F. Robinson . . .	35
5. Aneurism and laceration of the ascending portion of the arch of the aorta.	Mr. E. Canton . . .	36
6. Open ductus arteriosus.	Dr. Peacock . . .	38
7. Large aneurism of the descending thoracic aorta, which produced pressure on the left recurrent laryngeal nerve, involved the left lung, and proved fatal by rupturing into the left pleural sac.	Dr. Peacock . . .	39
8. Cardiac disease. Severe symptoms of obstructed circulation, &c., fatal after six months' duration. Very slight and apparently insufficient *post-mortem* evidence of cardiac disease.	Dr. J. R. Bennett . .	41
9. Aorta freely communicating with both ventricles, these with each other; small and thin-walled pulmonary artery, with very small slit-like opening into the ventricle. Open foramen ovale.	Mr. Nunneley . . .	42
10. Aneurism of descending thoracic aorta, with insufficiency of the aortic valves. *Treatment:* Repeated bleeding. *Termination:* Rupture into left pleural cavity.	Dr. W. H. Broadbent .	44
11. Fatty degeneration of the heart, in conjunction with an overloaded stomach, fatal at the age of three years.	Dr. W. H. Dickinson .	46

Digitized by Google

		Page
12. Dissecting aneurism of the aorta.	Dr W. H. Dickinson	48
13. Tubular aneurism of the aorta, innominate and subclavian arteries.	Mr. T. Holmes	50
14. Spontaneous rupture of the heart.	Dr. G. Harley	51
15. Primary softening of the heart.	Dr. G. Harley	52
16. Ecchymosis of the heart, in poisoning by arsenic.	Dr. Samuel Wilks	54
17. Supposed case of aortitis.	Dr. Crisp for Mr. Williams	54
18. Atheromatous aorta, incipient aneurism and extensive cancerous disease.	Dr. Crisp	55
19. Rupture of the brachial artery.	Mr. H. Lee	56
20. Malformation of the heart: contraction of the orifice of the pulmonary artery, and deficiency in the septum ventriculorum. Cyanosis.	Dr. Peacock	57
21. Clot of fibrin removed from the right side of the heart.	Mr. Henry Obré	59
22. Fibroid deposition in the wall of the heart, and in the pulmonary artery, with complete obstruction of one of its divisions.	Dr. W. H. Dickinson	60
Report on the above specimen.	Dr. Bristowe, Dr. S. Wilks	62
23. Malformation of aortic valves.	Mr. Barwell for Mr. Williams	63
24. Aneurism of ham mistaken for abscess.	Mr. E. Erichsen	63

Digitized by Google

		Page
25. Very greatly enlarged heart without valvular disease.	Dr. Peacock . . .	64

DISEASES, ETC., OF THE ORGANS OF DIGESTION.

1. Pharynx, Œsophagus, Stomach, and Intestines.

1. Perforation of sigmoid flexure in a case of typhoid fever, with stercoraceous vomiting.	Dr. Murchison . . .	65
2. Typhoid fever occurring in the seventieth year of age.	Dr. S. Wilks . . .	68
3. Rupture of diaphragm. Displacement of liver and stomach into left pleura. Rupture of stomach and left kidney. Fracture of leg.	Dr. Murchison . . .	70
4. Infiltrated scirrhous stricture of the œsophagus.	Mr. Buxton Shillitoe .	71
5. Disease of the appendix vermiformis, with a small aperture in it, and acute peritonitis.	Mr. Nunneley . . .	72
6. Rupture of the stomach.	Mr. Nunneley . . .	72
7. Stricture of œsophagus, with abscess opening into it and the bronchial tube.	Mr. Nunneley . . .	74
8. Large inflamed fibro-cystic ovarian tumour with incarcerated hernia.	Mr. Nunneley . . .	75
9. Case of medullary cancer of the stomach, associated with dropsy.	Dr. F. Robinson . .	76

Digitized by Google

		Page
10. Two cases of typhoid fever.	Dr. BRISTOWE . . .	78
CASE 1. Typhoid fever. Acute mania. Very slight intestinal disease.	Dr. BRISTOWE . . .	79
CASE 2. Typhoid fever. No Diarrhœa. Death on the sixth day. Early stage of intestinal disease.	Dr. BRISTOWE . . .	81
11. Fibroid disease of the stomach.	Dr. SAMUEL WILKS . .	83
12. Chronic ulcer of the pylorus, with induration of the pancreas.	Dr. BARLOW . . .	85
13. Six inches of the ileum passed per anum, three months before death; also the part of the intestine (perfectly cicatrized) whence this portion came.	Dr. HARE for Dr. HEARNE . . .	86
14. Colloid cancer of the omentum, pancreas, spleen, bladder, cæcum, sigmoid flexure of the colon and rectum.	Dr. O'CONNOR . . .	90
15. Perforation of the stomach from simple ulceration.	Dr. CRISP	93
16. Stomach of a patient who died from the effects of bitter almond oil.	Dr. HARLEY . . .	95
17. Artificial anus after the operation for strangulated femoral hernia.	Dr. PART	95
18. Stricture of the sigmoid flexure of the colon.	Dr. PEACOCK . . .	97
19. Enormous distention of the belly from the effects of a severe and extensive burn.	Dr. GIBB	98

Digitized by Google

		Page
20. Intus-suscepted portion of intestine.	Mr. Maunder	99
21. Cast of femoral hernia.	Mr. Maunder	100

II.—LIVER AND ITS APPENDAGES.

22. Medullary cancer and cirrhosis of the liver. Death from hæmorrhage into the peritoneum.	Dr Murchison	100
23. Two specimens of rupture of the liver, &c.	Dr. Murchison	103
24. Obstruction of the hepatic duct by hydatids. Purpura.	Dr. Dickinson	104
25. Cases of acute atrophy of the liver.	Dr. Samuel Wilks	107
26. Hydatid of the liver bursting into the right pleura.	Dr. Murchison	111
27. Syphilitic deposits in the liver of an infant.	Mr. Canton	113
28. Case of waxy or amyloid disease of the liver and spleen and fatty kidneys, with observations on waxy degeneration.	Dr. Murchison	114
29. Complete obstruction to the bile and pancreatic ducts.	Dr. Harley	118
30. Obliteration of the biliary ducts in an infant.	Dr. Samuel Wilks	119
31. Large abscess of the liver consequent upon dysentery, without the usual symptoms.	Dr. Dickinson	120

Digitized by Google

		Page
32. Specimens of cavernous growth in the liver.	Dr. SAMUEL WILKS . .	122
33. Obstruction of hepatic veins and vena cava by fibrous deposit in liver.	Dr. SAMUEL WILKS . .	122
34. Scirrhus enlargement of the pancreas.	Dr. CRISP	124

DISEASES, ETC., OF THE GENITO-URINARY ORGANS.

SUB-SECTION I.—KIDNEYS, BLADDER, CALCULI, ETC.

1. Stone in the bladder. Lithotomy. Death.	Mr. HENRY THOMPSON for Mr. CADGE . .	126
2. Enormous sac connected with the kidney, recognised as such during life, and repeatedly emptied by tapping.	Mr. HENRY THOMPSON for Mr. JOSEPH THOMPSON	128
3. Adipose transformation of the kidney, following calculus and abscess in that organ, opening through the lumbar muscles.	Dr. J. HULLETT BROWNE	131
4. Horse-shoe kidney, affected with Bright's disease.	Dr. GIBB . . .	132
5. Fragments of a large stone, broken up in the bladder by means of forceps, and removed by lithotomy, from a sacculated bladder.	Mr. H. LEE . .	134
6. Kidney distended into a large cyst, which subsequently became filled with colloid matter, mistaken during life for ovarian disease.	Dr. DICKINSON . .	137
7. Renal calculi.	Dr. GEORGE HARLEY .	139

Digitized by Google

		Page
8. Existence of a calculus in the urethra for a long period, probably fifty years, during which it increased greatly. Accompanying symptoms, and coincident state of bladder-disease. Nature of the calculus. Question as to the mode of formation.	Mr. HAYNES WALTON.	140
9. Atrophy of the right kidney, probably from former distention of the pelvis and calices by urine, with proportionate hypertrophy of the left kidney.	Dr. GOODFELLOW	143
10. Malposition of the left kidney, and sigmoid flexure of the colon.	Mr. CANTON	147
11. Two pounds of fat removed during life from a cyst near the bladder.	Dr. SAMUEL WILKS	148
12. Membranous bag said to have been passed from the female bladder.	Mr. MAUNDER	150
Report on Mr. Maunder's case.	Dr. MURCHISON and Mr. HENRY THOMPSON	150
13. Congenital hydro-nephrosis. Artificial production of acute albuminous nephritis.	Dr. W. J. LITTLE	151
14. Case of enlarged kidney with an irregular shaped calculus firmly impacted and moulded into the calices of the pelvis.	Dr. HILLIER	155
15. Two large calculi and a portion of the prostate removed in the operation of lithotomy.	Mr. H. THOMPSON for Mr. CADGE	155
16. Medullary cancer of the bladder.	Mr. CHRISTOPHER HEATH	157

Digitized by Google

		Page
17. Left kidney extensively sacculated, and containing numerous minute calculi. Obstruction of ureter by three calculi. Right kidney condensed in structure, and studded with minute calculi.	Dr. GOODFELLOW . .	158

SUB-SECTION II.—GENITAL ORGANS, MALE.

18. Cancer of the penis.	Mr. H. THOMPSON for Dr. TROUNCER . .	160
19. Case of stricture of the urethra, in which the strictures were ruptured after death by the employment of the stricture dilator.	Mr. B. HOLT . . .	161
20. Syphilitic testicle, with nodes on the femur and tibia.	Mr. E. CANTON . . .	161
21. The genito-urinary organs and pelvis from a case of Ectopia vesicæ.	Mr. E. CANTON . . .	163
22. Cancerous disease of the testicle.	Mr. DURHAM . . .	166
23. Cystic disease of the testicle.	Mr. DURHAM . . .	167
24. Epithelial cancer of the mucous membrane of the urethra.	Mr. HUTCHINSON . .	167
25. Urinary organs from a patient who was the subject of Syme's operation for stricture, between six and seven years ago.	Mr. HENRY THOMPSON for Mr. GAYE . . .	169

SUB-SECTION III.—GENITAL ORGANS, FEMALE.

26. Unilocular ovarian tumour, successfully removed.	Dr. GIBB for Mr BAKER BROWN . .	169

Digitized by Google

		Page
27. Uterus and its appendages, at the catamenial period.	Dr. Harley	170
28. Cancer of the ovaries and stomach.	Mr. J. B. Curgenven	172
29. Ovarian tumours removed by ovariotomy.	Mr. Spencer Wells	172

VI.—DISEASES, ETC., OF THE OSSEOUS SYSTEM.

1. Fracture of the os hyoides. Faulty osseous union.	Dr. Gibb	173
2. Hypertrophy and eburnation of the femur after amputation.	Mr. T. Carr Jackson	175
3. Case of Colles' fracture of the radius, with fracture of the styloid process of the ulna.	Mr. John Wood	176
4. Colles' fracture of the radius, with fracture of the styloid process of the ulna.	Mr. Christopher Heath	177
5. Syphilitic induration of the bones of the skull, with deposit on parts of their inner surfaces. Cicatrices in the liver.	Mr. Hutchinson	177
6. Case of transverse fracture of the patella, in which the fragments were two inches and a-half apart, but united by true ligamentous tissue.	Mr. Holthouse	178
7. Chronic thickening (node) of the anterior part of the shaft of each tibia, about the centre of the bone.	Mr. Partridge	179
8. Transverse fracture of the sternum, between its junction with the cartilages of the third rib on each side.	Mr. Partridge	179

Digitized by Google

		Page
9. Recent comminuted fracture of the lower end of the right radius.	Mr. Partridge	180
10. Cast of a compound incomplete lateral dislocation of the terminal phalanx of the right thumb inwards.	Mr. Holthouse	180
11. Parts removed in excision of the ankle.	Mr. Barwell	181
12. Separation of the lower epiphysis of the radius.	Mr. Hutchinson	182
13. Separation of the lower epiphysis of the femur.	Mr. Hutchinson	183
14. Rheumatic joint.	Mr. Barwell	184
Report on the above specimen.	Dr. A. B. Garrod and Mr. H. Thompson	185
15. Enchondroma of metacarpal bone and phalanges of little finger.	Mr. Barwell for Mr. C. Williams	185
16. Specimens illustrating the subject of separation of the epiphyses.	Mr. T. Holmes	186
17. Cases of acute necrosis, complicated by pyæmia; with remarks.	Dr. Bristowe	188
Case I. Necrosis of tibia. Pyæmia. Death.	Dr. Bristowe	194
Case II. Acute necrosis of femur. Pyæmia. Death.	Dr. Bristowe	198
Case III. Acute necrosis of radius. Pyæmia. Death.	Dr. Bristowe	201
Case IV. Acute necrosis of femur. Pyæmia. Death.	Dr. Bristowe	203
Case V. Acute necrosis of femur, and of pterygoid process. Pyæmia. Death.	Dr. Bristowe	205

Digitized by Google

		Page
Case VI. Acute Necrosis of tibia. Death from phthisis at the end of five months.	Dr. Bristowe	207
Case VII. Acute necrosis of humerus. Recovery after removal of a sequestrum.	Dr. Bristowe	209
18. Constituents of bone, in a case of mollities ossium.	Dr. Gibb	210

DISEASES, ETC., OF THE ORGANS OF SPECIAL SENSE.

1. Encephaloid tumour of the eyeball.	Mr. Henry Obré	211
2. Bone from the human eye.	Mr. Ernest Hart	212

TUMOURS, CYSTS, ETC.

1. Myeloid disease of the elbow-joint.	Mr. Canton	213
2. Large epithelial cancer of upwards of twelve years' standing, successfully removed.	Mr. Nunneley	214
3. Encephaloid cancer of the lower jaw, most rapidly developed, with acute suppuration and pyelitis, and commencement of disease in the liver.	Mr. Nunneley	215
4. Very rapidly and extensively developed malignant disease.	Mr. Nunneley	217
5. Nipple-like tumour removed from the thigh of a female.	Dr. Gibb for Mr. McWhinnie	218
6. Anæmia lymphatica.	Mr. Barwell for Mr. Williams	219
7. Cystic tumour of the breast.	Mr. Ernest Hart	220

Digitized by Google

		Page
Report on the above specimen.	Dr. John Ogle . . .	222
8. Atrophic scirrhus of breast.	Mr. Hart	223
9. Cancer of the three lower lumbar vertebræ.	Mr. Curgenven . . .	226
10. Enlargement of lymphatic glands with deposits in the viscera.—Anæmia lymphatica.	Dr. S. Wilks . . .	227
11. Cancer of the axillary glands, involving the axillary artery, and resulting in the formation of a false aneurism and fatal hæmorrhage.	Mr. Maunder . . .	229
12. Enlargement of lymphatic glands and spleen. Extreme fatty degeneration of heart and liver.	Dr. Hillier . . .	230
13. Large cystic tumour of the perinæum.	Mr. C. Holthouse . .	233
14. Cancer of lower jaw.	Dr. Quain for Mr. W. D. Wilkes . .	236
15. Anomalous tumours of the leg consisting chiefly of extravasated blood.	Mr. Canton . . .	237

DISEASES OF THE DUCTLESS GLANDS.

I. SPLEEN, ETC.

1. Fibroid degeneration of the capsule of the spleen.	Mr. Canton . . .	241
2. Hypertrophy of the spleen, with thick fibrous deposits on its entire convex surface.	Dr. Gibb	244
3. Atrophy of the spleen.	Dr. Gibb	245

Digitized by Google

II. SUPRA-RENAL CAPSULES.

		Page
4. Morbus Addisonii.	Dr. E. Montgomery	245
5. Disease of supra-renal capsules; tumour in spinal cord; chorea and incipient bronzing of the skin.	Dr. W. H. Broadbent	246
6. Case of morbus Addisonii.	Dr. Little for Dr. Mackenzie	247
7. Alteration of size and structure in the renal capsules.	Dr. Crisp	248

MISCELLANEOUS SPECIMENS.

		Page
1. Specimens of syphilitic disease of the dura mater, liver and diaphragm.	Dr. Murchison	250
2. Casts of diseased teeth.	Mr. Barwell	255
3. Case illustrating contagion between tinea tonsurans in a child and pityriasis versicolor in a young adult.	Mr. Hutchinson	257
4. Artificial jaundice.	Dr. George Harley	257
5. Casts of teeth illustrative of the influence of hereditary syphilis.	Mr. Nunn	258
6. Extensive false membrane in a case of diphtheria.	Dr. Hare	259
7. Syphilitic psoriasis of the nails.	Mr. Hutchinson	259

Digitized by Google

		Page
8. Diseased conditions of the nails consequent on inherited syphilis.	Mr. Hutchinson	260
9. Diphtheria associated with parotitis; recovery.	Dr. Gibb	261
10. Impregnated ovum discharged three or four weeks after conception.	Dr. Schulhof	262
11. Intense bronzing of the skin. Healthy supra-renal capsules.	Dr. George Harley	262
12. Cast of a supposed rupture of the upper and anterior part of the rectus abdominis muscle.	Mr. C. Holthouse	263
13. Arrest of growth of the radius, probably consequent on separation of its epiphysis.	Mr. Hutchinson	264
14. Detachment of the radial and ulnar (?) epiphyses, at the age of eight. Suppuration at the seat of injury: ankylosis of wrist; arrested growth of the bones.	Mr. Hutchinson	265
15. Cases of Alopecia circumscripta, in which contagion occurred, and the presence of a cryptogam was demonstrated.	Mr. Hutchinson	265
16. Case of supposed hereditary syphilitic eruption appearing for the first time at the age of ten years.	Mr. H. Lee	268

Digitized by Google

SPECIMENS FROM THE LOWER ANIMALS.

		Page
1. Tubercle of the spleen, liver, and lungs of an Entellus monkey (Semnopithecus Entellus).	Dr. Crisp . . .	269
2. Chronic rheumatic arthritis of the shoulder-joint of a horse.	Mr. Canton . .	270
3. Enlarged renal bodies in a flamingo.	Dr. Crisp . . .	271
4. Description of a new parasite found in the heart of the edible turtle.	Dr. Leared . .	271
5. Disease in doves, simulating diphtheria.	Dr. Bristowe for Mr. J. L. Jardine .	273

Digitized by Google

Digitized by Google

Digitized by Google

INDEX TO PLATES.

PLATE		PAGE
I.	Condition of Nerve-Trunks in Anæsthetic Leprosy (Dr. H. V. Carter)	16
II.	Fibroid deposition in the Walls of the Heart, and Pulmonary Artery (Dr. Dickinson)	61
III.	Portion of Ileum passed per anum, with the part of the Intestine whence this portion came (Dr. Hare)	88
IV.	Syphilitic deposits in the Liver (Mr. Canton)	114
	Fibroid deposits in the Liver (Dr. Wilks)	114
V.	Sacculated Bladder, from which Fragments of Large Stone had been removed by Lithotomy (Mr. H. Lee)	136
VI.	Congenital Hydro-nephrosis (Dr. Little)	154
VII.	Sacculated Kidney, and Ureter obstructed by Calculi (Dr. Goodfellow)	159
VIII.	Stricture of the Urethra, in which the Strictures were Ruptured after Death by the Employment of the Stricture Dilator (Mr. B. Holt)	161
IX.	Syphilitic Testicle with Nodes (Mr. E. Canton)	162
X.	Pelvis and soft parts from a case of Ectopia Vesicæ (Mr. E. Canton)	163
XI.	Separation of Lower Epiphysis of Radius	182
	Arrest of Growth of Radius, consequent on this accident (Mr. Hutchinson)	
XII.	Myeloid Tumour of Elbow-joint (Mr. E. Canton)	214
	Microscopic Drawings of Fibroid Deposits on Capsule of Spleen (Dr. Bristowe).	
XIII.	Cystic Tumour of the Perinæum (Mr. Holthouse)	233
XIV.	Syphilitic Disease of Nails (Mr. Hutchinson)	260
XV.	Chronic Rheumatic Arthritis of Shoulder-joint in a Horse (Mr. E. Canton)	270

Digitized by Google

INDEX TO WOODCUTS.

FIG.		PAGE
1.	Epithelial Cancer of Left Side of Larynx	24
2.	Portion of Bone inhaled into Trachea, and expelled four months afterwards	26
3.	Muscular Fibres from Left Ventricle, in various stages of fatty degeneration	47
4.	Muscular Fibres from the Heart, in a Case of Primary Softening	53
5.	Portion of the Ascending Aorta affected with Atheromatous Deposit	56
6.	Case of Malformation of the Heart, &c.	58
7.	Microscopic appearances of the Stroma, in Dr. O'Connor's Case of Colloid Cancer of Abdomen	93
8.	Horse-shoe Kidney (in outline)	133
9.	Microscopic appearances of Colloid Matter removed from Kidney	138
10.	Urethral Calculus, external surface and section	142
11.	Atrophied Right Kidney	145
12.	Lobulated appearance of Left Kidney, and its relation to Aorta and Sigmoid Flexure	147
13.	Contents of the Fallopian Tubes at the Catamenial period	171
14.	Fracture and subsequent faulty union of Hyoid Bone	174
15.	Cystic Tumour of the Breast	221
16.	Atrophic condition of Left Breast	224
17.	Cystic Tumour of the Perinæum; Diagram showing the supposed intra- and extra-pelvic relations of the Tumour	235
18.	Anomalous Tumours of the Leg, consisting of extravasated blood; appearance before amputation	239
19.	Ditto, microscopic appearances	240
20.	Fibroid Degeneration of the Capsule of the Spleen; atrophied condition of the Spleen	242
21.	Parasites from the Edible Turtle	272

Digitized by Google

Digitized by Google

REPORT.

SESSION 1861-2.

I.—DISEASES, ETC., OF THE NERVOUS SYSTEM.

1. *Meningeal apoplexy.*

On Sunday, 3rd of November, at half-past three P.M., I was called in to see the patient from whom the preparation was taken, and found him insensible. There were no movements of the limbs on the right side, but the limbs on the left side moved upon sprinkling his face with water. The mouth was not perceptibly drawn to either side. No reflex movements were produced by tickling the foot or leg of the right side. The right pupil was largely dilated; the left, if anything, contracted. There was no movement of the eyelid of the right side, but (from his friends' account) there had been movements of the left; he had partly opened it. He was seen again at nine o'clock and at twelve. No change in symptoms was noticed, except that the insensibility had become more profound. He was seen again at nine A.M. the following morning. There had been no return of consciousness; insensibility was complete; there was stertorous breathing and flapping of the cheeks. He gradually sank and died at half-past two P.M.

Previous history.—He was a man of intemperate habits, and was intoxicated on the night previous to my first seeing him, but not so much so as to disable him from walking: he having followed the girl with whom he cohabited from Battersea to Chelsea. Upon arriving at her home, he threw himself upon the bed, and complained greatly of pain in his head, which he was always accustomed to do when he had been drinking. He made some few observations, chiefly regarding the great pain he was in, was noticed to writhe about for some time, and went to sleep (or became insensible), not showing any sign of consciousness from that time to the time of his death.

Post-mortem examination.—No marks of violence. A large clot was found in the cavity of the arachnoid upon the right side, covering the middle and posterior lobes, and being in greatest quantity over the

Digitized by Google

junction of the middle and posterior lobes; the surface of the brain was compressed in that situation; the clot extended laterally down the side of the hemisphere to the base of the skull in the middle fossa, and as far as the optic nerve, also covering the surface of the tentorium. The membranes were healthy, with the exception of a patch of a bright crimson-colour on the inner surface of the dura mater, opposite the position of the largest portion of clot. There was effusion of lymph in this situation, and an appearance of ulceration. The arachnoid was perfectly healthy in every part, except at the point mentioned. There was no corresponding patch upon the visceral arachnoid, nor any sign of adhesion of the opposed surfaces.

The brain itself afforded no diseased appearances, except that the veins were full of blood. It was carefully sliced without any clot being found, as also were the crura, and pons and medulla. Spinal canal not opened. No blood beneath the tentorium.

Mr. J. Wood, 19*th of November*, 1861.

---

2. *Cerebral apoplexy from rupture of an aneurism of the right middle cerebral artery.*

In this case, there was an aneurismal dilatation, the size of a large pea, or more correctly four lines in length and three in breadth, on the right middle cerebral artery, commencing about three lines beyond where this vessel was given off by the internal carotid. The coats of this aneurism contained a good deal of calcareous matter, and at one place were ruptured to the extent of about one line. Attached to the aneurism externally, at the place of rupture, was a coagulum of dark red blood, situated at the inner part of the right fissure of Sylvius, and continuous with a large clot embedded in the anterior half of the right hemisphere, and amounting to fully two ounces avoird. The surrounding cerebral substance was torn, but not softened. At one place, the coagulum passed into, and filled, the right lateral ventricle; from this it passed down into the third ventricle, and thence, in the form of a narrow cord, through the *iter a tertio ad quartum ventriculum* to the fourth ventricle. It then surrounded the medulla oblongata, and covered the pons Varolii, and the commencement of the crura cerebri; but the coagulum at this place was not continuous with that already described as observed at the base anteriorly. There were four small patches of ecchymosis in the pia mater covering the right hemisphere; the pia mater generally was much injected. Both sides of the heart were filled with dark coagulum; the mitral and aortic

Digitized by Google

valves were healthy; there was very slight atheroma of the aorta, but not of the arteries at the base of the brain. Both lungs were extremely œdematous, the left weighing forty ounces and a-half, and the right forty-five ounces. The abdominal organs were healthy, the kidneys alone being very hyperæmic.

History.—The history of the case was brief, but full of interest. The patient was a man only 24 years of age, stout and well-developed. For some months he had been subject to epileptic fits, characterised by loss of consciousness and convulsions. On the 10th of July, 1861, his friends stated that he had been drinking, and at five P.M. he fell down in a state of unconsciousness, in which state he was brought to the Middlesex Hospital, and admitted under Dr. A. P. Stewart. On admission, he appeared to be in a state of complete coma, with livid countenance, dilated pupils, and pulse 68. About midnight his breathing became stertorous, and his pupils contracted; death occurred at one A.M. of July 11th, eight hours after the commencement of the apoplectic symptoms.

Remarks.—The connection between the aneurism and the epileptic fits is of interest. In a similar case reported to the Society on April 1st, 1856, by Dr. J. W. Ogle, the patient "had been for some time subject to fits." ("Transactions," Vol. VII., p. 128.) The course taken by the hæmorrhage was remarkable. The commencement of the stertorous breathing was probably coincident with the implication of the medulla oblongata. Dr. MURCHISON, *3rd of December*, 1861.

---

3. *Waxy or amyloid (?) tumour of the brain.*

History.—J. D., æt. 19, was admitted into the Middlesex Hospital, on the 28th of August, 1860, under Dr. A. P. Stewart, and died on the 15th of October. He presented all the symptoms and physical signs of advanced tubercular disease of the lungs and larynx, and never at any time suffered from headach, fits, or any indication of cerebral lesion. His illness commenced about twelve months before admission. After admission, he became gradually weaker, and death took place by exhaustion. He was perfectly conscious up to a few minutes before death.

Post-mortem examination.—Both lungs were found infiltrated throughout with tubercular deposit, breaking down into numerous cavities, one of which, at the apex of the left lung, was as large as an orange, and was traversed by bands of pulmonary tissue. The under surface of the epiglottis, the rima glottidis, and the upper inch of the larynx were rough and ulcerated, the ulceration having extended through the entire

Digitized by Google

thickness of the thyroid cartilage at its anterior angle, dividing it into two parts. The heart was healthy.

The liver weighed fifty-one ounces avoird. It was large, pale, flabby, and of soft consistence. The secreting-cells were loaded with oil. The spleen and kidneys were of normal size and structure. The peritoneum, stomach, and intestines were likewise normal.

A tumour, the size of a potato-plum, was found embedded in the upper surface of the right hemisphere of the brain, at the junction of the middle with the posterior third, and about an inch and a-half from the longitudinal fissure. It was attached to the pia mater, and did not project outwards, but dipped into the substance of the brain, to the tissue of which it was slightly adherent. The surrounding brain-substance was not at all softened, and contained no oily matter nor compound granular corpuscles. The tumour itself was very firm, white and translucent, like fœtal cartilage. It contained not a trace of juice, and not a vestige of a cell or nucleus could be obtained by scraping the cut surface. A thin section under a magnifying power of 240 diameters appeared to consist of a wax-like, structureless, hyaline substance, with numerous minute oil-globules, infiltrated through a delicate network of fibrillated tissue. When a portion of the tumour was compressed between two glass plates, it became spread out into a thin layer, and to the naked eye closely resembled a particle of white wax similarly treated. When a drop of a weak solution of iodine was applied to the edge of the glass slide and allowed to run in, the margins of the portion of tumour assumed a reddish-yellow colour, which became converted into a dark-purplish tint on the addition of dilute sulphuric acid. This reaction gradually extended over the mass, on the removal of the thin glass, so as to allow the portion of tumour to come in contact with the reagents. After the tumour had been kept for fourteen months in strong spirit it ceased to exhibit the reaction.

Remarks.—Although from the observations of recent writers, few organs of the body appear to be exempt from the so-called waxy, lardaceous, or amyloid degeneration, I have met with no instance in which the disease occupied the locality above described, or where the morbid tissue presented itself in the form of a distinct tumour.

The tumour, in this case, appeared to have originated in the pia mater.

The circumstance of the patient being the subject of tubercle is of interest, the tubercular diathesis being regarded as one of the chief predisposing causes of waxy degeneration. (See Observations under the

Digitized by Google

head of a case of Waxy Liver in the present volume.) It is to be noted, however, that none of the organs, which are most liable to waxy degeneration (the kidneys, liver, and spleen) were affected in the present instance.

The complete absence during life of all symptoms indicative of cerebral lesion was remarkable. Dr. MURCHISON, *17th of December*, 1861.

---

4. *Cysts of echinococcus scoliciparíens in the brain.*

E. R., æt. 13, a well-grown, healthy-looking girl, who had never menstruated, was admitted into Elizabeth's Ward, in May, 1861. The report which her mother gave was, that for some months she had complained of headach, and that latterly she had been subject to "fits." The head was well formed, and the girl very intelligent. Her appetite was good, and her nutrition well maintained. She was purged, and had a mustard cataplasm. It was soon evident that her sight was impaired; the pupils became widely dilated and fixed. She had occasional epileptic paroxysms, and often complained and cried bitterly from pain of the head, which she referred to the vertex chiefly. She had no vomiting, or impairment of other special sense, except of the sight. The bowels acted readily to medicine, which was not often needed, the tongue being clean, and the appetite good. She took for a long time small doses of iodide and bicarbonate of potash, and had blisters to the temples, &c. After a time she lost power in controlling the movements of her legs, so that she could neither walk nor stand; but when lying in bed she could move the legs freely. Her arms retained their power, and there was no impairment or alteration of sensation anywhere; nor had she ever any squinting, but at one time there was slight temporary paralysis of the left side of the face. When the pain of the head was severe, she obtained some relief from ice and blisters, and occasionally from a dose of henbane. For some time she took the syrupus ferri iodidi, with nourishing diet. Although there was no strumous aspect, or suspicion of strumous disease in other parts, the symptoms were considered as depending on a tumour of the brain, probably of a strumous character; and from the peculiar impairment of the locomotive power it was thought probable that the tumour was in the cerebellum. Having been kept in the Hospital till September 3rd, without any material change in her condition, she was discharged; but after six weeks was readmitted, on the statement of her friends that she was much worse. On her readmission, however, on October 18th, she was found to be in much the same state. Her nutrition had not

Digitized by Google

been quite so well maintained, probably from the insufficient diet of her home, and she had lost the control of her sphincters, so that she passed everything in bed, and occasioned a great deal of trouble to the nurses. Her eyes were more than once examined by the ophthalmoscope, and the retinæ found pale and anæmic. In the intervals of pain she now slept a good deal, and the fits when they occurred were more severe, lasting sometimes fifteen or twenty minutes. Both sides of the body were equally affected. After the fits she also seemed to suffer much pain. Her appetite was good, and she soon regained the *embonpoint* that she had when in the Hospital before. She was again discharged, and died at home on November 19th, after a prolonged paroxysm of convulsions. The *post-mortem* examination was made, under not very favourable circumstances, by Messrs. Gervis and Greaves, my clinical clerks, at the girl's residence.

Post-mortem examination, thirty hours after death.—Rigor mortis not gone off. Body well nourished. Ordinary *post-mortem* ecchymoses in the posterior parts. Lungs, with the exception of a slight sprinkling of small tubercles in both apices, quite healthy. Heart's substance and valves perfectly healthy; a good deal of fat about the right auricle. Liver enlarged, extending as high as the upper border of the fifth rib, and downwards about an inch below the cartilages; substance healthy, but containing seven or eight cysts of various sizes, principally in the right lobe, the largest holding about four or five ounces of colourless fluid. Kidneys congested, but otherwise healthy; as was also the spleen. Stomach and intestines not opened. Head.—Posterior fontanelle open. On removing the calvarium, the middle and posterior lobes of the right cerebral hemisphere were found to be occupied by two cysts, of which the posterior was the larger, and contained about six ounces of clear fluid. The rest of the substance of both hemispheres, the cerebellum and mesocephale and the medulla oblongata were apparently perfectly healthy; rather anæmic than otherwise. Dura mater slightly thickened in some parts. Optic nerves not quite equal in size, the right being a little the smaller. Of the optic tracts, on the contrary, the left was decidedly the less. Pupils equal, dilated, but less so than when she was in the Hospital. The lateral ventricles contained little or no fluid.

The cysts from the brain burst on exposing and attempting to remove the organ, and slipped out spontaneously from their site. One only was brought away. This proved to be the cyst of an echinococcus scoliciparens (Küchenmeister), and was about as large as a good sized lemon. The parietes presented, in a slight degree, their characteristic elasticity,

Digitized by Google

the edges curling over in rolls, and the whole trembling, when handled, like jelly. Close inspection revealed the concentric layers of which the cyst was composed. The internal surface had a fine velvety appearance. By scraping the internal surface of the cyst abundant evidence of its true nature was discovered in the shape of numerous hooklets and debris of microscopic echinococci. Several entire scolices were also obtained, presenting all the characteristic features both of the armed head and the caudal vesicle. But the cyst having been placed in spirit, with a view to further investigation, we searched in vain for other specimens of the animalcule for preservation. Although the cysts found in the liver were not brought away for examination, there could be no doubt, from the description given of them by the gentlemen who made the *post-mortem* examination, that they were also echinococcus cysts.

Dr. J. R. Bennett, *17th of December*, 1861.

---

5. *Case of extensive extravasation of blood into the centre of the brain, with a cavity in the left middle lobe containing the remains of an old coagulum.*

The patient was a small spare woman, and the mother of a large family, æt. 50. She was found in a state of partial insensibility at eight o'clock in the evening of the 15th of February, 1862. She was able with assistance to walk upwards of a mile, and at nine o'clock she tried to answer a question, but was unable to articulate clearly enough to make herself understood. She sank gradually into coma, and died at five o'clock the following morning. She had vomited at the commencement of the seizure. On *post-mortem* examination there was found extensive recent extravasation of blood into the left ventricle of the brain, which had also forced its way into the right ventricle and below the cerebellum.

The preparation was, however, especially interesting as presenting in the left middle lobe of the brain an oblong cavity, upwards of two inches in length, lined with a brown membrane, the result of previous extravasation. Its external wall was formed by the surface of the lobe, softened in texture, and about one-eighth of an inch in thickness.

Though the blood effused, to produce a cavity of this size, must have been considerable, the symptoms to which it seems to have given rise were but slight. The attack, in which Mr. Forbes attended the patient, occurred at the end of October, 1861, and commenced with violent headach and vomiting. The severity of the former symptom was more than usually attaches to ordinary stomach derangement, yet there

Digitized by Google

were at first no other signs of cerebral disorder. In two days, however, a slight loss of power in the left hand, without loss of sensation, was noticed, and on the following day, the mouth was drawn to the right side. The pulse was small and feeble. In a few days she left her bed, and in a fortnight she had quite recovered, and remained well until the attack which proved fatal.

It is said, that a year before this, she had had a somewhat similar seizure.

It is worthy of remark, that her mother, now 80 years of age, has been hemiplegic since the year 1853.

Mr. J. Gregory Forbes, 18*th February*, 1862.

---

6. *Syphilitic disease of the cranium and dura mater. Meningeal apoplexy.*

The subject of the present case was a man, æt. 35, an itinerant lecturer. He had for many years before his death suffered much from syphilis, and, in other respects, had been of very dissolute habits. Some pieces of bone had come away from the nose. For some time, however, before his fatal illness, his health had been tolerably good. In November, 1861, he was attacked with convulsions, chiefly affecting the left side, which were followed by a state of unconsciousness, which lasted for three days. Within the subsequent three months he had three similar convulsive attacks without any loss of consciousness, but accompanied with slight impairment of the mental powers, and much irritability of temper. When he was taken into St. George's Hospital, on the 6th of February, 1862, he was in the fifth convulsive seizure. He was hot, and covered with perspiration. He had violent convulsive twitchings of most of the voluntary muscles of the left side, especially those of the face. The muscles of the right side were similarly affected, but to a much less degree. The pulse was rapid, and rather hard. He was perfectly conscious. Though he could not speak so as to be understood, he wrote upon a card, begging for medicine to stop the convulsion. He had no loss of sensation. A turpentine enema was given, and afterwards some morphia. A blister was placed on the back of the neck. In about two hours he became much quieter, a slight amount of twitching only remaining. He slept well. Next day the movements were scarcely observed, except in the evening. He had no facial paralysis or squinting. The left pupil was slightly larger than the right. The left limbs were rather weaker than the right, and were found to be slightly wanting in sensibility. On the 10th the spasmodic

Digitized by Google

affection increased, as also did a sense of constriction about the throat when he attempted to swallow. He described himself while thus affected as "torn to pieces with cramp." When asleep he was perfectly tranquil. He took a mixture of valerian and ether. The convulsions were seldom quite absent while he was awake, and, at times, especially towards night, were very severe. They were increased when he was watched or spoken to. He became a little deaf. His pulse became feeble and his tongue parched. On the 13th, a swelling was noticed near the left elbow; this was soon afterwards punctured, and a quantity of matter let out. Some diffuse inflammation spread from the wound, and the sore made by the blister began to slough. The movements (Feb. 17) now ceased. He became completely deaf, still retaining complete consciousness. In spite of stimulants, he continued to sink, and quietly expired on the 23rd. After the first attack, three months before his admission, he never had any loss of consciousness.

When the body was examined it was much emaciated. A large abscess in the left arm was discharging through an incision. There were scars on the glans penis, such as would result from chancres.

The skullcap was very solid, and when partially dry appeared more than usually vascular. On the inner surface of the left parietal bone was a small circumscribed deposit of new bone, probably the result of a node of a date long antecedent to the fatal termination. Inside the right parietal bone was a similar deposit of greater extent and more recent origin. Both these localities were surrounded by diffused roughness, probably due to new growth of bone.

Just beneath the node, on the right side, was a circular deposit of lymph, about as large as a shilling, which was, on the outer surface of the dura mater, surrounded by a furrow, around which were some flakes of false membrane easily detached.

When the dura mater was cut open, a large thick mass of incompressible yellow matter was seen on its inner surface, just beneath the patch of lymph on the outside of the membrane. These were, in fact, continuous through the dura mater. The total thickness amounted to half-an-inch. The deposit was yellow and opaque. Under the microscope it had an indistinctly fibrous character. A few fibrillating cells and many fine oil-globules were intermixed.

The convolutions beneath this mass were compressed so as to have a slightly concave surface, which was adherent to the mass of lymph.

Excepting just where this compression had taken place, the arachnoid cavity over the convexity of the right hemisphere was occupied by a semi-transparent brownish membrane. In places this had a rusty

Digitized by Google

or yellowish shade. It had the appearance of a laminar coagulum, which had been effused three or four months before. It was loosely attached to the walls of the arachnoid cavity. It was inseparable from the rounded prominence already described.

There were a few old adhesions between the hemispheres. The ventricles, and all the other parts of the brain, were natural. There was no excess of vascularity.

This case needs little comment. The syphilitic disease of the skull had no doubt been gradually followed by an exudation of lymph beneath, which penetrated the dura mater, and occasioned compression of the subjacent convolutions. The first seizure, which alone was followed by loss of consciousness, was probably due to a sudden effusion of blood into the right arachnoid cavity. The irritation occasioned by the organized membrane which resulted, as well as by the mass of lymph already existing, was no doubt the cause of the convulsions which occasioned the exhaustion and death of the patient. This case illustrates the fact pointed out by Dr. Bright, that convulsive attacks, during which the patient retains his memory or power of observation, are generally produced by some cause of irritation, not in the substance, but upon the surface of the brain. A patient who died after a succession of epileptic fits in the Hospital, some months before, afforded another example of the same law. During the seizures he appeared unconscious, but in the intervals he was able to repeat conversations which he had then overheard. A film of recent lymph, probably of syphilitic origin, was found upon one of the hemispheres. The brain in all other particulars was natural. Dr. DICKINSON, *4th of March*, 1862.

---

7. *Red softening of the brain from obstruction of the minute arteries by fibrine, which had been carried from one of the valves of the heart during an attack of acute rheumatism.*

The subject of the present case was a single woman, æt. 25. She had a pasty and anæmic appearance. Excepting that her breath had been observed as offensive, she retained her usual health until the evening of February 14th, when she had several slight rigors, felt unwell, and went early to bed. During the night she became delirious. In the morning the left knee and one of the fingers were observed to be swollen. As the delirium continued, she was, on the evening of the 15th, sent to the Hospital. When spoken to, she was recalled to sensibility. The delirium was of the low muttering type. The head, and body generally, were hot. She complained of continual pain in

Digitized by Google

the head and in the back. The pulse was very rapid. The heart acted with energy. A systolic murmur was heard at the base, and less distinctly at the apex. There was now no appearance of swelling in any of the joints. An aperient was ordered, a saline draught at intervals, and cold lotion to the head. She passed a restless night, with the same kind of delirium. The evacuations were passed into the bed. Some urine which was secured was found to be highly albuminous. The murmur varied much from time to time. It was now (Feb. 16th) louder at the apex than at the base, and was sometimes scarcely audible, at other times very loud. There was a slight squint affecting the right eye. The tongue was furred and red at the edges. On the night of the 17th her nose bled. On the 18th she was more depressed; she lay quietly in bed, groaning occasionally, as if in pain, and now and then drew a deep sigh. There was a tendency to drowsiness. When roused she answered correctly. The skin was still unnaturally hot; the pulse 130, still with some power. She still took the saline draught, had calomel at intervals, and a blister on the neck. Next day the delirium was of a more active character; she sang and talked during the night, and declared she had no pain. The nose had bled again considerably, and there was a decided squint with both eyes. The pulse was 140; it was more feeble, seeming to fall away under the finger. On the 20th the pulse could scarcely be counted; there were sordes on the teeth, and a film upon the eyes. She took no notice of any one.

The pupils were not affected by light. Afterwards she passed into a state of complete unconsciousness, and quietly expired on the 21st.

When the body was examined, twelve hours after death, some excess of fluid was seen under the arachnoid membrane of the brain, which was turgid with blood in some places. When the hemispheres were sliced, a mass of circumscribed red softening was seen in the right. This was about an inch in lateral measurement, and two inches from before backwards. It had a broad base, which corresponded to the longitudinal fissure. The change extended in the vertical direction from within half-an-inch of the top of the hemisphere to the membrane lining the roof of the lateral ventricle. The softened part was red, as if dotted with innumerable minute ecchymoses. The colour was not bright, but tended to a brownish tint in parts. The separation between the affected and the healthy parts was abrupt. In the neighbourhood of the large mass were one or two others of similar character, but much smaller extent. The convolutions which were nearest to the softening had a trifling quantity of recent lymph upon them.

Under the microscope, the altered parts displayed numerous nerve-

Digitized by Google

tubes much broken up, and mixed with blood-cells; but there was no abnormal deposition in the tissue. The minute arteries forming, and connected with, the pia mater, were obstructed by coarse granular material, which was irregularly packed within their cavities. The corresponding vessels in other parts of the brain were natural.

The large arteries were dissected out. In the vessels connected with the vertebral, as well as with the carotid arteries, alike on both sides of the brain, were many small shreds of fibrine. These were pretty evenly distributed. They were too small to cause much obstruction in the vessels.

The heart was covered with a few patches of old lymph, the result of former pericarditis. The orifice of the mitral valve was fringed with beads of recent lymph. There was also a long loose mass of fibrine, about an inch in length, which was attached to one of the depressions of the valve. It was soft, easily detached, and floated freely in the ventricle. It was opaque, of a dull-whitish colour, inelastic, and had apparently been formed long anterior to death.

There was a fibrinous block, surrounded by vascularity, at either end of the left kidney. There was no obstruction in the larger arteries leading to these parts; but the microscopic arteries were all filled, more or less completely, with coarse granular matter. In the altered portions, beside the vessels thus obstructed, there were seen the ordinary elements of the kidney, and some coarse granular matter, some of which was collected into nodules.

The liver contained, at its anterior edge, a small mass of deposit resembling those in the kidney.

This case appears to have been one of acute rheumatism, with early affection of the heart. The cerebral symptoms no doubt were due to the obstruction of the vessels of part of one hemisphere by the accidental course of particles of fibrine swept into the circulation from the mitral valve. The red softening which resulted has been observed in other cases of a similar nature.

The symptoms referred to the brain were much the same as would have resulted from an inflammatory attack involving the same part of the organ.

In cases like the present, where fibrinous blocks are produced in organs by the stopping up of the vessels by fibrine, the obstruction appears to commence in the capillaries, or minutest arteries. As the current of particles continues to flow the obstruction extends up the larger branches. The characteristic appearance is due to the distention of small arteries by fibrine. The stopping up of a large vessel by a single

Digitized by Google

plug is inadequate to produce one of these blocks in the part from which the supply of blood has been cut off.

Dr. DICKINSON, 18*th of March*, 1862.

---

8. *On the condition of the nerve-trunks in anæsthetic leprosy.*

The interest appertaining to the accompanying observation is derived from the circumstance of its relating to a wide-spread and serious disease, the pathology of which has been comparatively neglected in India.

A similar affection is prevalent in Norway, where it has been carefully studied; but to judge from an epitome of Messrs. Danielssen and Boeck's work, contained in the Brit. and For. Med.-Chir. Rev., for 1850, p. 176, the microscope, except in one instance, has been little used. To the best of my knowledge, a similar change in the great nerve-trunks is not recorded in the more accessible works on Pathology. The physiologist may probably find, in anæsthetic leprosy, one of the most apposite illustrations he could adduce, of the effect upon nutrition of long-suspended nervous influence; in fact, the extremities do suffer greatly, become atrophied, ulcerated and destroyed. As my present object is simply to record a fact, it would be irrelevant to enter on this subject.

CASE.—A Mussulman, æt. 30, native of Dacca, but resident in Bombay, was admitted into the Jamsetjee-Jejeebhoy Hospital, on the 8th of December, 1861, having for seven months being affected with leprosy. He was emaciated and weak. There was no anæsthesia about the head, nor any signs of the disease beyond depression of the nose. The hands and adjoining parts of the forearms were almost completely devoid of sensation; the fingers were swollen, shortened and ulcerated. The foot and leg on both sides were similarly affected; on one the great toe had dropped off, and the anæsthesia was complete. The disease began in the feet; then the hands, and quite recently the face, were implicated. The urine was pale, alkaline, free from albumen, of light specific gravity, and copious in quantity.

The patient died of dysentery and exhaustion on the 7th of January.

Post-mortem examination.—The hairs on the eyebrow were few in number; muscles pale; blood coagulated.

Brain.—The membranes healthy; substance wet and soft, many puncta; on the floor of the fourth ventricle, and in the corpus dentatum of the left crus cerebelli, a very small extravasation of blood. Arteries healthy.

Digitized by Google

nerve, we see the ends of a series of more or less regular canals, with these nucleated fibre-cells forming the walls; in the interior, is the clear albuminous deposit, embedded in which may be seen the remains of the compressed and disintegrated nerve-fibre. Much granular matter and large granular nuclei remain after the addition of acetic acid, and they are particularly abundant just within the main sheath of the funiculus and in the smaller septa sent between its various segments. The accompanying illustrations (Plate I.) will serve to render these changes intelligible.

I forbear to enter into further details, or at present to trace the progress of this new deposit amongst the nerve-tubules; what I have now described is found in the nerve-trunks most enlarged; in others less changed, the deposit is not so abundant, and the nerve-fibres are less affected.

In the dissection of a previous case of anæsthetic leprosy, the nerve-trunks were found to be translucent and slightly diminished in size: further investigation may show that atrophy follows enlargement.

As to the nature of the deposit, it appears to me there is no evidence of its being the result of inflammation; neither increased vascularity, nor opacity, nor adhesions being present, and, under the microscope, no granules or exudation corpuscles. I should prefer to look upon the new material as consequent on a certain constitution of the blood, and the locality of effusion as the effect of altered nutritional tendency in the nerve-fibres; a similar state of things, in short, to what we may suppose to exist in syphilis and struma.

Not the least striking circumstance, which I have recently had other opportunities of observing, is that the cutaneous nerve-trunks or nerve-fibres alone seem to attract the new material. This is a remarkable instance of elective affinity in a tissue. The skin, as an organ of sense, is the only other structure I find the deposit in, and this occurs in tubercular leprosy.

Mr. T. Holmes, for Dr. H. V. Carter, *1st of April*, 1862.*

---

9. *Fibrous tumours of the dura mater.*

J. W., æt. 29, was admitted into the London Hospital on the 28th of March, suffering from great debility, loss of sight, smell, and taste, and subject to epileptic fits. He had been a fighting-man, and had

* The diseased nerves, described in the text, were received from Dr. Carter after the termination of the Session. They will be exhibited in the course of next Session; and a further communication on the subject will be found in the next volume of these "Transactions."

Digitized by Google

Digitized by Google

EXPLANATION OF PLATE I.

Fig. 1. The diseased ulnar nerve, natural size, showing the enlargement found at the elbow. A portion of a healthy ulnar nerve is placed at the side.

Fig. 2. A section of the diseased nerve, showing this enlargement to be due to increase in size of the several *funiculi*, which are also semi-transparent, and of a lighter colour than usual. The neurilemma is but little affected. As seen with a low power.

Fig. 3. A vertical section, highly magnified, of the diseased parts; three nerve-tubules are seen far separated, compressed and partly disintegrated, by the deposit and development of an albuminous (?) material between the nerve-tubules. Normally, these last are in close and parallel apposition, regular and clear, as seen in the side figure drawn from nature. The appearance of the diseased fibre is accurately represented, as seen after the addition of weak acetic acid. This brings into view several nuclei in the new formation, some granular and large, others small and clear.

Fig. 4. A transverse section, highly magnified, of the diseased parts. The dark ends of the altered nerve-tubules are seen embedded in the clear albuminous deposit, and surrounded by a network of fibrous tissue developed within it, clear and nucleated. Each of the clear spaces, as a rule, encloses one nerve-tubule, occasionally more than one. It may happen that the tubule has entirely disappeared by absorption, and the space seems empty. The diameter of some of these is 1-400th to 1-800th of an inch; the diameter of a healthy nerve-tubule is about 1-1500th of an inch. The difference expresses the increase of size the diseased nerves acquire.

Digitized by Google





Fig. 2
N. Trunk Transverse sections.

Vertical Sections - Nerve fibres.

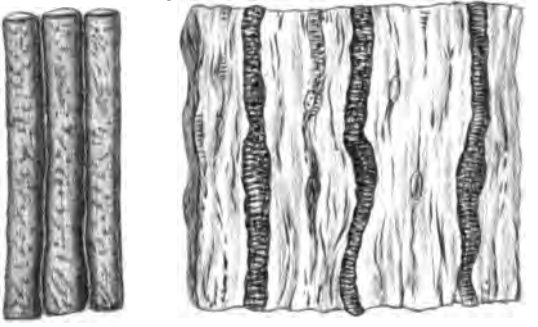

Diseased - Transverse Section - N fibres.

Fig. 4.

F.V. Carter del.
Digitized by Google
W. West, lith

Digitized by Google

received numerous severe blows on the head; he had suffered from syphilis, and had been much addicted to intoxication. The loss of sight was of about nine months' duration. The pupils were widely dilated and motionless. He could not distinguish light from darkness. His sense of smell became impaired four months before his admission and was now quite gone. For the last three weeks he had quite lost his sense of taste. His memory was very feeble. His illness commenced with an epileptic fit, which, however, only lasted a few minutes; after that he had altogether five fits. During the last three weeks of his life, his right side became affected with partial hemiplegia. The patient passed into a comatose condition, and died 2nd of April, 1862.

At the *post-mortem examination*, the dura mater over the cerebral hemispheres was found to be much thickened, and to contain several tumours, varying in size from a pea to a bean. These tumours had encroached on the brain-substance, and produced considerable softening of the grey matter of the convolutions. One large tumour, about the size of a pigeon's-egg, grew from the dura mater, on the under surface of the anterior cerebral lobe, to the left of the median fissure. This tumour had advanced considerably into the substance of the brain, and produced extensive disorganization; but though the left olfactory nerve was pressed upon by the tumour, it was of normal size. The optic nerves appeared healthy, though the commissure was pressed upon by the pituitary body, which was about three times the normal size. Histologically examined, the tumours of the dura mater appeared to be fibrous, with a large proportion of the nuclear element.

Dr. Little, for Dr. Mackenzie, *15th of April*, 1862.

---

10. *Fibroid tumour in the left hemisphere of the brain, associated with disease of the petrous portion of the temporal bone.*

The following case I saw twice in consultation with Dr. Henderson, of Stanhope Terrace, Gloucester Gate, who has been so good as to forward to me his notes of the illness of W. C., æt. 52, piano-forte maker.

For fifteen years he had slight deafness, but it increased during the latter half of that time, and was accompanied by more or less tingling in the left ear. During the last two years he had pain occasionally in the left side and back of the head, which was supposed to be of a rheumatic nature. For some years he has had most violent fits of sneezing, of seven or eight minutes' duration.

Digitized by Google

On the 3rd of June, 1861, while at his work, he was seized with giddiness, and loss of consciousness. He remained insensible for about ten minutes, when Dr. Henderson was called in. He then stated, that he had occasionally been seized with giddiness for some time previously, and that latterly his memory for names had failed, even those he was most familiar with. Under the use of salines and aperients he gradually improved; the pain in the head became less, and the giddiness less frequent, and of much shorter duration. In the course of five days he returned to his work.

On the 29th of September following, he was again compelled to seek Dr. Henderson's assistance. The pain in the head had become much more frequent and severe. Since the attack in June, he had several attacks of giddiness so as to compel him to give up his work, or, if walking, to stop for a few seconds.

October 16th.—The pain has been very severe during the last fortnight, occurring chiefly during the first part of the night, so as to deprive him of sleep until about four o'clock in the morning. He had a slight shivering fit two days previously. The appetite was good, the bowels were regular and sufficiently open, the motions healthy, but the tongue was coated with a brownish fur along the centre.

October 27th.—Has had some attacks of shivering since the 17th. An offensive odour has been smelt by his friends, who supposed it was from the breath.

On the 29th of November, no improvement was observed. The pains were almost constant all night, less severe during the day. The exhaustion from want of rest has been so great as to compel the use of morphia occasionally. It gives him quiet nights, and seems to afford temporary relief. He complains of sounds as from voices in his left ear. One morning he felt slight numbness in the left leg, which passed off in a few minutes. His memory fails him entirely sometimes, and he is at times unconscious of those about him. He has gradually become indifferent with respect to taking food, never asking for it, and when it is brought to him requiring to be fed. His grasp is strong, but he walks with difficulty, requiring support.

December 12th.—Apparently from the effect of small and repeated doses of the bichloride of mercury, he slept well for the last week, the pains in the head had considerably abated, and he walked more firmly and steadier. He now knows those around him, and is able to talk about his affairs, but forgets occurrences which took place a short time before.

On the 19th, the pains returned though not with their former violence, the weakness had considerably increased. He cannot walk

Digitized by Google

without assistance, but when lying down he can move his limbs in any direction with considerable power, and his grasp by each hand is firm. He has become very irritable, which is unusual with him.

During the night of the 20th his mind became clearer and more active, and he talked freely and coherently about his affairs; but at two P.M. the following day, he became worse, soon fell into a state of insensibility, and died at eight without convulsions.

Post-mortem examination.—Brain-substance healthy, save at the middle lobe of the left hemisphere. Vessels injected, some serosity in the ventricles, and some escaped on removing the brain. The middle lobe of the left hemisphere was closely adherent to the posterior two-thirds of the middle fossa of the skull, from which it was necessary to separate it by the scalpel. The substance of the brain at this part was indurated, forming a well-defined mass of a globular form of about two inches and a-quarter in its longest diameter, and one inch and three-quarters in its shortest diameter. It was of a yellowish colour, and seemed to consist of fibroid tissue, exudation corpuscles, a few pus cells and ordinary, but altered, brain-tissue. Around this circumscribed, indurated tumour, the brain-substance, to the extent of from half-an-inch to three-quarters of an inch, was soft and diffluent and puriform. The part of the brain beyond was perfectly healthy. The membranes covering this portion of the brain, and the dura mater covering the superior surface of the petrous portion of the temporal bone, were much thickened. The latter membrane in this situation was separated from the subjacent bone for a considerable extent. The bone itself was red and rough, and a small portion almost black, and infiltrated with blood. It is to be regretted that the removal of this portion of the bone was not permitted. In fact the *post-mortem* examination was made under difficulties. The man was in the coffin, and there was a friend in the room while the examination was in hand. There was no pus seen in the bone, so far as it could be observed by candlelight.

Dr. GOODFELLOW, *20th of May*, 1862.

---

11. *Chorea. Softening of the brain and spinal cord.*

S. W., æt. 16, was admitted into the Middlesex Hospital on the 22nd of April, 1862, under the care of Dr. Henry Thompson. On the 13th of April she received a severe fright while riding on the outside of a cab, and on her return home symptoms of chorea manifested themselves and continued to increase in severity up to the time of her admission into the Hospital. At this time the movements were exces-

Digitized by Google

sively violent, so that she required a nurse to watch her constantly, to prevent her being thrown out of bed by their violence. The movements involved all parts of the body. There was not observed a single voluntary muscle that did not participate in them. The mental faculties were unaffected; but she had great difficulty in articulating her words intelligibly. She was fairly developed; had always been tolerably well off; and was represented to have enjoyed good health up to the date of the present attack, except that she had not menstruated for five months previously. She was severely burnt when a child, since which she is stated to have been "nervous." A brother has been affected with epilepsy from birth. The parents and other members of the family are healthy. She had a good colour; the pupils were normal; the skin moderately warm; the tongue coated; the bowels relaxed. Sulphate of zinc was prescribed for her, on her admission, in grain doses three times daily.

On the 23rd, the movements being as violent as ever, and after a night passed without any sleep, she was ordered to take the following draught every six hours:—Haust. acetatis ammoniæ cum vini antim. pot-tart. et tinct. opii ana ℥x; and to have the whole length of the spine rubbed with the following liniment:—Lin. saponis co. ℥iiss ext. belladonnæ ʒj.

24th.—No rest, and the movements as violent as ever; no delirium. A quarter of a grain of the acetate of morphia to be given hypodermically. Tinct. hyoscyami ʒss. acidi hydrocyanici dil. ℥ij ex mist. camph. 2$^{dis.}$ horis. Cold affusion to the head. Four ounces of port wine.

25th.—She obtained some sleep for short periods only during the night. The muscles were in complete repose during sleep. A pill, composed of compound colocynth and blue pill, of each five grains, was given to move the bowels, which had not acted since her admission. A third of a grain of morphia was injected in the evening, before any sleep was obtained.

26th.—Pil. tiglii co., gr. x, was given last night, and half-a-grain of morphia was administered hypodermically. No relief from the bowels; movements increased in violence; little sleep. Rep. pil. tiglii co., gr. x, statim. Two-thirds of a grain of morphia were injected, and in the evening half-a-grain more.

On the 27th the urine was drawn off by catheter, for the purpose of testing. The sp. gr. was 1030, it was clouded by heat, and cleared by nitric acid. Unfortunately, no analysis for urea and other constituents was made. From the great sp. gr., it is presumed that the proportion of urea was considerable.

Digitized by Google

No action of the bowels occurred until the 30th, when they acted freely; the motions were copious and lumpy. Between this and the last report the movements remained as violent as ever, sometimes alarmingly so.

Quinine, chloric ether, and zinc were tried; with cold affusion, and the warm bath occasionally. This always seemed to soothe her, and the movements were for a few minutes less violent.

May 1.—Chloroform inhalation was cautiously tried this morning. The movements subsided in some measure for about five minutes after the inhalation, but afterwards they became more powerful than before.

May 3.—This afternoon, almost immediately after the hypodermic injection of a grain of the acetate of morphia, the pupils, which had previously been dilated by large doses of hyoscyamus, were observed suddenly to become contracted, and she was violently delirious. In the course of an hour (about half-past four P.M.) she fell into a comatose state; the lips were livid; there was foaming at the mouth, and a discharge of a considerable quantity of tenacious mucus from the nostrils. The pulse was almost imperceptible; the respirations about twelve in a minute, variable; and there was a loud tracheal rattle. By means of slapping the chest with a towel saturated with cold water, and galvanism, but principally, as it seemed, by the former, she recovered from this state. During the use of galvanism alone, the coma became more and more profound, whereas she was immediately roused by the wet towel.

From this time she slept more, and the movements were much less violent; but the skin became preternaturally hot, the breathing hurried, moist rattles were heard over the whole of the chest, and the prostration was extreme.

She died, without convulsions, on the 7th, at half-past five P.M., the movements having continued, though with less violence, up to the period of her death.

Post-mortem examination, twenty hours and a-half after death.—No rigor mortis.

Head.—Vessels of the *pia mater* much distended with blood. No apparent deposit of lymph or tubercle. Bloody points on section of brain-substance rather above the average, but not very numerous. A very small quantity of fluid in the ventricles and in the sub-arachnoid space. Substance of brain almost universally softened. The parts chiefly affected were those surrounding the ventricles, especially the posterior pillars of the fornix and the septum lucidum. The left side of the cerebrum was more softened than the right, and more extensively. The cerebellum was in the same condition as the cerebrum.

Digitized by Google

Thorax.—Substance of the heart pale; cavities somewhat larger than natural. One of the folds of the *tricuspid valve* partially adherent to the wall of the ventricle. Endocardium stained with blood.

The left lung much congested, but no part sinking in water. Some cretified tubercle at the apex. The bronchial tubes deeply injected. The right lung presented no tubercle. The middle and lower lobes studded with numerous patches of apoplexy. The lower lobe much congested, slightly granular, and apparently in the early stage of hepatization. The bronchial tubes as in the opposite lung.

Abdomen.—Intestinal vessels generally distended with blood. Mesenteric glands enlarged. No tubercle. No appearance of ulceration. Kidneys dark-coloured from congestion, otherwise normal. Liver mottled, as in first stage of hepatic congestion. Stomach much injected, its folds enlarged, and the mucous membrane marked with numerous points and patches of extravasated blood.

Spine.—Marked congestion of all the blood-vessels, both those external to the dura mater and those ramifying on the *pia mater*. Cervical swelling softer than natural. Considerable softening of the whole substance of the cord, especially in that portion between the third or fourth and the seventh dorsal vertebra. In this last situation the softening was extreme.

On a careful microscopical examination of the cord, after it had been in spirit, by Dr. Thompson, Dr. Murchison and myself, no compound granular corpuscles could be observed. The nervous substance seemed as if it had been broken down.

On reflecting on the changes observed in the brain-substance, as also that of the spinal cord, and the duration of the disease, it seems probable that the softening observed might have been due to innutrition from want of rest,—from constant unintermitting active function. Nearly a month elapsed without sleep for more than a few minutes at a time, the longest time being two hours, with the exception of that state of coma into which she fell after the injection of the grain of morphia. During the whole of this time, also, with the same exceptions as with regard to sleep, the movements were incessant, and of a most violent character, the contortions being frightful at times.

The disease followed a fright, the health being otherwise good. There was nothing calculated to produce inflammation of the nervous centres, and no products of inflammation were observed, after close examination of the substance of the brain, or of that of the spinal cord.

Dr. GOODFELLOW, *20th of May*, 1862.

Digitized by Google

II.—DISEASES, ETC., OF THE ORGANS OF RESPIRATION.

1. *Epithelial cancer of the left side of the interior of the larynx, communicating with an abscess in the neck.*

W. P., æt. 43, of nervous temperament, occupied for the greater portion of his time as a working-tailor. He had been for years subject to more or less cough. He had no evidence of phthisis, although his chest capacity was much diminished, with considerably prolonged inspiration. Twelve months since from riding outside an omnibus at night, he was seized with partial loss of voice, and some tenderness over the larynx, with increase of cough, for which he was treated generally and locally for a month with considerable mitigation of his symptoms. Four months afterwards he applied for further advice, his cough having now become intolerable and loss of voice complete. There was not much wasting of the body, but his look was haggard and indicative of great anxiety. A little swelling began to make its appearance at the base of the thyroid cartilage to the left of the median line, which at first slowly increased, but latterly became suddenly so large as to endanger life by suffocation. On two occasions he expectorated a large quantity of pus without any apparent diminution of the swelling, which might have led one to suspect vomicæ. The mucous membrane of the pharynx was inflamed and somewhat corrugated. The glottis and rima glottidis were believed to be perfectly healthy. After consultation with Dr. Stewart and Mr. Nunn of the Middlesex Hospital, I opened the swelling, when nearly half-a-pint of thin pus escaped. The neck in a few days became perfectly level. The opening remained, but no air escaped through it, although a communication existed into the larynx lower down. There was no history of cancer in his family. A slight attack of pleuro-pneumonia occurred, and death took place entirely from exhaustion.

The *post-mortem examination* revealed a considerable amount of mischief, involving chiefly the left side of the larynx, and destroying the vocal cords with considerable deposit of what appeared to be epithelial cancer, as shown in the preparation and drawing (Woodcut 1). The thyroid gland was much enlarged, which, from its continuous pressure on the trachea has flattened it antero-posteriorly. A remarkable instance of nature's peculiarity exists in the absence of one of the cornua of the thyroid cartilage.

The case is a very interesting one, as cancer is rare, beginning as in

Digitized by Google

this instance, in the larynx. The case ran the usual period of epithelial

Woodcut 1.

Represents the left side of the larynx, with the large epithelial cancer developed from it.

cancer of other organs before proving fatal. There was no deposit of tubercle in the lungs.

Dr. Gibb for Dr. M^c^Oscar, 21*st of January*, 1862.

Report on the above specimen.—The flattening of the trachea is lateral, towards the right side, and the same cause giving rise to it has produced some deformity of the thyroid cartilage, which is seen in the projection of the anterior part of its right wing at the pomum Adami to the extent of a couple of lines in front of its left wing. The right wing is perfect and apparently not involved in the disease, which would seem to be confined to the inner surface of the left, engaging also the left half of the inner surface of the cricoid cartilage, and a portion of the mucous membrane of the trachea of the same side. A fistulous opening exists at the extreme left side of the crico-thyroid space which must have been in communication with the abscess externally. The left side of the interior of the larynx is filled up with the disease, which com-

Digitized by Google

mences immediately below the cordæ vocales, obliterating the ventricle on that side. The surface is ulcerated, and presents the physical and microscopical characters of epithelial cancer. A remarkable circumstance in association with the larynx is the absence of the superior cornu of the left wing of the thyroid cartilage, and most probably of the left thyro-hyoid ligament. The thyroid gland has the general appearance of colloid disease, in that it is divided into a number of loculi of varying size, filled with gelatinous and oily-looking fluid, which contains an immense number of globules, somewhat resembling those of the blood, but without their distinctive characters.

Dr. GIBB, 21*st of January*, 1862.

---

2. *Vomica of the lung partially lined with bone.*

H., æt. 53, cook in a family, had for several years been subject to severe cough, with expectoration and occasional hæmoptysis. Her impaired health unfitted her for the duties of her situation. On the 13th of December, 1861, about nine A.M., I was hastily summoned to see her. Before I reached the house she had died in the arms of her fellow-servant, who stated, that after a violent fit of coughing, there was a sudden gush of blood from the mouth, which ended fatally in a few minutes. The blood, which amounted to about two pints, was bright and frothy. No satisfactory history of the case could be obtained.

Post-mortem examination.—Nothing unusual in the superficial appearance of the body. Condition tolerably good. On removing the sternum, and exposing the thoracic viscera, the heart, its valves and principal vessels were found healthy. Hydro-pericardium (between two and three ounces); also hydro-thorax on the right side.

The remote and immediate cause of death, however, was evidently in the left lung, a small portion of which only could have performed its function. The pleuræ were firmly adherent; the apex of the lung was so attached to the ribs that it could not be removed. On exploring with the finger, it came into contact with an osseous plate, which formed the anterior and inferior boundary of a vomica the size of a small orange. The bone readily broke away under pressure, and spicula were felt within the cavity. The cavity contained grumous blood, pus, and the *debris* of lung-tissue, and freely communicated with bronchial tubes the size of a quill. The upper part of the pleura was extremely thickened, and connected with an adventitious deposit which lined the upper ribs, and in which could be traced the metamorphic

Digitized by Google

changes from a soft pulpy material to cartilage, from cartilage to bone.

This interesting and very rare specimen has given rise to various opinions as to its true nature. I am inclined to regard it as a case of pleuro-pneumonia, involving the apex of the lung, which was probably the seat of circumscribed tubercle. The chief points worthy of notice are, the partially ossified walls of the lung cavity, and the physiological metamorphosis, to which allusion has been made, in the development of bone. Mr. BROWNING, *4th of February*, 1862.

3. *Portion of bone inhaled into the trachea, and expectorated four months afterwards.*

J. F., a stout asthmatic man, æt. nearly 60, was one day dining on rabbit-pie, when suddenly a violent fit of coughing seized him. When the first paroxysm abated, he still suffered from great difficulty of breathing and sense of irritation in his throat. The dyspnœa continued, and in the course of the afternoon he expectorated blood repeatedly. Next day, the symptoms continuing, he sent for Mr. Steele, of Reigate. Mr. Steele had frequently before attended the man for attacks of bronchitis; and as the patient had himself no suspicion that any foreign body had passed into the trachea, the idea of such an occurrence never suggested itself.

The man remained very ill for several months after the commencement of his attack. He repeatedly expectorated florid blood in considerable quantities, and Mr. Steele noticed a very peculiar bleating rhonchus over the root of the lungs behind. The expectoration was muco-purulent and profuse, and at one time it seemed likely that his strength would give way. At length, about four months after the beginning of the illness, during a violent attack of suffocative cough, the portion of bone shown in the appended figure (Woodcut 2) was brought

WOODCUT 2.

Represents the portion of rabbit's skull which was inhaled into the trachea, and expelled four months afterwards.

up into the mouth. It was evidently a portion of the skull of a rabbit,

Digitized by Google

and presented several sharply-pointed angles. Immediately after its ejection, all symptoms ceased, and the man rapidly regained his usual health.

In this case, had the presence of the intruding bone been suspected, the symptoms were quite sufficient to have warranted—indeed, to have strongly indicated the necessity for—an attempt at operative relief. The man narrowly escaped with his life, so great was the irritation caused. I am indebted to Mr. Steele for the particulars respecting the case. Mr. JONATHAN HUTCHINSON, *4th of March*, 1862.

4. *Enchondroma of the lung.*

J. G., æt. 28, was admitted into Guy's Hospital in a dying state, and no history was obtained of his illness. The body was wasted, and the left side of the chest very dull on percussion. The left lung was much atrophied, and adherent to the chest. On removal, a quantity of purulent matter escaped; this appeared to be partly in the chest, and partly to have escaped from the bronchial tubes, which were broken open. The tissue appeared quite wasted, and the tubes belonging to it dilated. At the root of the lung there was a hard mass of disease, which, on being cut through, was found to be crisp, translucent, and of a pinkish colour. It had all the appearance of enchondroma, both to the naked eye and to the microscope, being composed of loculi which contained cells. The disease involved the bronchial glands and the left bronchus with its branches, having sprung apparently from the tubes themselves, with which it was incorporated. A wide channel passed through the substance of the mass, corresponding to the left bronchus, but the walls of this tube were not involved in the disease. Its branches, or the smaller bronchi, were completely incorporated in the growth, so that the only traces of them found were remains of the rings, which appeared harder and more opaque than the adventitious cartilage. The pulmonary artery was much reduced in size, but still preserved its walls. The pulmonary veins in like manner were much shrunken by the surrounding deposit.

The interest of this case lay in its relation to the subject of the character of new growths, the nature of the disease having been here determined by the presence of the bronchial tubes, from which it sprang. For, just as the more usual forms of disease, cancerous or fibrous growths, appear to take their origin in the bronchial glands, or fibro-cellular covering of the tubes; so here the enchondroma appeared

Digitized by Google

to have sprung up under the influence of the cartilage of the bronchi. This form of disease is not common at this part.

Dr. Samuel Wilks, *15th of April*, 1862.

---

5. *Dilatation of the bronchial tubes.*

This specimen presented an extreme degree of the disease. The patient was fifteen years of age at the time of her death, and was under the care of Dr. Pavy, in Guy's Hospital. The surface of the body was remarkably livid, and especially the face; so much so, that her complaint had been styled *morbus cæruleus*. During the whole of her life she had suffered from bronchitis, dyspnœa, great congestion of the surface and occasional dropsy. At last she died, and the lungs were found to have the tubes dilated towards the periphery into distinct sacs. The upper lobe of the right lung was wholly converted into cavities by dilatation of the bronchial tubes, there being no remains of pulmonary tissue discoverable between them. The section presented the same appearance as would a number of tubes closely packed together, and then cut across, most of these being of the size of the little finger.

Dilatation of the tubes is generally witnessed under two conditions, —the one in connection with chronic pneumonia, and the other with atrophy of the pulmonary tissue. In the first, theories differ between a forcible pulling open of the tubes by the contraction of the inflammatory product, and a giving way of the inflamed tissue under the force of inspiration; in the second case, the morbid process clearly takes its origin in the bronchial tubes. These probably become obstructed, portions of lung-tissue collapse, and the tubes then yield under the force of inspiration, the process being analogous to what is supposed to occur in the inspiratory theory of emphysema,—a part of the lung being collapsed, another expands in an equal degree to take its place. In the case of the adult, this dilatation usually occurs in the air-vesicles of the lung itself; in the child, in the bronchial tubes,—the latter condition being much aggravated during the growth of the chest, whereby the tubes attain even a much greater diameter than they otherwise would.

Dr. Samuel Wilks, *6th of May*, 1862.

---

6. *Cancer of the larynx and œsophagus.*

This specimen was removed from a lady, æt. 60, to whom I was summoned to perform tracheotomy on the 10th of December, 1861. She had

Digitized by Google

been suffering for some weeks from laryngeal symptoms with occasional attacks of dyspnœa, and had had some enlargement of the neck (? thyroid) for some months; and this, together with the recent application of a blister, had rendered the neck much swollen. Upon making an incision I found an immense mass of dense tissue, apparently altered gland (? scirrhus), over the trachea, through which it was most difficult to cut; and it was only after a prolonged operation, and through the kind assistance of Mr. Fergusson, that the trachea was opened at a depth of at least two inches. The dyspnœa was relieved by the operation, and the patient got about and gained a little strength; but on 16th March, 1862, some of the food appeared through the tracheotomy tube, some difficulty of swallowing having been noticed for a few weeks previously. An attempt to introduce an ordinary stomach-tube by the œsophagus failed, but a No. 10 catheter was passed, and she was fed by means of an india-rubber bottle. This continued, with increased difficulty in passing the catheter, up to 17th April, when it was found impossible to pass it; and from the urgent dyspnœa which came on at each attempt, I came to the conclusion that the catheter passed from the œsophagus into the trachea. Injections per rectum were now resorted to, and the patient was kept alive by their means till 13th May, 1862, when she died quietly, having lain in an exhausted condition for two days previously.

The tongue, larynx, œsophagus, and tissues of the neck were removed *en masse*. On laying open the œsophagus from below, it was found to be completely obstructed by the thickened edges of a malignant ulcer of large size, occupying the anterior wall of the œsophagus, which was two inches in its long, and an inch and a-half in its short diameter. In the centre of this was a large ragged orifice leading directly into the trachea opposite the wound made by the operation. Several rings of the trachea were wanting at this point, and in fact, it was one large *cloaca* formed by trachea, œsophagus, and tracheal opening. The larynx presented a growth beneath the mucous membrane of the left side which had completely obstructed the passage and proved to be medullary cancer, this being no doubt the original cause of the dyspnœa. The thyroid and cricoid cartilages were necrosed, the former being broken in half, and a great part of the latter having disappeared. The thickened tissue in front of the trachea had almost entirely disappeared. The thyroid on the right side was only slightly enlarged, but on the left it was undistinguishable from a mass of soft cancer which filled up the anterior triangle, and through which the large vessels and nerves passed, and with which the muscles seemed to

Digitized by Google

be incorporated. The trachea did not appear to have been subjected to any injurious pressure.

All the other organs of the body were healthy, except the liver, which was exceedingly fatty.

There can be no doubt that the primary disease in this case was cancer of the larynx, which offered a mechanical obstruction to the passage of air, and probably give rise to the enlargement of the cervical glands. What the tissue was which caused the extreme difficulty in the operation of tracheotomy must remain undecided, as the appearance at the time of death (five months after) was quite different, but at the time it presented every appearance of scirrhus.

Cases have been recorded in which the irritation of the tracheotomy tube has produced an opening into the œsophagus, but I am inclined to believe, that in this case the disease commenced in the œsophagus and ate through into the trachea, on account of the difficulty of swallowing noticed prior to the formation of the opening, and also on account of the disease found in that viscus. In the "Pathological Transactions," Vol. X., I recorded a case of cancer of the œsophagus opening into the trachea spontaneously.

Mr. CHRISTOPHER HEATH, *20th of May*, 1862.

III.—DISEASES, ETC., OF THE ORGANS OF CIRCULATION.

1. *Acute pericarditis, associated with great cardiac hypertrophy, the heart weighing forty-six ounces and a-half.*

The following are brief particulars of this remarkable case:—M. M., a stout coloured man, of short stature, æt. 42, was admitted, under Dr. David's care, into the St. Patrick's Hospital, Montreal, labouring under a severe and well-marked attack of pleuritis. He stated that he had been ill for about ten days with acute rheumatism, from exposure in travelling, and that he had taken several doses of salts, as well as a couple of ounces of spirits of turpentine, which had been recommended to him as a specific in rheumatism, but that he had become much worse after taking this latter medicine. For the last twenty-four hours he had been unable to rest, cough or take his breath, from the increasing pain in the right side. He was bled copiously twice, and put on calomel and opium, under which treatment he soon got better, when the rheumatic symptoms, which, on admission, had left him, returned with great violence, affecting nearly every large joint in the body. Four

Digitized by Google

ounces of lime-juice were ordered every four hours, and in three or four days he was quite relieved, the pains had ceased, and the swelling of the joints had entirely disappeared. He was now convalescent, and went on still further improving for the next three days, when, having occasion to go to the water-closet during the night, he did so without taking the precaution of putting on any clothes, and on his return to bed he was seized with a shivering fit, which lasted for nearly two hours. Next day he was labouring under a second attack of pleurisy of the right side, for which he was treated as before, with the exception that cupping was substituted for venesection, and he again improved. On examining the chest, however, it was discovered, that as the friction-sound on the right side of the chest diminished, the heart commenced to present a feeble *bruit* with the first sound, which next day increased to the to-and-fro sound of acute pericarditis. There was now acute pain below and to the right of the left nipple, between the fifth and sixth ribs, much increased on respiration or pressure. He was repeatedly cupped, blistered, and given calomel, the treatment being occasionally varied with colchicum, but without avail. He died at the end of the fifth week.

The following appearances were noted after death:—Strong adhesions in the right side of the chest, with effusion of a large quantity of thick turbid serum. The pericardium contained eight ounces of straw-coloured serum; it was enormously distended with a considerable quantity of lymphy deposit upon both of its surfaces, which exactly resembled masses of tripe, of a perfectly white colour. The membrane was not anywhere adherent. The heart was very much enlarged. After removal from the body and being well washed it was found to weigh forty-six ounces and a-half, and measured in circumference fifteen inches and a-quarter, and in length six inches.

The coloured drawing exhibited, accurately represented the appearance which the heart presented after removal from the body, with the pericardium laid open by a crucial incision, and the flaps reflected backwards.

Intense endocarditis was found to be present in both sides of the heart.

Dr. David believes that this is one of the largest hearts on record; but these brief details are brought before the Society, more for the purpose of showing how insidiously so extensive an amount of disease may run its course, as was found in the present instance.

Dr. Gibb for Dr. David, *15th of October*, 1861.

Digitized by Google

2. *Extreme hypertrophy of heart.*

M. W., a young man, æt. 22, was admitted, in a dying state, into St. Thomas's Hospital, on the 6th of April, 1859. He died, in fact, before he could be warded. No history is preserved, and indeed scarcely any was obtained. I recollect, however, that he came from a distant part of the country, with the express object of seeking admission into one of the London Hospitals, and that, although sufficiently out of health to have been induced to take such a step as this, his heart-symptoms had not been severe, nor had he (except, perhaps, by his medical adviser) been thought seriously ill, prior to the occurrence of the paroxysm which carried him off. This paroxysm came on suddenly in the street, and terminated fatally just within the Hospital gates.

Post-mortem examination.—The corpse measured five feet ten inches in length, and weighed nine stone six pounds. It was that of a spare, but not emaciated man, and was neither jaundiced nor anasarcous.

Head.—Brain and its membranes healthy.

Chest.—The pleuræ presented a few old adhesions, and contained a little fluid. The pericardium was in contact very extensively with the front of the chest, and was universally attached by thick toughish cellular adhesions, which were somewhat congested and œdematous. The heart was of enormous size, and weighed, when stripped of adhesions and empty of clot, *forty-six ounces and a-half*. The walls of the left ventricle were seven-eighths of an inch thick at the base. Its cavity was very large, and measured six inches from the commencement of the aorta to the apex. The aortic valves were utterly incompetent, but could have offered very little obstruction to the onward flow of blood. They were contracted in all their dimensions, but chiefly in depth. Their free edges were a little thickened and everted, and their bases presented a good deal of calcareous matter, but there was neither sufficient rigidity nor sufficient deposit to cause any material diminution of the aortic orifice. The mitral valve appeared healthy, but the chordæ tendineæ were remarkably elongated, and the musculi papillares much hypertrophied. The walls of the right ventricle were one-sixth of an inch thick at the thickest part, and the cavity was dilated; but the hypertrophy here was inconsiderable, compared with that of the opposite ventricle. The pulmonic and tricuspid valves were healthy. Neither of the auricles was much larger than natural. The ventricles contained only a trace of coagulum, continuous with cylindrical clots extending along the arteries. The auricles were full of dark-coloured coagulum. The lungs were of moderate size, sparely crepitant, and,

Digitized by Google

in a very great part of their extent, carnified. Bronchial tubes healthy.

Abdomen.—Peritoneum healthy. Liver large and congested. Spleen of moderate size, somewhat pulpy. Stomach and intestines, pancreas and supra-renal capsules healthy. Kidneys congested, otherwise healthy. Aorta healthy.

Remarks.—The case just detailed was brought forward chiefly as an example of very great enlargement of the heart; but there is a point connected with its weight that may be thought to give it some additional interest. When fresh from the body, the heart was carefully examined by myself, and found, as above stated, to weigh exactly forty-six ounces and a-half. About six days subsequently it was examined by Dr. Peacock, who, to my surprise, informed me that he found its weight less by about ten ounces than that which I had assigned to it. Knowing positively (from several circumstances) that I had made no mistake in my original estimate, and being curious to ascertain the cause of our conflicting results, I re-weighed the organ when (about two days subsequently) it returned into my possession; and found, to my dismay, that it was then actually about one ounce and a-half lighter than Dr. Peacock himself had made it. A little consideration reconciled these discrepancies, and showed at the same time the importance, in estimating the relative weights of organs, of instituting the comparison at the time of the *post-mortem* examination, or at least of weighing the organs under the same conditions of time and of other external circumstances. The fact in reference to the above case is, that during the six days that had intervened between my original examination and Dr. Peacock's, the heart, as the weather was cool, had been allowed to lie in a plate, covered at most by a damp cloth, and had thus, by evaporation, gradually lost a large proportion of its moisture, and hence of its weight; and that, between Dr. Peacock's examination and my second one, the organ had been placed in spirit, by which means a further portion of water had been extracted, and the weight had become yet further reduced. Dr. Bristowe, *15th of October*, 1861.

3. *Aneurism of the common iliac artery, showing fissures of the internal coat.*

This specimen was sent to me by Mr. Roper, of Shoreditch, with the following history.

J. C., æt. 57, a publican, and a hard drinker. For many years he

Digitized by Google

suffered from pain in his abdomen, so great at times, that his wife has been called up at night to foment it. He had been wasting away for a year, and for a few weeks his legs had been swollen. For some months his reduced circumstances had prevented him procuring his usual allowance of drink. Six days before his death he had unusually severe pain in the abdomen; and, three days afterwards, when Mr. Roper saw him at his surgery, he was still suffering great pain, and appeared much broken down in health. Eleven hours before his death he was again seen; he was then in his bed, and complaining of violent pain. On examining the abdomen, a tumour could be felt in the right side, extending from the umbilicus to the right iliac fossa, soft, and appearing slightly to expand with the heart's systole, the femoral vessels below pulsating with their usual force. No distinct bruit could be heard. A grain of morphia was prescribed; but in a short time, Mr. Roper was called to him again, and found him in a dying state, with a cold sweating skin, &c. He lived seven hours after this final seizure.

On *post-mortem* examination, the tumour was found to be an aneurism, which had ruptured on its posterior aspect, the blood having become extravasated into the mesentery and sub-peritoneal cellular tissue. The tumour did not appear to have pressed injuriously on any surrounding organs.

The parts removed showed an aneurism of the right common iliac artery extending from the aorta to its bifurcation; and on its posterior and external aspect was a small rupture. At the termination of the aorta, also, was another aneurism of this vessel, with about an inch intervening between it and that of the iliac. Both aneurisms were formed by an equal dilatation of the whole circumference of the vessel. On opening the lower one, the interior was seen to be covered with fissures, which had gradually taken place at various times previous to death. One of these ran along the whole length of the sac, from its bottom through the aorta, as far as the aneurism above;—this fissure had taken place through the internal and middle coat leaving the external stretched over it. It was through the latter that the final and fatal rupture had occurred. This fissure was evidently of some age, as the edges were smooth and rounded. Besides this, there were transverse fissures running around the sac.

The specimen afforded a good illustration of the well-known fact of the middle and internal coats being those which give way in cases of rupture of the blood-vessels, whether in spontaneous laceration of the aorta or in cases of dissecting aneurism, the external coat being in these cases for a considerable time left entire. The ruptures seen in this

Digitized by Google

specimen may in all probability be connected with the attacks of pain, &c., which the patient suffered some weeks before his death.

Dr. WILKS, *15th of October*, 1861.

---

4. *Case of aneurism of the arch of the aorta, terminating fatally by ulceration of the trachea.*

A soldier in the Fusilier Guards, of rather pallid appearance, æt. 39, and who had served twenty years, was admitted into the Regimental Hospital, on the 31st of August, complaining of symptoms so closely simulating those of ordinary chronic bronchitis,—an ailment very common among men of lengthened service,—that he was considered by the medical officer to be labouring under that disease. He expectorated frothy mucus in considerable quantity; complained of dyspnœa, occurring in paroxysms for the most part. No pain of the chest was present. No stethoscopic signs indicative of disease in the arterial system appeared to have been evident then; but large moist râles were audible in both lungs anteriorly. This was also the condition of the chest when I first saw him; but I did not examine the lungs posteriorly. At this date (6th of September) there was no morbid sound in the heart or great vessels anteriorly; no prominence of the sternum, dulness, swelling of the neck, or congestion of the veins. The pulse corresponded in both wrists, and was equally feeble. His appearance was cachectic, the tongue moist, and the indications generally were such as might be expected in a man who had suffered from an exhausting discharge. He was ordered bark, astringents, wine, and liberal diet. Notwithstanding, the symptoms remained unaltered, and the various remedies seemed to have no effect whatever in lessening or altering the character of the sputa, although changed often. His voice was a little hoarse, but certainly not more so than is often met with in chronic affections of the bronchial membrane. He was allowed to be up during the day; and one evening, while taking tea, his mouth filled with arterial blood; a large quantity was instantaneously ejected, and, in trying to walk across the ward to his bed, he fell on his face and expired. An examination was made the following day. The heart was found rather small. Slight atheromatous deposit existed in the aortic valves, but not to an extent to impede their function. The aorta, through its whole course, was much diseased, its coats much thickened, and studded with large patches of the same deposit. The lung-tissue was congested; the bronchi, especially the larger tubes, were dilated; the lining membrane thickened, and covered with thin tenacious secretion. An aneurism, sacculated,

Digitized by Google

irregularly oblong in shape, and filled with coagula at the orifice, was found at the commencement of the arch, opening posteriorly by a slit, large enough to admit a fourpenny-piece, into the trachea. This aperture was the result of a slow ulcerative process. The mouth of the aneurismal sac was surrounded, and regurgitation from it in a great measure prevented, by an elevated abrupt fold of the coats, imparting much the appearance, and probably fulfilling the function, of a valve. This may explain the absence of a bruit (anteriorly, at least), and help to account for the circulatory system,—except as regards the lungs, somewhat compressed and congested by the tumour,—being unaffected. The extent of disease in the coats of the aorta was considerable, the age of the patient considered.

The case is instructive, as corroborating strongly the remarks of writers on the frequent absence of any symptoms pathognomonic of aneurism of the thoracic aorta. Dr. F. ROBINSON, *15th of October*, 1861.

---

5. *Aneurism and laceration of the ascending portion of the arch of the aorta.*

T. D., æt. 72, was brought into the Charing Cross Hospital, having suddenly fallen down in a state of insensibility. The surface of the body and extremities was cold; pulse and respiration scarcely perceptible; pupils contracted. There was no evidence of his having struck his head in falling. Stimulants were administered; he was placed in a warm bed; and hot bottles applied to the feet, axillæ and epigastrium. The temperature of the body rose, the pulse increased in number and volume, and the respiration became improved. He now recognised and spoke to those around him. No pain at any part was complained of. In the space of half-an-hour the favourable symptoms disappeared gradually, and, sinking by degrees, he died within an hour of his admission.

Previous history.—Was a springmaker by trade, and always enjoyed good health until within the last three years. About four years before his death he fell into a saw-pit, and no further injury was complained of than a severe bruising. He has laboured under a cough for the past two years, and the breathing, which had been frequently embarrassed, has latterly become more laborious. Has often complained of pain in the chest. His work occasioned him to stoop much, and it is of a very arduous character, from being obliged to use a heavy hammer. Within the week preceding his death he had not made more than the usual complaint of his ailments; but, for this space of time,

Digitized by Google

having to make greater than his ordinary exertions in business he became worse, and once felt so ill as to be obliged to forego his work, from a feeling of great exhaustion, though, at the same time, suffering no particular pain. By the following morning he had quite recovered, and felt enabled to attend to his duties; but on commencing some easy work he fell down in a state of insensibility, was carried to the Hospital, and there found in the condition already described.

Post-mortem examination.—The pericardium was distended with blood. The heart, large and flabby, was in an advanced state of fatty degeneration. Coronary arteries in the same condition. The ascending aorta much diseased, and at its anterior and right side distended into a large aneurismal pouch, in which was a laceration to the extent of two inches, situated at the forepart of the swelling, and commencing just above one of the sigmoid valves. This rent involved all the tunics of the vessel, but did not implicate the serous membrane covering this part of the artery. The laceration was zigzag in its course, and at the lower part of it was a perforation, not larger than a pin's head, through which the bleeding into the pericardium had taken place.

Remarks.—A case in many respects similar to the above is related by Dr. Geo. Johnson in Vol. I. of the "Transactions" (p. 224). The age of the patient, however, was not more than forty-two years.

It will form an interesting appendix to the above case to quote a few remarks by Hasse and Rokitansky. The former author observes: "Sometimes there are both longitudinal and transverse fissures at right angles with each other. Cracks, traversing in a crooked direction a degenerated portion of the internal membrane of an artery, appear to be the result of the retarded or imperfect development of an aneurism. A rupture of this kind, with separation of the external membrane, may be complicated with an aneurismal sac (Cruveilhier). Occasionally, the continued impulse of the circulation causes eventual laceration of the filamentous sheath, and effusion of blood into the pericardium, and into the cavity of the pleura" (p. 96).

Rokitansky says: "These lacerations, like the diseases in which they originate, generally occur in advanced life. They also usually affect the ascending aorta, which may be explained by the circumstance, that this vessel is, in most cases, especially diseased; while it is, at the same time, exposed to the force of the blood-wave propelled from the heart." (Vol. IV., p. 319). Mr. E. Canton, *5th of November*, 1861.

Digitized by Google

6. *Open ductus arteriosus.*

The preparation was removed from the body of a man, æt. 30, who was admitted into St. Thomas's Hospital, on the 6th of February, 1860, but who died in the bath before he could be placed in bed. No history of his previous condition could be obtained; but, while under observation, he laboured under great difficulty of breathing, and after death he was found to present a marked lateral curvation of the spine.

On examination, old adhesions and some fluid were found in the pleural cavities. The larynx and trachea were healthy. The lungs were congested and sparingly crepitant, and the branches of the pulmonary artery were atheromatous.

The abdominal organs were generally healthy, but the liver was large and firm, and, together with the stomach, intestines and kidneys, congested.

The heart weighed twenty ounces and a-quarter avoir. There was considerable hypertrophy and dilatation of the ventricles, and especially of the right. The pulmonic valves were somewhat thickened, and the artery was rather large, and gave origin to the ductus arteriosus in the usual situation; the duct was pervious, so as to admit of the passage of a large writing quill, and opened into the descending portion of the aortic arch at a point three lines below the origin of the left subclavian artery. The aorta was throughout its upper portion unusually small, and, after giving off the left subclavian artery, diminished still further in capacity, and again expanded beyond the point of entrance of the ductus arteriosus. At its commencement, the aorta had a circumference of thirty french lines; beyond the origin of the left subclavian artery it was only capable of transmitting a ball measuring twenty-four french lines in circumference, and below the entrance of the ductus arteriosus it again expanded to thirty french lines.

There were old adhesions and white patches on the pericardium.

Dr. Peacock remarked that the permanent patency of the ductus arteriosus occurs as a secondary condition in various forms of malformation,—as in some cases of contraction of the pulmonary arteries and very generally when the orifice or trunk of the pulmonary artery is entirely obstructed,—the open duct in these cases forming indeed either the only means by which the blood is transmitted to the lungs for aëration, or a supplementary channel for the same purpose. When the origins of the pulmonary artery and aorta are transposed, the duct also very generally remains open. In cases, however, like that now described, the duct must have been prevented from closing by the existence, at the time of

Digitized by Google

birth, of unusual narrowness of the aorta distal to the left subclavian artery, owing to the imperfect development of that portion of the vessel from the branchial arches. This form of malformation is therefore closely allied to the cases of contraction or obliteration of the aorta which are met with in the same situation in after life, and only differs from them in the period at which the contraction occurs. In those cases in which the ductus arteriosus is found open, the narrowing must have existed to a considerable degree before birth; but where, on the contrary, the duct is closed, the contraction must have been only slight at the time of birth, though it may subsequently have become very marked or have even led to the entire obliteration of the canal of the vessel.

The nature of the latter class of cases is described by Dr. Peacock, in Volume XXV. of the Brit. and Foreign Med.-Chir. Rev. (1860, p. 467). Dr. PEACOCK, *5th of November*, 1861.

---

7. *Large aneurism of the descending thoracic aorta which produced pressure on the left recurrent laryngeal nerve, involved the left lung, and proved fatal by rupturing into the left pleural sac.*

The man who was the subject of this disease, was a scaffold-builder, 35 years of age, engaged in his occupation up to the time of his admission into St. Thomas's Hospital, on the 12th of June, 1861. He had never sustained any serious injury or strain, and no cause could be ascertained to explain his illness.

When admitted, he spoke with a peculiar laryngeal and interrupted voice; had a loud ringing cough and much difficulty of breathing, increased on any exertion. Beneath the left clavicle, there was an obvious prominence, with marked pulsation, dulness on percussion, absence of respiration, and a double murmur, and the left external jugular vein was considerably distended. There was also a loud diastolic murmur heard at the base of the heart and extending down the left side of the lower part of the sternum, and the pulse at the wrist was of the peculiar splashing regurgitant character, and especially when the patient was in the upright position. Some time after his admission into the Hospital, he began to spit blood, and continued occasionally to do so, though never very profusely, throughout the remainder of his life; there was also latterly a considerable difference between the pulses at the two wrists; that of the left arm being fuller and firmer than the right. He died suddenly on the morning of October the 29th. About one o'clock he went to the watercloset, and on returning, staggered and fell on one of the patient's beds. When the nurse went to him, he was faint and nearly

Digitized by Google

insensible, and when seen by the assistant-apothecary after being carried to his own bed, he was entirely unconscious. He rallied, however, and though faint became quite intelligent; when, in the absence of the nurse, he got out of bed and immediately fell back and expired.

The *aneurism* commenced an inch and a-half below the origin of the left subclavian artery, and passed downwards, occupying the right and posterior side of the vessel for about two inches and a-half, so as to form a large oval sac which extended above in front of the transverse arch of the vessel, and posteriorly and on the right side, had led to the erosion of the bodies of the second, third, fourth, and fifth dorsal vertebræ. On the left side, the sac was formed by the upper lobe of the left lung, and it had compressed the bronchus of the lower lobe of the lung, so as to lead to the entire collapse of that lobe. Between the upper and lower lobes it had opened by a small chink in the left pleural sac, and about four pounds of dark coagulated blood were contained in the cavity.

The aneurism had entirely destroyed the left recurrent laryngeal nerve. The ascending aorta was not materially dilated, but its coats were rough and atheromatous. The arteria innominata and its branches were somewhat small, the left carotid and subclavian relatively large. The descending aorta was healthy. One of the aortic valves was contracted, and hung down towards the ventricle, so as to allow of regurgitation. The heart was somewhat large, the right ventricle dilated; the left hypertrophied and dilated. The mucous membrane of the larynx and trachea was injected, but otherwise free from disease.

During life, the aneurism was supposed to arise from the transverse arch of the aorta, the aortic valves were regarded as incompetent, the laryngeal symptoms were referred to pressure on the recurrent nerve, and the hæmoptysis was ascribed to the sac tending to open into some portion of the pulmonary apparatus. It will be seen that the general correctness of the diagnosis was shown on *post-mortem* examination, the origin of the aneurism was not, however, precisely what had been supposed. Instead of its having arisen from the transverse arch, it took its origin from the descending portion, but the upper edge of the sac was considerably above its point of origin, so as to present itself above the transverse arch, and beneath the left clavicle in the seat of prominence and pulsation during life.

Dr. Peacock, *5th of November*, 1861.

Digitized by Google

8. *Cardiac disease. Severe symptoms of obstructed circulation, &c., fatal after six months' duration. Very slight and apparently insufficient post-mortem evidence of cardiac disease.*

J. D., æt. 12, a rather small but well-nourished and healthy lad, was admitted into St. Thomas's Hospital, on the 2nd of October, 1861. His mother stated that between five and six months ago, he had been laid up with the "rheumatics," and was attended by the parish surgeon, but that he had never had scarlatina or any other complaint. He has been ailing ever since the rheumatism.

The following report was taken of his state on admission. His face is swollen and livid, and the lips purple; his breathing is very difficult, and he has a most harassing, frequent, dry cough. The belly is much swollen from ascites, and there is also a good deal of general anasarca, particularly of the scrotum and lower extremities. Tongue tolerably clean; urine scanty, high-coloured, and free from albumen. Pulse quick, regular, and of fair volume. Heart's action excited and visible to the eye, sphere of cardiac dulness increased somewhat, particularly towards the right of the sternum. The pulse somewhat augmented. A well-marked, but not very harsh, systolic bruit exists at the apex and at the base, and in the latter situation there is also a well-marked, rather harsh, diastolic bruit, most distinct in the centre of the sternum, and heard along the course of the aorta. To the right of the sternum this bruit is double, and takes the character of a double friction sound. There is some degree of sensitiveness, not to say tenderness, of the cardiac region. Breathing heavy, frequent, and sometimes gasping. Chest generally resonant on percussion, free from any local depression: posteriorly there is a certain amount, but not much, mucous and sonorous rhonchus. He obtains but little sleep from the frequency of the cough and general distress, which is evidently great; requires the head and shoulders to be elevated. The condition of the liver cannot be ascertained, owing to the amount of fluid in the abdomen; but the alvine secretions are tolerably natural. He was ordered the diuretic pill of squill and mercury, and decoction scoparium with squill and spirits of nitric ether (previously having taken a rhubarb and calomel purge), milk diet and beef-tea. On the following day, the cough being very troublesome, a little tincture of hyoscyamus was added to each dose of the mixture. By these means he was for a time a good deal relieved; but the distressed breathing and lividity of face returned, and he suffered much till his death on the 23rd.

Post-mortem examination, 25th of October.—Anasarca of whole body, lower extremities specially much swollen.

Digitized by Google

Mucous membrane of the larynx and trachea vividly injected. Rather more than a pint of yellow serum was found in each pleural cavity. The apex of right lung was adherent to the surrounding parts, and the base of both lungs was firmly adherent to the diaphragm. The substance of the lungs was much compressed, being at some parts completely carnified. Hæmorrhage had taken place at numerous points into the substance of the lungs, and minute apoplectic clots had formed at these spots; but, towards the costal surface of the lower lobe of the left lung, a portion more than one inch in diameter was found infiltrated with recent coagulated blood. There were also clots in the smaller bronchi leading to this part. The heart was pushed a little to the right side. There were no adhesions to the pericardium, and the inner surface of the latter was perfectly smooth.

The heart was somewhat enlarged, but the enlargement was not very striking. Its muscular structure appeared quite healthy. The walls of the left ventricle were slightly hypertrophied. The mitral valve was perfectly smooth, and no shrinking was detected. The cordæ tendineæ appeared rather short, and seemed to fasten the valve more tightly down than usual. The aortic valves, at first sight, appeared healthy, but a more careful examination showed that the right semilunar valve was somewhat altered. The pouch instead of becoming wider was narrower towards the opening, and the valve itself was slightly thickened. Both the right ventricle and the right auricle were somewhat dilated. The valves of the right side were healthy, but the pulmonary artery was wider, and the walls thicker, than usual.

The abdominal cavity contained a large quantity of yellow serum. The liver was large, and presented very distinctly the characteristics of the nutmeg liver. The spleen appeared healthy, as well as the stomach and intestines. In the left kidney, there was a wedge-shaped discoloured fibrinous clot. These organs were otherwise healthy, as also was the bladder.

Dr. J. R. BENNETT, *5th of November*, 1861.

---

9. *Aorta freely communicating with both ventricles, these with each other. Small and thin-walled pulmonary artery, with very small slit-like opening into the ventricle. Open foramen ovale.*

The young person, from whom this specimen was taken, lived until she was nearly fifteen years old. She had from birth exhibited symptoms of marked cyanosis, at least the symptoms detailed to me when I first saw her could leave no doubt that such was the case. I watched her for up-

Digitized by Google

wards of three years before her death, which took place after a short illness, in which though there was some cough and expectoration, obstinate diarrhœa was the principal ailment.

She was poorly developed both in mind and body, very feeble, very indolent, sat crouching over the fire, was capricious and obstinate in temper, took very little interest in anything, generally but not invariably was indisposed to take exercise, and had an appetite amazingly small. Her colour was always a dull leaden hue, the extremities being cold, moist, and almost purple. The respiratory murmur was very feeble indeed. The action of the heart was rapid and confused, and had a most remarkable sound and impulse, which I do not recollect to have perceived before, nor to have seen noticed by others, but which, independent of the cyanosis, at once led me to diagnose a free communication between the two sides of the heart, though I imagined this rather to be between the two auricles through the foramen ovale, than between the two ventricles, as it proved in a greater degree to be. Instead of the usual direct forward impulse caused by the tilting forward of the apex of the heart during the systole, there was also perceived a distinct lateral distending movement, accompanied by a peculiar burring sound and tremor; both probably caused by the free communication between the two sides of the heart, allowing this lateral pressure when the heart contracted, and the almost single aortic exit, for the minute aperture into the pulmonary artery would allow very little blood to pass. When the ear was laid directly upon the chest, both these abnormal indications were very peculiar, and would, I should imagine, be met with in similar cases.

The walls of the right ventricle are thicker than natural, in proportion to the left. The tricuspid valve is imperfect, one portion is large and thick, one is tied down by short carneæ columnæ, and the third —that before the aortic opening—is very small. The opening into the pulmonary artery is a mere slit, which projects into the vessel, and is not more than sufficient to admit a probe; while there is an aperture into the aorta and left ventricle, sufficiently large to admit the finger. The sides of this orifice are thick, round, and smooth. The walls of the left ventricle are thinner than those of the right. One portion of the mitral valve is much larger than the other. The right auricle is large and thick. The foramen ovale is sufficiently open to allow a quill to pass.

The walls of the aorta are thick, and its valves are natural, while the pulmonary artery is small and thin. The ductus arteriosus is closed.

In the apex of both lungs are some very small tuberculous cavities.

Digitized by Google

The whole tissue of the lungs, however, is so very solid, and the air-cells so very little developed, that several of the different portions tried sink in the water.

The abdominal viscera are very small, but otherwise not unnatural.

It is obvious that such a conformation as here disclosed could have allowed of very little blood passing through the lungs. A nearer approach to the condition of the circulation in the higher of the cold-blooded animals is not often found compatible with the preservation of life in man to the age of fifteen years.

Mr. NUNNELEY, *19th of November*, 1861.

---

10. *Aneurism of descending thoracic aorta, with insufficiency of the aortic valves. Treatment: repeated bleeding. Termination: rupture into left plural cavity.*

The specimen, as exhibited, comprised the dorsal portion of the vertebral column with a large part of the left side of the thorax and its contents, including the aneurism, and showed the relations of the latter with the adjacent viscera.

The aneurism proper commenced just below the origin of the left subclavian artery; but the arch itself, as far the heart, was greatly dilated—this dilatation rendering the valves incompetent to close the opening. It extended down the left side of the vertebral column as far as the sixth dorsal vertebra, occupying the posterior part of the chest, and displacing the lung. Superiorly it projected forwards beneath the clavicle, and had destroyed the anterior part of the first and second ribs and nearly eaten through the third, during life having formed a large pulsating tumour in this situation. An oblique slit, about an inch long, existed on the external aspect of the aneurism, near its lower end, through which blood had been effused into the pleural cavity. The aorta below the seat of the aneurism was extensively diseased.

The lung was displaced forwards by the tumour adherent to its upper part, where it was greatly compressed. It had undergone further compression also from the effused blood.

The heart was large, displaced almost entirely to the right of the sternum. The valves were comparatively healthy in structure, but the semilunar valves of the aortic orifice were incompetent to close that opening on account of the great enlargement of the vessel.

The man from whom this specimen was taken, a coachman, æt. 58, had been under the care of Dr. Sibson in St. Mary's Hospital, at intervals, since the 10th of August, 1860. When first admitted, he complained of

Digitized by Google

pain in the left side, and about the left shoulder-blade, from which he said he had suffered for two or three months. He had a slight cough, and a peculiar broken voice, which was so characteristic, that the diagnosis of aneurism was made before examination. When examined, a heaving motion was found to exist in the left infra-clavicular region, for about one and a-half or two inches below the clavicle, but no tumour. There was absolute dulness over this space; comparative dulness over, and a little to the right of, the sternum. A double-blowing sound was heard along the entire sternum, just audible in the left infra-clavicular region. The heart's impulse was felt an inch and a-half below the nipple, in the fifth intercostal space, and the murmur was less distinct at the apex.

Posteriorly the lung's resonance on the left side extended unusually low down. Dulness began at the lower angle of the left scapula, extended along the left inter-scapular region, and was especially marked over the supra-spinous fossa. Pulsation could be heard, but no murmur.

The pulse was visible, and was equal in force on the two sides of the neck, and in the two wrists.

The pain, never altogether absent, was at times extremely severe, and as he expressed it, "pierced him through." These attacks having become more frequent and lasting, he was bled to twelve ounces, and cupped over the back of the shoulder. The bleeding gave great relief, and he shortly left the Hospital nearly free from pain.

He was readmitted on the 17th of September, with a return of all the symptoms and dyspnœa. There was now a distinct tumour beneath the clavicle, pulsating visibly. He was again bled with the effect of instant relief. The tension and pulsation of the tumour diminished, and the dyspnœa ceased. He had good nourishing diet, but was desired to take fluids in as small a quantity as possible, and he was encouraged to take gentle exercise in the ward and garden. When the pain returned, bleeding was again practised to the extent of six or eight ounces, always giving relief, and checking, for a time, the progress of the tumour. After three or four bleedings he again left the Hospital on the 14th of December.

After being some time under observation as an out-patient, he again entered the Hospital on the 8th of March, 1861, the tumour now projecting beneath the clavicle. The same treatment was pursued with the same result.

He was last taken in on the 17th of September, suffering from great dyspnœa and severe pain. Bleeding again gave great relief, but the dyspnœa soon returned, though in a much slighter degree. On the

Digitized by Google

morning of the 24th, while in the act of sitting up in bed, he suddenly died from the bursting of the aneurismal sac into the left pleural cavity.

Remarks.—The frequent bleeding in this case was not practised with the idea of curing the aneurism according to Valsalva's method, but for the relief of symptoms caused by the extension of the tumour and its pressure on neighbouring parts; and there can be no doubt that the progress of the disease was thus checked, and life considerably prolonged. The regurgitation through the aortic valves, indicated by the diastolic murmur over the sternum, also tended to prevent rapid progress of the aneurism, as there could be no continued tension of the vessel when the blood was permitted to flow back into the heart. This was pointed out as a favourable point in the prognosis by Dr. Sibson at an an early period of the case.

Dr. W. H. Broadbent, *3rd of December*, 1861.

---

11. *Fatty degeneration of the heart, in conjunction with an overloaded stomach, fatal at the age of three years.*

The child was admitted ten days before her death with some ulceration about the labia, and in a very pale and emaciated state. With local measures and good living the ulceration completely healed and the child was apparently convalescent. One night, however, she gradually became pale and collapsed, and complained of pain in the belly; the skin was cold, and the pulse nearly imperceptible. Stimulants were given without avail. After remaining in the same state for three or four hours she expired. There was nothing to give any clue as to the cause of the attack. It was conjectured that the collapse might have been due to some sudden rupture or perforation.

Post-mortem examination.—The body had a natural appearance, excepting that upon the labia were some small round cicatrices.

The brain and its membranes were perfectly natural.

When the pericardium was opened, the heart looked unusually large, owing, as was afterwards found, to the completely uncontracted state of both ventricles, which were distended with yellow coagulum. The auricles were filled with black coagulum. All the valves were perfectly healthy. The foramen ovale was open to a sufficient extent to admit a crowquill. The muscular substance was rather pale, but there was no excess of fat upon the surface. Under the microscope the fibres were seen to be in an universal state of fatty degeneration. No striæ could

Digitized by Google

be found, but their place was occupied by fine black dots, mingled with some obvious oil-globules. (Woodcut 3.)

WOODCUT 3.

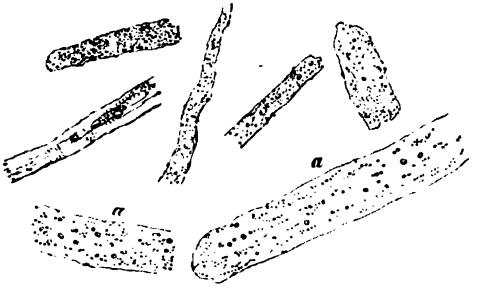

Represents portions of muscular fibres from the left ventricle, in various stages of fatty degeneration. The two lower figures, *a*, *a*, show the appearances produced on the addition of acetic acid.

The stomach was greatly distended, so as to form a very conspicuous object when the belly was laid open. It was inflated with gas, and contained a large quantity of meat and potatoes which were in large lumps, having sharp angles and edges, just as they had been cut by the nurse. They gave no evidence of either mastication or digestion.

Upon the surface of the right kidney was a patch of irregular shape, and about as large as a sixpence. This was congested in the centre, and was surrounded by a white margin. It had the appearance of the very earliest stage of fibrinous block, and this supposition as to its nature was verified by further examination. A portion was prepared so that clear sections could be obtained. Parts of the minute vessels, between the tubes, were distended with fibrinous coagula. The larger arteries were natural.

All the other viscera were natural.

Commentary.—This case affords an example of fatty change in the muscular substance of the heart at an unusually early period of life, though the failure which resulted was probably immediately owing to the oppression occasioned by the distended stomach. In the hours which passed while the action of the heart was gradually failing, the decolorized clots must have accumulated which were found in the ventricles. In similar cases of slow death, it is probable that the fibrine is gathered from the blood by the valvular apparatus of the heart by the same mechanical process as it can be collected out of the body upon a

Digitized by Google

bundle of twigs, or by anything else passing rapidly through the fluid. The incipient fibrinous block in the kidney may be explained by supposing minute portions of the fibrine thus separated to have been carried into the circulation by the blood, and lodged in the minute vessels of the organ. Dr. W. H. DICKINSON, *17th of December*, 1861.

---

12. *Dissecting aneurism of the aorta.*

This preparation was afforded by a policeman, æt. 32. He had usually had good health.

On returning from his turn of duty, which had lasted seven hours, he was suddenly seized with a shooting pain down the centre of the abdomen, which passed through the loins down both legs. He immediately lost all power in the lower extremities, and only saved himself from falling by clinging to some railings which were at hand. He was assisted by some passers-by and sent home in a cab. He reached the Hospital at twenty minutes past six on the evening of December the 11th, about three hours after the first symptoms. He was then perfectly cold from the middle of the belly downwards. The lower extremities were completely paralyzed and the sensation was deadened, though he was conscious of the application of heat, and could feel when the legs were sharply pinched. He was very restless and complained of severe pains in the sacral region. Soon after his admission he passed some pale acid urine which was found to be slightly albuminous. He was cupped from the loins, and small doses of opium were given every six hours. Next day the bowels acted. He observed that the motion was passed quickly and without his control, and said that his power of voiding the urine was imperfect. The pain remained unchanged, but the paralysis had slightly diminished. He was perfectly sensible and collected. He complained of palpitation, and of the annoyance caused him by the sounds of his own heart. Considerable impulse could be felt at the upper part of the sternum, where a double murmur accompanied the sounds of the heart. At the apex the sounds were natural, but dull and distant. The pulse was soft, 80 in the minute. It intermitted frequently, more especially in the right wrist. While undergoing the examination, the results of which are here given, he was induced to sit up in bed. As he was talking quietly he suddenly exclaimed, "I feel giddy," fell forward and expired. He died within twenty-four hours of the first seizure.

Post-mortem examination.—There was nothing unusual in the appearance of the body, which was that of a rather lean, muscular man.

Digitized by Google

The pericardium was distended with black coagulum, which was found to have proceeded from a hole in the ascending aorta through which a large quill might have been passed.

The heart was of rather large size, but was found to be perfectly healthy. About half-an-inch above the aortic valves was a transverse rent which occupied two-thirds of the circumference of the vessel, and formed the entrance to a space between the coats. In the immediate neighbourhood of the rent, the splitting was between the outer and middle coats. Opposite one end the outer coat had given way, and the blood escaped into the pericardium. From this spot the separation could be traced downwards to behind the sigmoid valves, and in the other direction through the arch, and incompletely through the thoracic portion of the vessel. At the point of rupture, as has been stated, the fibrous tissue of the outer coat was exposed to view, but everywhere else the separation had taken place in the substance of the middle coat, a film of which could be peeled off both sides of the cavity. The splitting had extended into the left subclavian, but not into any other of the branches.

Beside the rent described, close to the sigmoid valves, there were other lacerations of the inner surface of the artery. One immediately over it, and parallel, but scarcely deep enough to pass through the inner coat, and not penetrating into the cavity within the wall. Still higher there was an irregular rent, angular in form, which made an opening into the cavity. The origins of the innominata, left carotid and left subclavian arteries were marked by transverse splits which also penetrated into the space. The space was nearly empty. The contact of the walls was only prevented by a few shreds of black coagulum. The lining of the vessel was free from disease excepting one or two minute specks of atheroma near the origin. The abdominal aorta was not examined.

An old tubercular cicatrix existed at the apex of the right lung, but with this exception, all the thoracic and abdominal viscera were healthy.

The spinal cord was examined and found to be healthy.

Commentary.—It is probable that the rupture in the lining of the vessel, which first admitted the blood among the coats, must have been caused by some jerk or strain, though no evidence of this was afforded by the history of the case. The man's occupation must have rendered him liable to occurrences of this sort. It seemed, from the smooth and elastic state of the wall of the vessel, that the rupture could not be at-

Digitized by Google

tributed to any preceding disease. The shallow, recent crack, which had not gone through into the space between the coats, had every appearance of having been produced by mechanical violence, and was apparently of the same date as the other injuries.

The first seizure must have corresponded with the outburst of blood into the arterial wall; the sudden death of the patient was probably occasioned by the escape of blood into the pericardium.

The loss of nervous power in the lower part of the body must be attributed to the sudden closure of the aorta by the pushing inwards of the part of the wall which was internal to the effused blood. It is well known, that when the abdominal aorta is tied, in animals subjected to experiment, complete paraplegia results.

This case is confirmatory of the views expressed by Dr. Peacock, that in dissecting aneurism the cavity is formed in the substance of the middle coat of the vessel; and not, as is sometimes stated, between the middle and outer coats. The blood had completely penetrated the middle coat only at the spot where the rupture into the pericardium took place. Dr. DICKINSON, *17th of December*, 1861.

---

13. *Tubular aneurism of the aorta, innominate and subclavian arteries.*

Mr. Holmes exhibited a tubular aneurism, or aneurismal dilatation, affecting the aorta, innominate and right subclavian arteries.

The patient, a man, æt. 45, was admitted into St. George's Hospital, on the 2nd of February, 1861. He was a plasterer by trade, and in the constant habit of working with the arms raised above his head. Six months before admission he felt a little pain in the right shoulder, accompanied by slight pulsation about the collar-bone. The pain was severe for two days, but subsided under the use of embrocations. He noticed nothing further about the pulsation. In November he became a patient in the Hospital for "gout" in the right hand and arm; and was discharged cured on January 31st. In the evening of that day after he got home, he felt a slight pain beneath the collar-bone, and next morning noticed a swelling just above the clavicle. Finding that this did not decrease he came at once to the Hospital. There was then a large pulsating tumour immediately above the right clavicle, extending from the anterior border of the trapezius muscle, across the subclavian triangle, and passing beneath the edge of the sterno-mastoid. It was of rounded shape, and reached upwards halfway to the jaw. He complained of pain when pressure was made on it. There was said to be an aneurismal bruit in the tumour on his admission, and pulsation of a

Digitized by Google

heaving character was very distinctly perceptible in it. A few days afterwards, however, no aneurismal bruit could be heard. The tumour had diminished in size and seemed harder. The pulse at the right wrist was fuller than that at the left. The sternum was thought to be slightly elevated opposite the second costal cartilage. The superficial veins in the three upper intercostal spaces on the left side were swollen. The heart's action was accompanied by a double murmur.

Under these circumstances, as it was clear that the arteries near to the heart were affected as well as those more superficially situated, it was thought unjustifiable to attempt any treatment. The man was accordingly discharged. He lived for about half a year, and then died with symptoms of dyspnœa. As the death occurred at his own house, the exact particulars are not known.

The affected arteries were taken out and preserved. The dilatation was found to have extended considerably further then when he was in St. George's Hospital, and had now reached into the axilla. The aortic valves were healthy; but the dilatation commenced immediately beyond the valves and involved the whole arch. This part of the artery was not uniformly dilated; the convex part having yielded more than the concave, so as to form a tumour projecting upwards from the highest point of the arch. The dilatation of the aorta ceased at the termination of the arch, but the whole artery was atheromatous. The innominate artery was greatly dilated along its whole extent; and this dilatation extended down the whole subclavian artery and terminated, by a rounded extremity, just beyond the first rib—in the axilla. The axillary artery opened out of the termination of the swelling and seemed healthy. The right carotid artery was also quite healthy. On laying open the sac corresponding to the subclavian artery it was found about half-full of laminated clot, but there was a free passage for the circulation, as there was still a channel through which the finger passed easily into the cavity of the aorta.

Mr. T. Holmes, *17th of December*, 1861.

---

14. *Spontaneous rupture of the heart.*

Dr. Harley exhibited a specimen of spontaneous rupture of the heart, sent to him by Dr. Wm. Newman, of Stamford, with the following history.

"S. S., æt. 65, residing at Leadenham, wife of a labourer. A short, fairly healthy-looking woman. Had not of late years had any serious illness. She came under my care two years since with fractured radius

Digitized by Google

(right). This healed well, and I heard no complaint about general health.

On the 2nd of December she came to my house, complaining of cold and cough. She was seen on the 4th of December; again on the 6th and 8th of December. On the last visit she expressed herself as better in health, but having much cough at night.

On December the 9th she was better all the morning. At 1 P.M. was eating some dinner, and fell back in her chair dead. Her son, who was in the room, said that she died at once, without sound or movement being made.

Post-mortem examination made on the 10th.—Chest alone examined. Lungs normal, a little congested at bases, but no actual consolidation of tissue, frothy mucus in larger bronchi. No pleuritic adhesions on right side. No cavity or trace of tubercular disease. Pericardium contained three ounces or more of clot, heart obscured and pushed backward by mass of coagulum."

The heart is of the normal size, but pale in colour, and rather soft. In the anterior wall of the left ventricle is a rent about an inch in length, parallel to, and half-an-inch from, the septum. The rent has irregular margins, and is about equidistant from base and apex. On the interior of the ventricle it is not visible in consequence of the carneæ columnæ overlying it. On filling the ventricle with water, however, it soon flows out through the rent.

On microscopic examination the fibres were found to be fatty. The fat being distributed in irregular groups of granules.

Dr. Harley called attention to the fact of the left ventricle being so much more frequently ruptured spontaneously than the right, and said that in the thirty-six cases of rupture of the ventricles collected by Berthrand, no less than thirty occurred on the left side. On the other hand, Dr. Harley believed that rupture of the auricles of the heart was more common on the right side than on the left.

Dr. G. HARLEY, *17th of December*, 1861.

---

15. *Primary softening of the heart.*

The specimen was removed from a gentleman, æt. 48, who had been under my care for nearly three months, and whose case presented some unusual features. The gentleman, an inhabitant of one of our large provincial towns, had for many months suffered severely from the effects of chronic pleurisy of the left side, and as no remedies seemed of any benefit he was sent up to London to receive further advice. When first seen by

Digitized by Google

me he was unable to swallow any solid food, could only sleep on one side, and could not take any exercise in consequence of the slightest exertion bringing on extreme difficulty of breathing. The right side of the chest was healthy. The left completely dull throughout. Not a trace of vesicular murmur: only slight tubular breathing in upper portion. He was harassed with a constant hacking cough, but had no spit.

At the *post-mortem* examination, made fourteen hours after death, the left lung was found condensed to a quarter of its original size, and squeezed against the back wall of the chest. The pleural cavity was filled with fluid.

Heart.—The heart seemed of about the normal size, perhaps a little larger than natural, and had a good covering of fat outside. On section, it was not pale like a fatty heart, but of the colour and even of the consistence of a piece of liver that has been kept a few days. In consequence of its unusual appearance, I examined it microscopically, and I found that the fibres separated and broke into fragments, with unusual facility. Notwithstanding this, each individual fragment shewed the striæ well marked. (Woodcut 4). Other fragments were distinctly granular, but contained no fat globules.

WOODCUT 4.

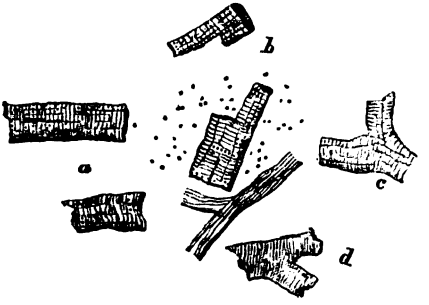

Represents portions of muscular fibres from the heart. *a*, *b*. Broken fragments, with striæ, tolerably distinct, some granular. *c*, *d*. branched fibres.

In turning to the literature of the subject, I can only find one other case of the kind here described. It is reported by Wagner in the "Archiv. d. Heilk.," p. 185, 1860, and occurred in a child sixteen days old, whose mother died of puerperal fever.

Dr. GEORGE HARLEY, *17th of December*, 1861.

Digitized by Google

16. *Ecchymosis of the heart, in poisoning by arsenic.*

Amongst the morbid appearances found in those who have been poisoned by arsenic, authors have alluded to ecchymosis of the endocardium. This, no doubt, is due to a poisoned condition of the blood, which, as is well known, from whatever cause arising, is apt to shew itself in a purpuric state of various parts of the body. In the case of poisoning by arsenic, the heart has been especially noticed to be thus affected; and the subject, therefore, would not have been brought before the Pathological Society, had not the fact been seemingly ignored by some.* My own observations, however, entirely corroborate the statement, and in two cases lately occurring in Guy's Hospital, a large surface of the endocardium of the left ventricle was thus affected. On the septum of the heart exhibited, beneath the aortic valves, there was a large purple patch, also another similar one beneath the mitral valve, and the muscular columns of this valve were also covered with spots of ecchymosis. In one case the man lived three hours after taking the poison, and in the other, twelve hours. The left ventricle, it may be stated, is not the part exclusively affected; the right ventricle may be similarly ecchymosed as well as the auricles.

Dr. SAMUEL WILKS, *7th of January*, 1862.

---

17. *Supposed case of aortitis.*

J. E., æt. 39, became an out-patient at the Norfolk and Norwich Hospital in October, 1860. He had the appearance of being in good health, was rather thin and short in stature. He complained of constant pain in the region of the heart, which was so intensely severe at times, as to render him almost maniacal, and to cause him to run about the house begging his wife to open his chest with a knife, and take his heart out. He had neither suffered from rheumatism nor any other illness but that for which he sought advice. The pain in the cardiac region commenced nine or ten months, but the paroxysms only a few weeks, before he presented himself at the Hospital. He was a parish schoolmaster, but had been subjected to so much mental irritation in consequence of unnecessary interference in his duties by the

* "It is asserted, that on the inner surface of the heart (especially the carneæ columnæ and valves, particularly of the left side) is observed redness, sometimes diffused, sometimes in the form of spots, which penetrate a line in depth into the substance of the heart. White spots are, however, frequently met with on the surface of the heart, when no arsenic has been taken."—Pereira's "Elements of Materia Medica."

Digitized by Google

clergyman and ladies residing in the parish, that he had lately relinquished the occupation.

About three weeks from the date of admission, he died suddenly, and on making a *post-mortem* examination, his body was found to be tolerably well nourished. No œdema in the limbs. The lungs perfectly healthy. Normal amount of fluid in the pericardium. The heart large, and its substance gorged with blood; the coronary veins considerably distended. All the cavities contained semi-coagulated blood, of a dark colour. The right ventricle was dilated, and its walls hypertrophied, the valves perfectly healthy. The left ventricle was likewise dilated and considerably hypertrophied. Mitral valve healthy. Aortic valves small, shrunk, and opaque; the orifice of the aorta so contracted as not to permit the passage of one's little finger; aorta itself contracted, and its internal surface uneven, reminding one of the surface of a "cirrhosed liver;" a good deal of atheroma but no calcification to be seen; the orifices of the coronary arteries extremely small. To the external surface of the aorta was attached much adipose and cellular tissue; a good deal has been removed. The coronary arteries were not calcified. Under the microscope the muscular substance of both ventricles was seen to be in an extreme degree of fatty degeneration. No other organs were examined, inasmuch, as permission was only given to open the chest.

I forgot to mention in their proper places, that there was no fat on the surface of the heart, and, that the pulmonary artery was healthy.

As he was an out-patient his disease was not so thoroughly investigated as it ought to have been.

Remarks—In answer to some questions put to Dr. Williams respecting this patient, he informs me that the aorta was not red, but that the colour was that of liver sodden in water for several days. There had been uneasiness about the breast for nine or ten months, but the intense pain existed for a few weeks only. There is no disease of which probably we know so little as of aortitis, but after a careful examination of the aorta in combination with the symptoms during life, I am inclined to think, with Dr. Williams, that the aorta was inflamed.

Dr. CRISP for Dr. WILLIAMS, 21*st of January*, 1862.

---

18. *Atheromatous aorta, incipient aneurism and extensive cancerous disease.*

This specimen, which consisted of the heart and aorta of a man, æt. 58, who died of cancer of the pubes, prostate, vesiculæ seminales,

Digitized by Google

liver, lungs, and kidneys, was sent to Dr. Crisp by Dr. Williams of the Norwich Hospital.

The ascending aorta was much thickened and dilated, and contained a large amount of soft atheromatous deposit (Woodcut 5), but in this de-

Woodcut 5.

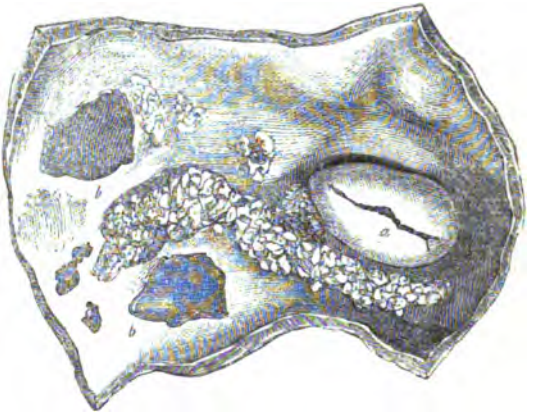

Represents a portion of the ascending aorta, affected with atheromatous deposit. *a*, An incipient aneurism; the inner coats of the artery destroyed by atheromatous deposit; the cellular, and part of the elastic coat, bulging out, through weakness of the arterial walls. *b b*. Similar lesions of the inner coats.

posit were no cancer cells. About two inches above the valves was a small pouch of the arterial walls containing a portion of fibrine (*a*) the size of a large nut; it was closely adherent to the arterial coats, which were thin and defective at this part. Two similar lessions, which would readily occasion aneurism are seen at *b b*. I believe, as I stated many years since, that there is no example to be found of true aneurism (so-called), that is, where all the coats of the artery are entire. The above case I think is a good instance of one of the forms of the commencement of aneurism. Dr. Crisp, 21*st of January*, 1862.

---

19. *Rupture of the brachial artery.*

Mr. Henry Lee showed a portion of a brachial artery which had been taken from a limb amputated a month after a very severe and complicated injury from machinery. The accident happened on the 28th of November, 1861, and on the 18th of December profuse hæmorrhage occurred from a wound in the lower part of the upper arm.

Digitized by Google

On the 22nd, the patient had some rigors, and an abscess opened on the outside of the elbow.

On the 26th, the hæmorrhage recurred, and the arm was then amputated. The humerus was found to have been fractured near its lower part, and corresponding to a projecting part of the upper portion of the bone, was a wound in that portion of the brachial artery which was now exhibited. Mr. H. Lee, *4th of February*, 1862.

---

20. *Malformation of the heart. Contraction of the orifice of the pulmonary artery, and deficiency in the septum ventriculorum. Cyanosis.*

The boy, who was the subject of this malformation, first came under Dr. Peacock's notice in 1857 when he was four years old. His mother then stated that when born his lips were observed to be very blue and he breathed rapidly. When six months old, his heart was noticed to beat unduly, and when he began to play about, he became subject, on any active exertion or excitement, to violent attacks of dyspnœa and palpitation in which he became livid in the face, and which occasionally terminated in convulsions, though when he became quiet they usually subsided. When seen by Dr. Peacock, the veins of his head and chest were large, his fingers and toes clubbed, and the lips and extremities livid. A loud systolic murmur was audible about the left nipple, but not at the top of the sternum or at the posterior part of the left side of the chest.

He was frequently seen during the years 1857, 1858, and 1859, and upon the whole rather improved in health, being less livid and freer from the cardiac and convulsive symptoms. In the last year his friends went to reside in the country, and he was not under observation till February of the present year. He was then found to be suffering more severely, apparently from having recently taken cold. He had a severe cough and much difficulty of breathing, and was markedly cyanotic; the conjunctivæ being injected, the cheeks flushed, the lips and extremities livid, the fingers and toes clubbed, and the nails incurvated. A loud systolic murmur was heard over a large portion of the front of the chest, but was apparently the most distinct in the course of the pulmonary artery. He died convulsed shortly after being seen. He was then nine years old.

The *body was examined* the day after his death. The forehead was prominent, but the head not unduly large. The lower portion of the sternum was protruded and the ribs depressed and flattened; the extremities were very livid.

Digitized by Google

The lungs were dense and congested, but free from disease. The heart weighed four ounces avoir. The orifice of the pulmonary artery was contracted from the adhesion of the valves, which were only two in number, so that it would only give passage to a cylinder, fifteen french lines in circumference. The deficiency in the number of the valves was

Woodcut 6.

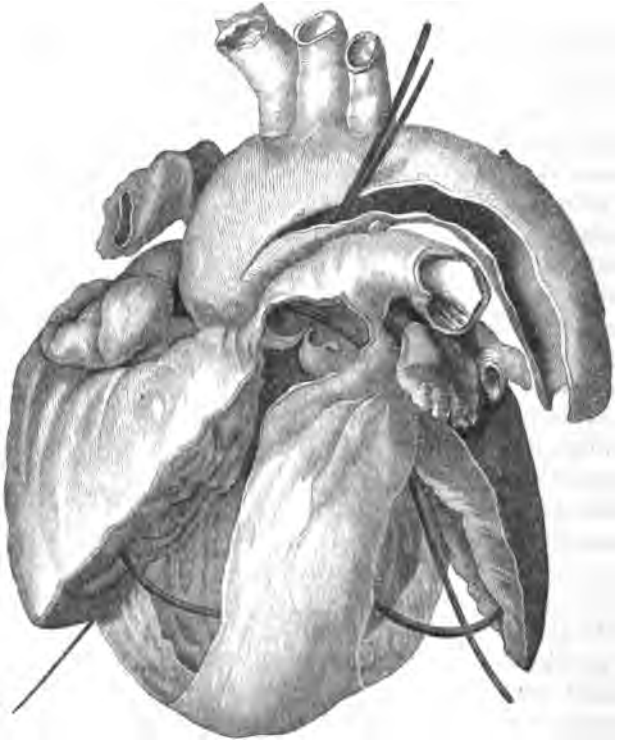

Represents the appearance of the heart. The different points of interest are sufficiently described in the text. The septum ventriculorum could not be shown in the figure; but that it is patulous will appear by the course of the bristles passed through the aortic orifice, one of which protrudes through the section in the right, the other through that in the left ventricle.

evidently due to the adhesion and blending of two of the segments. The right ventricle was of large size (Woodcut 6) and its walls thick

Digitized by Google

and firm. The trunk of the pulmonary artery was small, and its coats thin.

The septum of the ventricles was defective at its upper part, so that the aorta communicated with equal freedom with the two ventricles. The left ventricular cavity was small and its walls thin and flaccid relatively to those of the right. The ascending aorta was of unusually large size. The foramen ovale and the ductus arteriosus were both completely closed.

The liver, spleen and kidneys were large but healthy.

The form of malformation of which this specimen affords an example, is that which is of the most common occurrence, and a considerable number of instances of the kind are recorded by authors (see pp. 49, 50, and 51, of Dr. Peacock's work on "Malformations"). But this case differs from most others, in having had both the foramen ovale and the ductus arteriosus completely closed. The contraction of the pulmonic orifice was, however, much less than in some other recorded cases. Dr. Peacock has himself described specimens in which the orifice was only capable of giving passage to balls or cylinders, thirteen, twelve, and eight french lines in circumference, in much older persons; and similar cases are described by various writers.

During the year 1859, Dr. Peacock repeatedly observed the temperature under the tongue, in the axilla, and in the palm of the hand, of this patient, with the view of ascertaining whether the power of generating heat was less than usual, and he found that there was no material difference between his temperature and that of a healthy, but somewhat younger, child examined at the same time. Dr. Peacock, *18th of February*, 1862.

---

21. *Clot of fibrin removed from the right side of the heart.*

The patient, from whom this clot was removed, was a little girl, æt. 4 years. She had suffered for two days from rheumatic pains in the ankles which were not considered sufficiently severe to require medical advice. The parents described the child to have no other apparent disease. On the third day of her indisposition she was unusually languid, and shortly after an attack of vomiting, suddenly fainted, and died before medical aid could be procured.

The body was examined fifteen hours after death, and all the organs presented a perfectly natural appearance, excepting the heart. On the external surface were fragments of fibrin, the result of recent pericarditis. On opening the heart, the right auricle and ventricle were filled with a *firm tough clot* of fibrin which nearly closed the auriculo-ventri-

Digitized by Google

cular opening, adhering firmly to the walls of both cavities, and entangled with the carneæ columnæ and chordæ tendineæ, so as to require some force to remove. It also passed some distance into the pulmonary artery, and when cut into, it presented resistance to the knife, leading to the conviction that it could not have accompanied sudden death, but must have been of slow formation, and by impeding the heart's action caused the fainting which preceded death.

Mr. Henry Obré, *4th of March*, 1862.

---

22. *Fibroid deposition in the wall of the heart, and in the pulmonary artery, with complete obstruction of one of its divisions.*

The preparation brought before the Society was obtained from a labourer, æt. 40. Few particulars as to the early part of his illness were recorded. He was known to have been ill for two years, suffering from cough and pain on the right side of the chest. When admitted on the 24th of July he was wasted and feeble. He had much cough with expectoration, and shortness of breath. On examination, a loud systolic murmur was heard at the base of the heart. The right side of the chest was flattened in front, behind there was dulness on percussion, with increased voice-sound, which was described as œgophony. Over the whole of the side the breathing was very deficient, while over the left lung it was exaggerated. The urine was found to be albuminous. He had good diet, bark, and cod-liver oil, and went on without much change until the 21st of August, when his belly was found to be swollen, and a draught was prescribed, containing acetate of potash and iodide of potassium. A week later the abdomen was larger, and the legs were becoming œdematous. He was purged with compound jalap-powder, and various diuretics were added to the mixture, without, however, any diminution of the dropsy. The cough was frequent, and was accompanied with frothy expectoration. His strength failed, the dyspnœa increased with the swelling of the abdomen, and he sank on the 26th of September.

Post-mortem examination.—The body was examined fifteen hours and a-half after death. The legs were œdematous, and the belly distended with fluid. There was a superficial abscess over the right scapula.

When the chest was laid open, the greater part of the cavity was found to be occupied by the pericardium, which encroached much upon the space due to the left lung. The membrane was much thickened, and the cavity contained a large quantity of bloody fluid. Both layers were

Digitized by Google

Digitized by Google

DESCRIPTION OF PLATE II.

Illustrating Dr. Dickinson's case of Fibroid Deposition in the Walls of the Heart, and in the Pulmonary Artery (p. 61).

The large figure represents the right side of the heart, and the pulmonary artery, laid open. A large lobulated fibroid mass is seen occupying the muscular wall of the ventricle, and involving the attachments of the valves. The pulmonary artery is thickened, and rendered irregular by similar deposit; and in the right branch, represented in the plate by a conical depression, is completely obstructed.

The smaller figure represents, in profile, the proximal portion of the obstructed right branch of the pulmonary artery.

Digitized by Google

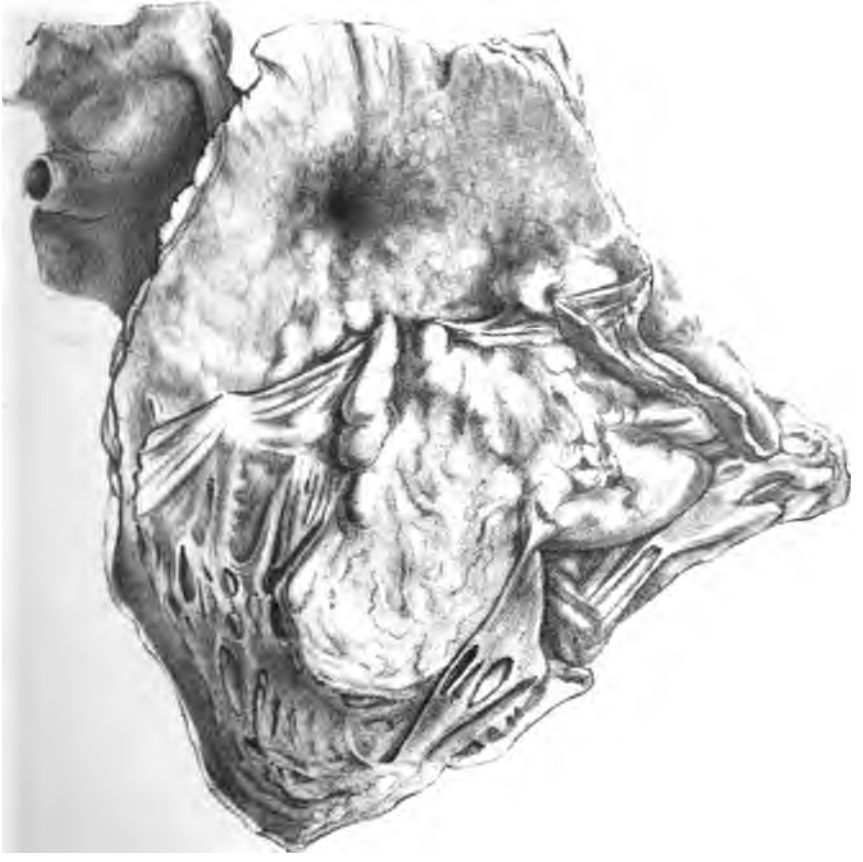

J. O. Westwood del. Tuffen West lith.

W. West imp.

Digitized by Google

Digitized by Google

covered with ragged lymph, firm, and evidently of some standing. They were not attached.

The substance of the heart was greasy and soft. The left side was healthy, excepting a few fibrinous nodules about the aortic valves. A very large lobulated deposition of fibrine (Plate II.), occupied the right ventricle, reaching up to, and partially destroying, the pulmonary valves. The endocardium lining the ventricle, was intensely congested. The pulmonary artery was roughened up to the bifurcation. At this spot the orifice of the right branch was contracted to about the size of the coronary artery. Within this opening was a mass of fibrine, which occupied the entire course of the artery, even to its smaller branches.

The mass of fibrine in the ventricle was quite continuous with that which obstructed the pulmonary vessel. It appeared to have crept upwards, at first between the coats of the artery, though it afterwards made its appearance in the cavity. In the ventricle the fibroid mass was formed, to a certain extent, at the expense of the muscular wall. Under the microscope, the growth presented a good deal of irregular fragmentary and granular matter, of no definite structure. A few minute bodies, like nuclei, were seen, beside which there was a considerable quantity of loose fat. The structure was the same whatever part of the growth was examined.

The right lung was firmly adherent at every point to the parietes of the chest. It was of small size, and solid as if from compression. Every part sank in water. Some masses of fibrine were found in its structure; and the pleura, as well as the interlobular septa of the lung, were greatly thickened by fibrinous deposition.

The bronchial tubes were pervious and natural. The left lung was healthy in its substance, though somewhat compressed by the distended pericardium.

The liver weighed as much as seven pounds three ounces. The surface was smooth. On section the glandular material was distributed in conspicuous dots, separated by whitish subdivisions, which seemed to be an hypertrophied state of the capsule of Glisson. Tincture of iodine turned the glandular structure the reddish-brown colour, characteristic of amyloid degeneration. Under the microscope the cells were granular and fatty.

The kidneys were enlarged, pale, and finely granular on their surfaces. The capsules were adherent. Their texture, on section, was very coarse. Under the microscope, the tubes were separated with great difficulty. The epithelium was leaded with oil. The rest of the abdominal viscera were healthy.

Digitized by Google

Commentary.—It was at first conjectured that the mass of fibrine in the artery had been carried by the blood from the deposit in the heart, and that the case therefore was simply one of pulmonary embolism. A further examination, however, revealed many particulars not to be so explained, which are given in the account of the *post-mortem*. The disease appeared to have been of very slow progress. The right lung was probably completely shut off from the circulation, except by the bronchial artery, for some time before the death of the patient. The tendency to a deposition of fibroid matter showed itself not only in the heart, the pulmonary artery, and in the lung; but in the network of fibrous tissue which appeared on section of the liver; and in the granular state of the kidneys. The pericarditis, which seemed to be the immediate cause of death, might have been produced by the appearance of the deposition upon the outer wall of the ventricle, the muscular substance in one place having been completely replaced by the fibroid matter. Dr. DICKINSON, 18*th of March*, 1862.

Report on the above specimen.—The heart, exhibited by Dr. Dickinson, appears to us to be essentially in the same pathological condition as several hearts which have in former years been brought by members and others under the notice of the Society, and also as several specimens of voluntary muscles which are described in the "Transactions," and regarded as syphilitic. The disease in this, as in former cases, appears to consist in the infiltration and destruction of the muscular tissue, by a buff-coloured or whitish fibroid material, tending to soften and break down in places, accumulating here and there so as to form a kind of tumour, and constituted microscopically of a delicate, but close, irregular fibrillated tissue obscured by abundant granular and oily deposits. Dr. Dickinson's case differs, however, from all others on the records of the Society in the fact that the deposit, instead of being limited to the muscular walls, has been prolonged from them into the parietes of the pulmonary artery, separating by its accumulation the angles of the valves, and increasing in quantity from the origin to the bifurcation of the vessel and along its right branch, so that the latter has become completely occluded by it. The same kind of disease seems also to have involved the right lung to a very considerable extent, producing in it the condition which is known by the name of cirrhosis of the lung. Dr. BRISTOWE,
Dr. S. WILKS, 1*st of April*, 1862.

Digitized by Google

23. *Malformation of aortic valves.*

This specimen was removed from a remarkably healthy-looking old gentleman, æt. 68, who had enjoyed, up to within a few months of his death, uninterrupted health. The cause of death was chronic cystitis, enlarged prostate, and incipient disease of the kidneys. With these exceptions, his organs were in a very healthy condition. The heart was of normal size, its structure firm, and no signs of fatty degeneration could be detected on microscopical examination. There was no appearance of atheroma on any portion of the aorta, which was of ordinary calibre, but guarded by two valves only. The pulmonary artery possessed three.

There existed no other malformation in any part of the patient's body, with the exception of the malformation. The valves seem to have been in a healthy state, and were nearly equal in size.

Query. Is this a congenital malformation? or is it the effect of disease in infantile life?

Mr. BARWELL for Mr. WILLIAMS, *18th of March*, 1862.

---

24. *Aneurism of ham mistaken for abscess.*

A man, æt. 42, had noticed a swelling in his ham for seven weeks. He was admitted into an Infirmary, where, on the supposition of the swelling being an abscess, poultices were applied. Fluctuation being detected at the outer side, a medical man made an incision, and let out a small quantity of pus and grumous blood. The poultices were re-applied at the end of thirty hours after the incision had been made. A profuse and alarming escape of arterial blood took place in changing the dressings. Pressure was applied to arrest the escape of blood, and the patient sent to University College Hospital, where the limb was immediately amputated above the knee by Mr. Erichsen.

On examination after removal, a sacculated aneurism of the popliteal artery was found about as large as an orange, with a large quantity of black coagulum filling up the ham. The case was interesting on account of the length of time the aneurism had been under treatment without any pulsation being detected in it, and from the fact of thirty hours having elapsed between the time of the incision and the approach of arterial hæmorrhage. Mr. ERICHSEN, *15th of April*, 1862.

Digitized by Google

25. *Very greatly enlarged heart without valvular disease.*

This specimen was removed from the body of a man, æt. 35, under the care of Mr. Hutchinson, and whom Dr. Peacock once saw a day or two before his death. He then laboured under extreme difficulty of breathing so as to be incapable of lying down, and his lower extremities were very œdematous. The dulness on percussion in the præcordial region was very greatly extended, the action of the heart was very irregular, but there was no morbid murmur; the pulse at the wrist was scarcely detectable.

The following particulars of his case have been furnished by Mr. Hutchinson.

"I first saw J. B. about nine days before his death. He then, one evening, came into my room, a fine tall muscular man, but with a countenance expressive of very peculiar distress and anxiety. He held his chest bent forwards and spoke little above a whisper, the difficulty seeming to be simply want of breath to make a vocal sound. Sometimes he would make a great effort and say a few words quite clearly and in a loud voice. To my great astonishment I could not find any pulse whatever at either wrist.

"On the following day when I saw him at his house the pulse was perceptible, but it was a mere flutter, and only to be discovered by considerable care. He was, as he had been for a week before, unable to lie down, and whenever he went to sleep, used to wake up under the impression that he was being strangled. His chest was sonorous in most parts and moved well, but the area of cardiac dulness was very much extended. He lived on, in a state of urgent suffering from cardiac dyspnœa, almost without pulse and never able to sleep, for nine days. During the last four days his legs swelled very much, but they had never done so before.

"The history of his case was, that about fourteen years ago he had rheumatic fever. Since then he had led a rough life, having for some time been one of the mounted escort for gold in Australia. During this time he underwent much hardship, and his heart caused him no inconvenience. He returned to England about eighteen months before his death, and about six months afterwards began to feel occasionally heaving sensations at the heart. He also found that he could not walk quickly. He was now employed as an overlooker at a railway depôt, and was accustomed to walk several miles a day. A month before I saw him, he first put himself under medical care, but until within a fortnight of his death he still kept to his work. His age was about thirty-five. He had no albumen in his urine. Never at any period of his

Digitized by Google

life, until as noted during the last few days of his illness, did he observe the slightest œdema of any part. He had always been temperate as regards stimulants."

The heart weighed twenty-six ounces and three-quarters avoir. There were several white patches on the attached pericardium. The cavities of the heart, especially the left ventricle, were very greatly dilated; the walls of the right ventricle were from one and a-half to two lines in thickness, and those of the left ventricle six lines at the outer side. The tricuspid valves were somewhat thickened, the lining membrane of the left auricle was opaque, and the cordæ tendineæ of the mitral valve were stretched, so that the folds were probably not competent to cover the orifice from want of adjustment, connected with the large size of the ventricle. The valves were otherwise quite healthy, and there was no disease of the aortic valves or aorta. The various orifices were considerably increased in size, the aortic orifice admitted a ball measuring forty-five french lines in circumference; the pulmonic, one measuring forty-eight; the mitral, sixty-three, and the tricuspid, sixty-nine.

The cavities of the heart were distended with coagula, and those at the apex of the right ventricle were somewhat adherent to the endocardium.

Dr. Peacock exhibited the specimen as affording a remarkable example of dilatation of the heart from failure of muscular power, without valvular or aortic disease. Dr. Peacock, *15th of April*, 1862.

IV.—DISEASES, ETC., OF THE ORGANS OF DIGESTION.

1. PHARYNX, ŒSOPHAGUS, STOMACH, AND INTESTINES.

1. *Perforation of sigmoid flexure in a case of typhoid fever, with stercoraceous vomiting.*

History.—E. T., æt. 26, was admitted into the Middlesex Hospital, on September 24th, 1861. She was brought from the country, and all the information that could be obtained respecting her previous history was, that she had been ill for six weeks, that her illness commenced suddenly with pains in the abdomen increased by pressure, and that her more prominent symptoms had been frequent vomiting, thirst, and loss of appetite, slight diarrhœa at first, troublesome cough, occasionally slight delirium, and latterly, emaciation and night-sweats. Four

Digitized by Google

days before admission, the vomiting became more urgent, and the vomited matters were very offensive, resembling fæces, while, at the same time, the bowels were freely open.

On admission, the patient was in a state of extreme prostration; pulse 112, small and feeble; tongue moist, thickly furred along centre, red at the edges; urgent thirst and vomiting, the vomited matters consisting of a yellowish-brown fluid, of a very fetid (stercoraceous?) odour; bowels open, motions solid and lumpy; much pain and extreme tenderness of abdomen, especially at lower part, over pubis; moderate tympanites; coils of intestine visible through abdominal parietes; frequent cough, with muco-purulent expectoration; complete dulness on percussion, with distant tubular breathing over the whole of the right side of the chest in front, with coarse crepitation under clavicle; features pinched; great emaciation and profuse night-sweats; occasional attacks of syncope, but no delirium, and mind perfectly clear; a circumscribed pink flush on both cheeks; no eruption.

The patient continued to sink, and died eight days after admission, on October 2nd, the mind remaining clear almost to the last. There was urgent vomiting during the whole period that the patient was under observation, so that nothing was retained on the stomach. Twenty-four hours after admission, the vomited matters were observed to be unequivocally stercoraceous, consisting of solid scybala, mixed with a yellowish-brown fluid, and they retained this character until the last, a stercoraceous odour being likewise exhaled with the breath. For two days after the commencement of the stercoraceous vomiting, the bowels were freely open, the fæces exactly resembling the matters ejected from the stomach. After this nothing was passed from the bowels, except a little fetid yellowish fluid, with the nutritious enemata.

Post-mortem examination, thirteen hours after death.—Extreme emaciation; marked rigidity of limbs; greenish discoloration of abdomen.

The great omentum was glued to the abdominal parietes, by easily separable adhesions of soft lymph. The serous surface of the bowels was covered by a very thin layer of lymph, which could be scraped off with the knife. The opposed surfaces of the coils were at many places intensely injected. In the cavity of the pelvis was a circumscribed peritoneal abscess, surrounded by the sigmoid flexure, the fundus of the bladder and of the uterus, and by several coils of the ileum. The contents of this cavity amounted to about ten fluid ounces, and consisted of an opaque dirty-yellowish fluid of a fæcal odour. The whole of the small intestines down to two or three inches below the connection of

Digitized by Google

the first coil of the ileum with the abscess, or, in other words, about seven feet from the commencement of the jejunum, were greatly distended with flatus and with fluid fæces like pea-soup, which were likewise found in great quantity, both in the stomach and in the œsophagus. The intestines below the spot above mentioned, comprising the whole of the lower part of the ileum and the entire large intestine, down to the sigmoid flexure, were contracted, and, for the most part, empty, except a few scybala in the cæcum. On slitting up the large intestine from the anus, the bowel was found to become contracted at the lower part of the sigmoid flexure. The mucous membrane over the lower three inches of the sigmoid flexure, which corresponded to the peritoneal abscess, was of a dark crimson-colour from vascular injection, and likewise presented several patches of submucous ecchymosis. In this injected part, seven inches and a-half from the anus, was a perforation, large enough to admit a swan-quill, extending through the entire coats of the bowel into the abscess. There was no ulceration or puckering around the perforation.

The lower end of the ileum close to the valve was thickened, and the mucous surface was rough and irregular from the presence of numerous minute depressions or excavations. These depressions varied in diameter from one to three or four lines; their edges were not at all thickened, so that most of them were only visible, when the light was made to fall on them at a certain angle. These depressions were more marked on following the bowel higher up, and about two feet above the valve they passed into characteristic typhoid ulcerations. All of the ulcers corresponded in situation to Peyer's patches. The edges of the ulcers were not at all thickened; none of them presented any adherent sloughs; the mucous membrane surrounding most of them was moderately injected. Nothing abnormal was observed on the mucous surface of the ileum corresponding to the abscess, or where the bowel suddenly became smaller.

The mesenteric glands were enlarged up to the size of a filbert, but not softened. The spleen weighed two ounces and three-quarters, and was rather firm. The liver weighed forty-seven ounces, was pale and anæmic, but in other respects, normal. The gall-bladder contained half-an-ounce of inky bile; its mucous membrane was not ulcerated. The kidneys were anæmic; the other abdominal organs were normal.

The right cavities of the heart contained a pale, adherent coagulum; the left were empty. The valves and muscular tissue were normal.

The right lung was inseparably adherent, with about half-an-ounce of pus between its posterior surface and the wall of the chest. The

Digitized by Google

entire lung was condensed, most of it sinking in water and very red; it was likewise extremely friable, and at some places granular on section. The left lung was firmly adherent at the apex, which was puckered and condensed, and contained small encysted masses of yellow putty-looking matter (tubercle). The dependent part of the lower lobe was much injected, extremely friable, and infiltrated with serous fluid, but floated in water. There was no indication of recently-deposited tubercle in either lung.

Remarks. — During the patient's life, considerable doubts were entertained as to the nature of her case, as she did not come under observation in the first six weeks of her illness. The most probable theory was thought to be general deposit of tubercle in the lungs and peritoneum; and it was suggested, that the coexistence of stercoraceous vomiting with a free passage of the bowels, might be accounted for, on the supposition of a fistula between the stomach and colon, consequent on the softening of an intervening mass of tubercle (See *Memoir on Gastro-Colic Fistula*, "Edin. Med. Journ.," for July and August, 1857). The existence of undigested food in the stools, necessary to corroborate such a supposition, could not be observed. The *post-mortem* examination left no doubt that the case had been one of typhoid fever. It might be a question, whether the abscess was due to a typhoid perforation of the sigmoid flexure, or to a perforation of the ileum, the abscess afterwards bursting into the colon. The absence of any signs of cicatrization, on the mucous surface of the coils of ileum adherent to the abscess, favoured the former view. Typhoid perforation of the large intestine, although rare, has occasionally been observed; two cases are recorded by Forget (*Enterite Folliculeuse*, 1841, p. 354); one by Chomel (*Fièvre Typhoïde*, Paris, 1834), and one by Brinton ("Trans. Path. Soc.," Vol. IX., p. 199). In two of these four cases, the perforation was situated in the same locality as in the above observation, at the junction of the sigmoid flexure with the rectum; in the other two, it was situated at the junction of the transverse, with the descending, colon. Dr. MURCHISON, *15th of October*, 1861.

---

2. *Typhoid fever occurring in the seventieth year of age.*

The specimen of ileum presenting the well-known typhoid deposit in the glands is only interesting in connection with the age of the patient whence it came, it being unusual to meet with this form of

Digitized by Google

disease at so advanced a period of life. It is agreed by all observers, that typhoid fever is not often met with at this age, just as true typhus is less common in children. This fact was thought by the older physicians sufficient to explain the difference between these two forms of disease, that the younger subject in whom the powers of life are greater, and the intestinal glands in a state of greater activity, is more liable to the typhoid form, or, as it was formerly called, common continued fever with the intestinal complication, whilst the patient at a more advanced period of age is more liable to have the genuine typhus where the intestine is not affected. It has been said, that the mulberry rash of the last-mentioned form is due to the greater prostration of the patient at this age, and should the younger subject by chance have a similar eruption it is due to some accidental debilitating causes which have placed him in a similar position to the older one. Such opinions are easily combated by those who maintain the specific forms of the two diseases, but even these are agreed as to the greater susceptibility of patients of different ages to a particular form of fever; thus, Dr. Tweedie says, "Typhoid fever is seldom observed above the age of fifty. It is not unlikely, that the alterations which Peyer's patches undergo with advancing age, may have something to do with the infrequency of enteric fever after the age of fifty." It may be questioned, how far this statement is absolutely true, since in the absence of *post-mortem* examination a considerable difficulty might exist in forming a correct diagnosis of the nature of the case, seeing that typhoid does not present so well-marked symptoms in the old, just as typhus is more obscure in the young. In the case which suggests these remarks, the disease was supposed to be typhus, and it was only the *post-mortem* examination which revealed the true nature of the disease.

The patient, a woman, was in her seventieth year, she had been ailing about two weeks with the ordinary symptoms of fever when she was brought to the Hospital. She was then in an extreme state of depression with excessive nervous and muscular debility, was quite insensible, and was delirious. There was no mulberry rash, the skin being quite clean, nor were any rose spots observed, and during the three days she lived the bowels were open only once daily, and the motions were semi-solid. The *post-mortem* examination showed the typhoid disease well-marked in the ileum; Peyer's glands being considerably enlarged by the deposit.

The case may, therefore, be regarded as a good one in exemplification of the specific nature of the typhoid affection, for all the circumstances of the patient were those which should have ensured the

Digitized by Google

development of typhus with the mulberry rash, and yet here in spite of age, the true characters of the typhoid disease were all present.

Dr. S. WILKS, *15th of October*, 1861.

---

3. *Rupture of diaphragm. Displacement of liver and stomach into left pleura. Rupture of stomach and left kidney. Fracture of leg.*

S., a lad, æt. 19, was killed by the accident on the Kew and Hampstead Railway, on the evening of the 2nd of September, 1861. His body was brought to the Middlesex Hospital, and was examined forty-three hours after death.

Numerous subcutaneous ecchymoses of head, trunk, and extremities: one of these, ten or twelve inches in diameter, was situated on the anterior aspect of the lower part of the chest and the upper part of the abdomen. There was a compound comminuted fracture of the left tibia and fibula, about the middle.

Several large patches of ecchymosis on left side of scalp, but no extravasation within the cranium. No fracture of cranium.

Both lungs non-adherent. Left lung displaced forwards by the left lobe of the liver, and almost the entire stomach with its contents, which were projected into the chest, through a large rupture in the left side of the diaphragm, and reached as high as the second rib. The left pleura also contained about half-a-pint of bloody fluid, mixed with the contents of the stomach. The left lung was collapsed, dry, and anæmic, and weighed only seven ounces and a-half, but in other respects was normal. The right lung weighed thirteen ounces and a-half, and presented a patch of extravasated blood, about one inch and a-half square, at the anterior extremity of the middle lobe, corresponding to a subpleural ecchymosis on the posterior surface of the right costal cartilages.

The heart was displaced considerably to the right; its apex corresponding to the right margin of the sternum. The blood in the heart and great vessels was perfectly fluid, and was not coagulated at the end of two hours after the body was opened.

The rupture in the left side of the diaphragm measured twelve inches in circumference. In the peritoneal cavity immediately adjoining this cavity, was about one fluid ounce of the contents of the stomach, but there were no signs of peritonitis. The stomach was distended with a large quantity of undigested food, but there was no appearance of *post-mortem* digestion of its coats. About the middle of the great curvature was a rupture through all the coats, measuring

Digitized by Google

one inch and a-quarter in length, perfectly linear, like a cut, and with no attenuation or discoloration of the surrounding walls.

Liver, fifty-five ounces, hyperæmic, but structure normal. Upper surface of left lobe marked about its middle by a deep furrow, at the bottom of which the hepatic tissue was pale and bloodless. This corresponded to the edges of the rupture in the diaphragm, which had compressed it. The portion of liver which lay beyond this, in the cavity of the chest, was very dark and hyperæmic.

The spleen was four ounces and a-half, and rather soft. Its axis was reversed, its lower extremity being drawn up by the stomach into the rupture.

The right kidney weighed four ounces and a-quarter. It was very hyperæmic, and there was considerable ecchymosis of the surrounding adipose tissue. The left kidney weighed four ounces and three-quarters, and was also very hyperæmic. It presented a rupture, one inch and a-quarter long and one-third of an inch in depth, running transversely across the anterior surface, at the junction of the upper with the middle third, and there was considerable extravasation of blood into the surrounding adipose tissue.

Dr. MURCHISON, *5th of November*, 1861.

---

4. *Infiltrated scirrhous stricture of the œsophagus.*

A fish-salesman at Billingsgate, æt. 50, had enjoyed good health until about five months before his death. He first complained of some difficulty in swallowing solids, not unfrequently almost choking, which was only relieved by sickness. Frequently this was merely the regurgitation of the bolus of food last swallowed, mixed with ropy mucus and saliva. This difficulty rapidly increased. For the last two months he was kept alive by liquids and nutrient enemata.

At the *post-mortem* examination, the body was extremely emaciated. There were old adhesions at the apex of both lungs. The abdominal organs were healthy, except three small nodules of scirrhus on the under surface of the liver. On examining the œsophagus, the stricture was found to commence exactly on a level with the bifurcation of the trachea, and extended downwards for about two inches. It just admitted a No. 4 bougie. When laid open, an ulcerated surface was exposed, grey, soft, and pulpy.

Between the strictured portion and the adjacent descending aorta, the areolar tissue was infiltrated by hard cancerous material; and in the aorta itself a corresponding longitudinal projection existed, caused by

Digitized by Google

infiltration between the coats of the vessel, which at this part had a thickness of more than a quarter of an inch.

Under the microscope the diseased structures presented numerous large cells of various forms, with one or two distinct nuclei. Many of the cells were fusiform. Mr. BUXTON SHILLITOE, *5th of November*, 1861.

---

5. *Disease of the appendix vermiformis, with a small aperture in it, and acute peritonitis.*

Six months before this young man was taken ill, he had the right arm torn off, and the limb so mutilated by machinery, that in amputating at the shoulder-joint I had some difficulty in procuring skin enough to make a good flap.

He made an excellent recovery, and in three months was at his work again. I am doubtful, but think it probable, that he might at the time have been crushed in the abdomen, as he was carried round a shaft revolving rapidly. However, he became apparently as well as before the accident, and made no complaint until he was suddenly seized with symptoms of intense diffuse inflammation of the peritoneum, and died in less than three days.

On a *post-mortem* examination, there was found a large effusion of lymph in the right hypogastric region, glueing all the bowels together, and covering the whole cæcum with a thick coating. A very small escape of fæcal matter had taken place. On removing the cæcum, as here seen, the exterior of it was considerably thickened, and the lymphatic glands attached to it were large and dense. The appendix vermiformis was tied down, and much thickened; its cavity was nearly filled up and closed by lymph; a small ulcerated aperture had formed at its base, while the communication with the cæcum was closed, and the mucous membrane at this point of the bowel was thicker and rougher than natural.

No other disease could be found.

He had always been a small, rather delicate lad.

Mr. NUNNELEY, *19th of November*, 1861.

---

6. *Rupture of the stomach.*

When I first saw the subject from whom this specimen was taken, he was a remarkably fine, stout, handsome man. Two years afterwards, he came under my professional care. He had then been ill for some months, during which, so far as I could ascertain, with the exception

Digitized by Google

of great debility and rapid emaciation, there had been few symptoms of acute disease. At this time he was suffering from pain in the stomach after taking food, and vomiting, which appeared to have been occasioned by large doses of muriated tincture of iron, which had been prescribed for him; as the omission of the iron, and the administration of alkaline salines was at once followed by their disappearance. Subsequently, under the use of bitter infusions with the milder preparations of iron, he considerably improved, and gained both flesh and strength.

I now lost sight of him for some months, as he removed to a distant part of the country, and subsequently took a tour on the Continent. On his return, which was hastened by his becoming worse, I found him reduced to almost a skeleton, and so weak as hardly to be able to walk. He could take but little food, and that little, every second or third day, appeared to be rejected by vomiting. The character of the complaint, which previously had puzzled all who had been consulted, was now far more pronounced; yet even now, one gentleman of large experience regarded the disease as rather of greatly enlarged spleen than as seated in the stomach, and another, as stricture of the lower bowel. Though the symptoms rather pointed to stricture of the pylorus than either of these, yet the entire absence of any indication of malignant disease was thought to militate against this opinion. Without any assignable cause, shortly after his return, he was suddenly seized with an attack of acute pleurisy. As little medicine could be administered by the mouth, and the bowels were confined, two days afterwards an enema was given, when, getting out of bed to the commode, he was seized with intense prostration and great pain in the abdomen. He died within an hour after.

On opening the chest, the lungs were found to be healthy; but there was some bloody serum effused into both pleuræ and the pericardium.

In the abdomen was a large quantity of semifluid alimentary matter, of a dark colour from the admixture of blood, which must have very recently escaped, as there was not the least trace of inflammatory action. In the posterior wall of the larger curvature, at the greater end of the stomach, was a hole through which a finger could easily be passed. The margin of this aperture was round, soft, and sloughy. The size of the stomach was larger than natural; several ulcerations of the mucous membrane, with some ecchymosed patches, were seen; the whole membrane was soft, in several places thin, and in some parts the walls of the stomach were not thicker than tissue paper. In one spot was found a large, distinctly puckered patch, as though resulting from a cicatrized ulcer. The pyloric orifice was small, and this end of the

Digitized by Google

stomach contracted; the mucous membrane and submucous tissue were much thickened, and the villi largely developed, but without any trace of malignant disease.

The small intestines were healthy; but the larger were much contracted in parts where the membranes were hard and thickened, while the sacculi were greatly distended and their membranes extremely thin.

The other viscera were healthy.

Four years before this last illness, while in the Crimea, this subject had suffered from a long and obstinate attack of dysentery, which may account for the condition of the larger bowel.

Twelve years ago, he had a long illness, attended with loss of appetite, and great debility and emaciation, which was relieved by a residence of several weeks in the Mediterranean. This, in all probability, was connected with the condition of the stomach, of which the puckered patch is the remains.

Mr. NUNNELEY, *19th of November*, 1861.

---

7. *Stricture of œsophagus, with abscess opening into it and the bronchial tube.*

I saw the subject from whom this preparation was taken, a month before his death. He was a large man reduced to a perfect skeleton. He had possessed property and occupied a farm, but being reduced to poverty, he had latterly been employed as a porter in a dusty warehouse, to which he attributed his illness. This, he had been told, was a stomach complaint. He had for some time noticed an increasing difficulty in swallowing, which for upwards of a fortnight had prevented him from taking any food whatever; all, whether liquid or solid, being rejected before reaching the stomach. He had no pain; the respiration was feeble but not difficult; when quiet, there was no cough, but he continually spat up without effort a considerable quantity of pus. He was extremely hungry, in fact was dying of starvation. With the exception of the extreme emaciation he had not an unhealthy appearance.

There was neither swelling nor tenderness in the course of the œsophagus, and no abnormal respiratory sounds except the feeble murmur. I saw him more than once attempt to swallow both liquids and solids, which he did most carefully, but after passing some distance down the œsophagus, the food was rejected with violence, and a sense of suffocation. Nutritious enemata, with a few drops of laudanum, gave him

Digitized by Google

immense relief; and if not followed, as he thought, by an increase of strength and flesh, at least prevented much more wasting.

For upwards of six weeks, except on one occasion, nothing whatever was swallowed. I had passed a long tube down the œsophagus until I found it stopped, when a considerable quantity of offensive pus passed up the tube. Soon after this he drank freely three cups of tea, and was able to do the same the following morning, but never afterwards. A few days after this, I yielded to his entreaties and again passed the tube as carefully as possible, when I distinctly felt it leave the line of the œsophagus, and pass into a cavity; a choking sensation with cough and expectoration of pus was immediately induced, but no power of swallowing. A few nights afterwards he spat up and vomited several ounces of most offensive bloody matter. A week subsequently he died from exhaustion.

On *post-mortem* examination, I found the œsophagus towards its lower third quite impervious for a short distance, with a large opening above this spot into a considerable abscess, which also had a free opening into the bronchus, so that there was a ready communication between these two tubes.

The dark glands about the bifurcation of the trachea were numerous, and large, and there was a good deal of consolidation of the tissues here.

All the thoracic and abdominal viscera were healthy.

Both clavicles had been broken and united very irregularly. This accident was occasioned by his horse falling with him when tired after a long day's hunting. He was much hurt from the horse rolling on him. This happened about two years before his fatal illness, and is more likely to have been the origin of it, than the dusty warehouse to which he attributed it. Mr. NUNNELEY, *19th of November*, 1861.

---

8. *Large inflamed fibro-cystic ovarian tumour with incarcerated hernia.*

I was requested to operate for hernia in a woman, æt. 73. She had been ill three or four days with such symptoms as induced the medical attendant to suppose they arose from strangulation of the protruded gut, which he could not reduce.

The hernia was of long-standing. No truss had been worn, and though not usually so large as it then was, so far as could be ascertained had never been entirely reduced. But finding that the sac was not tense or hard, that I could return at least a portion of the gut, and that there was less pain and tenderness in the sac and its vicinity than over the abdomen generally, particularly towards the left side, and that the

Digitized by Google

patient was in a most feeble condition, I declined to operate, not thinking the symptoms arose from strangulation. The next morning the woman died.

On *post-mortem* examination, there was found diffused inflammation over nearly the whole peritoneum, with a good deal of effused fluid in the cavity, and patches of lymph upon its surface, and upon the large sac now shown. This sac was much injected, and, where not solid, filled with bloody fluid and grumous blood. It was connected with the left ovary.

There was no strangulation in the large thickened femoral sac, nor any appearance of inflammation upon it or the contained ilium, as these parts will show.

The hernia was femoral of the right side, though when first seen so large as to make it difficult to say whether it was femoral or inguinal.

The woman had been ill for eighteen months, during which she had commonly referred her symptoms to the body, in which she had not unfrequently complained of having severe pain.

Mr. NUNNELEY, 19*th of November*, 1861.

---

9. *Case of medullary cancer of the stomach associated with dropsy.*

A man, æt. 39, who had served thirteen years in the army—chiefly on foreign service—was admitted into the Regimental Hospital on the 12th of July, 1861. He complained of tenderness in the hepatic region, and general pyrexial symptoms were present. On the following day, the case assumed all the characteristics of subacute peritonitis, and there was occasional vomiting. The usual treatment was resorted to, including depletion to a small extent, the type of the disease being asthenic. By these means all the symptoms were greatly relieved, but effusion immediately supervened. Alterative mercurials and diuretics were exhibited without effect, and, on the 16th of August, so much dyspnœa existed that it was found necessary to tap the abdomen. Eighteen pints of clear serum were drawn off with great relief, and the previous plan of treatment was again employed, but without benefit, inasmuch as the fluid again began to collect. At this date (August 18th), nausea and vomiting became more frequent and distressing, while the emaciation was increasing much. The matter ejected from the stomach at first seemed to be merely the usual contents—undigested food,—but on the 1st of September and subsequently, the ejected substance, which was of a dark colour and semi-liquid, had an odour so offensive, at times quite stercoraceous, that the medical officers were

Digitized by Google

inclined to believe that either some fistulous communication existed between the intestine and stomach, or else that a state, more or less complete, of intus-susception existed. The bowels became at the same time much constipated, but enemata brought away healthy evacuations. Tenderness in the epigastric region was present, but not to any considerable extent. The vomiting increased in frequency and severity, all nourishment taken causing first nausea, and a minute or two afterwards ejection of it. This distressing chain of symptoms continued, scarcely relieved by any remedy, and he died in a state of extreme emaciation on September 10th. The skin throughout was of a dusky-yellow colour, but nothing abnormal was discovered in the urine. On the day before his decease, some dark blood coagula (apparently) were vomited, quite stercoraceous in character, and the breath was equally offensive. The only nutriment taken for the last few weeks was beef-tea enemata, and latterly these could not be retained long enough to be absorbed into the system.

Post-mortem examination.—Four pints of clear serum were found in the cavity of the abdomen. The whole of the intestines and the other abdominal viscera were most firmly agglutinated together by lymph; the peritoneum throughout being much thickened and black in colour. The intestines formed a ball and could scarcely be separated without tearing them. This was especially the case with the stomach, the walls of which could not be detached from the liver. On opening the viscus the cardiac orifice was found encircled by a morbid growth (medullary cancer) as large as a turkey's-egg in the aggregate. Only a chink large enough for the passage of a sixpenny-piece was left open in the centre. The liver was pale, but otherwise no lesion was observed. The intestines were not opened, neither were the other viscera examined.

The peritonitis in this case would appear to have been set up and caused by the disease in the stomach, antecedent to the production of any symptoms of so serious a malady in the viscus, and hence the diagnosis of this lesion was necessarily obscured. The man had remained at his duty until the day of admission. The question as to the rate of progress or growth of such disease, is one of much interest with reference to the prognosis, and it would in the present case appear to have been *very* rapid. Another point of interest is:—To what cause was the stercoraceous smell of the ejected matter and of the breath attributable? The intestines were unfortunately not cut open, and it is possible that some obstruction, dependent perhaps on their want of peristaltic action, arising from their fixed position, and allowing of regurgitation of their contents, may have existed. My

Digitized by Google

own impression however certainly is, that the smell was caused rather by the decomposition of portions of the morbid growth by the gastric juice. Dr. Robinson, *3rd of December*, 1861.

---

10. *Two cases of typhoid fever.*

The following two cases of typhoid fever, which occurred almost at the same time, differed so much from the typical forms of the disease, and, at the same time, so much from one another, that I have thought it worth while to associate them in the present communication.

In the first case, the disease was ushered in with symptoms of acute maniacal excitement, which continued for about a week; and which, just about the time when in the more usual forms of the affection delirium commonly makes its appearance, were succeeded by perfect consciousness, which persisted during the remainder of the patient's illness. No rash was at any time visible; and symptoms of gastro-intestinal disturbance were by no means prominent. They were totally wanting throughout the maniacal stage, but seem to have been present at the onset of the disease, and to have reappeared during the last week of the patient's life. At the *post-mortem* examination the evidence that typhoid fever had existed, though conclusive, consisted solely in the presence of one small ulcer above the ileo-cæcal valve, and two very minute ulcers in the colon, together with a few large congested softened suppurating glands in the neighbourhood of the cæcum. The patient seems to have died, not from the immediate influence of the typhoid poison, nor yet from debility caused by the extent or the effects of intestinal or other lesion, but from the excessive prostration induced by the severe attack of mania.

In the second case, there was neither diarrhœa nor rash; but there were symptoms of bronchitis, tendency to vomit, delirium, and, almost from the first, extreme collapse. The explanation of whatever was anomalous here is afforded both by the history of the case, and by the *post-mortem* examination. The history showed the duration of the disease to have been between five and six days only. The *post-mortem* equally established that the disease, even at the time of death, was in its earliest stage. There was no intestinal ulceration whatever, but there was very extensive typhoid deposit in the lower part of the ileum, and the mesenteric glands of the neighbourhood were enlarged, reddened and soft. The patient had manifestly been prostrated at the first by the virulence of the poison which he had received; and

Digitized by Google

died, as occurs even more frequently in other fevers, before the usual features of the disease had had time to reveal themselves.

CASE I.—*Typhoid fever. Acute mania. Very slight intestinal disease.* J. S., a grocer's assistant, æt. 20, was admitted into St. Thomas's Hospital, under my care, on the 13th of December, 1861. I saw him first on the 14th, and learnt that he had been seized on the 9th, with what was called a "bilious attack," of which the most important feature was great sickness. He got better of this, and on the 12th began to be "queer" in his head; he became violent that night, and has continued so ever since. He seems to have been perfectly well prior to the access of his present illness, had never previously been seriously indisposed, and had been perfectly temperate in his habits. There was no history of insanity in his family.

He is now in a state of maniacal excitement, but replies to questions, and does for the moment as he is bid. Bowels confined; skin hot; no rash. Face and forehead appear flushed, but this is said to be natural to him.

Ordered an effervescing saline mixture every six hours; five grains of calomel and five of compound colocynth pill immediately; milk diet; beef-tea; hair to be cut close.

15th.—Has had no sleep, talked nonsense all night, and was with difficulty kept in bed. Is rather more rational this morning, answers when spoken to and does what he is told. Says he is tired and parched. Face flushed; skin hot and dry; neither rash nor jaundice; pupils dilated; tongue furred and dryish; has only taken fluids; no abdominal tenderness or fulness; bowels opened by pills (with aid of an injection); evacuations passed under him; pulse 128.

A blister to the nape. An egg.

16th (ten A.M.).—Was very violent and noisy all night, acting like a maniac. Did not sleep; the blister has not risen well; the bowels have not been relieved; passes much urine, all under him; looks wild, and tosses about constantly; hears and partly notices what is said to him, occasionally answers, but incoherently, will not show his tongue; face paler than it was; skin neither hot nor moist; no rash; pulse 128.

Ice to head; extra milk; two eggs; three glasses of sherry; ordered also, by resident officer, one drop of croton-oil.

(Half-past eight P.M.).—Has been much quieter for the last half-hour. Has his eyes closed, and seems to have dropped off to sleep, but mutters, talks incoherently, and is constantly moving his arms about on rousing him, he seems more sensible than he has been, puts out his tongue at once, and says he is better. Tongue dry and brown; sordes

Digitized by Google

on teeth; skin cool, but dry; pulse 132; bowels open twice, under him. The nurse states that he passes blood with his urine.

17th.—Continued pretty quiet until midnight, after which he again became very violent. He has this morning, however, had a distinct sleep of two hours. He is very restless, but seems more rational; skin hot and dry; tongue dry and brown; bowels relieved during night, everything passed under him; pulse 136; skin of buttocks getting chafed.

Four glasses of wine.

18th.—Slept very well last night; is much more rational and quiet, and altogether better this morning; pulse 124; says he has pain in the head, and great thirst. The tongue is morbidly red and clean, but smooth and dry; the face is flushed; the skin warm and dry; no rash; boils on the buttocks. This morning, for the first time, he has passed his urine consciously; its specific gravity is 1016; it is highly albuminous, and, under the microscope, presents many blood-corpuscles, but no casts.

To take an ounce of the compound infusion of gentian thrice daily, in place of former mixture.

19th.—Much better; slept well yesterday evening, but not in the night; is now quite sensible. Recollects nothing of his being brought to the Hospital; says his mouth is dry, that his neck and shoulders ache, and that he is very weak. Tongue clean, perhaps rather redder than natural; pupils contract naturally; skin warm and dry; pulse 116; evacuations passed naturally; urine still contains blood.

* * * * * *

26th.—On the evening of the 19th I went out of town, and have not seen the patient again until to-day. I learn that during my absence he has continued perfectly intelligent, but has been gradually becoming excessively prostrate and emaciated, and that many boils have formed on his back, arms, and elsewhere. On the 20th he was attacked with violent vomiting and purging, which lasted continuously for forty-eight hours, and has broken out two or three times since. On the 21st he was ordered chalk-mixture and opium every four hours, a glass of brandy, and soda-water. On the 23rd, the brandy was increased to two glasses, and on the 25th to two and a-half.

He is now excessively emaciated and feeble, but quite sensible, complains of some headach at times, and constant pain across the upper part of the belly; he sleeps, but rather restlessly. Cheeks flushed; skin hot, no perspiration; tongue covered with a whitish fur; thirsty, no appetite; bowels now regular; evacuations passed consciously; urine

Digitized by Google

sp. g. 1013, with a trace of albumen; pulse 140; there are bed-sores on the back.

Effervescing mixture every four hours, instead of other medicines. An injection to be administered twice a-day, consisting of half-a-pint of beef-tea, half-a-drachm of laudanum, and one egg.

28th.—Quite sensible; looks, and says he is rather better; sleeps little; face flushed; skin hot; tongue clammy, but not furred; great thirst; no sickness; pain in chest relieved; bowels not loose; retains injections; specific gravity of urine, 1017; no albumen; pulse, 148.

Four eggs.

29th.—He died quietly this morning at forty-five minutes past seven.

Post-mortem examination.—The body was emaciated, and presented commencing bed-sores about the buttocks. The cerebrum, and other contents of the cranial cavity, were all healthy. The thoracic viscera were in a perfectly normal condition. There was a single circular ulcer, half-an-inch in diameter, immediately above the ileo-cæcal valve; there was no adherent slough, and its floor was formed by the muscular parietes. There were also two minute ulcers in the colon, each about a quarter of an inch broad, situated on a thickened base, and presenting a partially separated slough. Several mesenteric glands, close to the end of the ileum, were enlarged to the size of walnuts, congested and softened, and one of them was partially converted into an abscess. All the remaining abdominal viscera were healthy.

It should be added, especially, that the kidneys were quite healthy; and that hence the opinion entertained during life was confirmed, viz., that the hæmaturia, present for a limited period, had been caused by the application of a blister, and had not depended on any actual kidney disease.

Case 2.—*Typhoid fever. No diarrhœa. Death on the sixth day. Early stage of intestinal disease.*—J. H., æt. 24, a hosier, was admitted into St. Thomas's Hospital under my care, on the 30th of December, 1861. He was at once prescribed, by the resident officer, an effervescing draught every four hours, and a purge of calomel and rhubarb; he was put also on milk diet and a pint of beef-tea. Early next morning, half-an-ounce of castor-oil was administered, and two glasses of wine were ordered.

I saw him first about midday on the 31st; and learnt, partly then and partly subsequently, that on the previous Christmas-day he was in his usual health; that on the 26th he took a long ride on horseback, and became in consequence a little fatigued and stiff; that on the morning of the 27th he complained of lassitude and giddiness, and in

Digitized by Google

the middle of the day by the direction of his employer gave up work; that on the 28th he was worse; and that in the afternoon and night of the 29th he rambled slightly; that he had had no diarrhœa; that no persons in the extensive establishment with which he was connected, and in which he dwelt, had been indisposed; and that the premises were perfectly free from ill smells and thoroughly drained.

He had no sleep last night, and was constantly rambling and muttering. The bowels have been acted on once by the castor-oil, and the motion was very offensive, and passed in bed. His urine has also been voided involuntarily ever since admission. He is now excessively prostrate, lies on his back, mutters nonsense, but when roused answers questions pretty correctly. Face pale; skin warm, not moist and without trace of rash; lips dry; tongue fissured and furred and moist. He has some sore-throat and difficulty of swallowing, but the fauces look healthy. Pulse 128, regular, soft. Is troubled with a hacking cough, unattended by expectoration; chest resonant; general but slight rhonchus and subcrepitation; says he has pain, and points to both iliac regions as its seat; but the belly is flaccid and there is no pain on pressure. Ordered another pint of beef-tea and two eggs, the whole of the beef-tea and the eggs to be administered, night and morning, by injection.

January 1st.—Slept little and rambled much. The first injection was returned immediately; the second, given this morning, has been retained. He is evidently weaker this morning. He is pale and vacant-looking, mutters to himself, but answers when spoken to. The bowels have not been relieved since yesterday; his urine is still passed under him. Skin warm and dry; no rash; herpetic eruption round lips; tongue furred and moist, somewhat fissured. Takes scarcely anything, even to drink; seems inclined to vomit, and has apparently considerable difficulty in swallowing. Still suffers from constant hacking cough, but the chest is resonant, and the breath-sounds are pretty healthy. Pulse 152. Has no pain anywhere, and no abdominal tenderness or enlargement. Early this morning he had several shivering fits; and he appears to have had one also on the day of admission.

Wine increased to four glasses; and a glass of brandy to be given in addition. He remained in an excessively prostrate condition, and died the same evening at ten minutes past nine.

Post-mortem examination.—The lungs were congested, and presented slight lobular pneumonia posteriorly. The bronchial tubes contained a good deal of mucus. The spleen was rather large and soft. Throughout the last twelve inches of the ileum, the mucous membrane was extensively diseased. There was no ulceration, but the membrane was

Digitized by Google

greatly thickened, especially in the situation of Peyer's patches. The thickening was somewhat tuberculated, and was clearly due to some whitish infiltration, extensively diffused, but occupying chiefly the region just mentioned. The mucous surface of the affected bowel was softened, and its colour variegated, from the intermixture of congestion and of the whiteness due to the deposited material. The disease increased in intensity from above downwards. Several mesenteric glands adjoining the diseased portion of bowel were enlarged to between the size of a filbert and that of a walnut, and were softened and congested. There was no further disease of the bowels, nor of the other chilo-poietic viscera, nor in fact of any of the other organs or tissues of the body.

Dr. Bristowe, *7th of January*, 1862.

---

11. *Fibroid disease of the stomach.*

This disease has also been styled hypertrophy of the walls of the stomach, or by some cirrhosis, since a development of fibrous tissue beneath the mucous membrane appears to constitute the primary process in the change which the organ undergoes. The specimen came from a woman, æt. 44, who was admitted into Guy's Hospital, under Dr. Wilks's care, in December, 1861. She was a laundry-woman, and no doubt accustomed to spirits, though there was no proof of her having been very intemperate. For a few weeks before admission, she had been ailing with pain and swelling of the abdomen, but never any more decided symptoms. On admission, she was not extremely ill, and her principal affection was ascites. A cause for this was sought for in the liver, but there being no very decided proof of hepatic disease, it was thought probable that a cancerous disease of the peritoneum existed. After being in the Hospital three weeks, and somewhat improved in health, she was seized with peritonitis, and died. It may be stated, that her health was tolerably good, and that she never had sickness until a few hours before death.

On *post-mortem* examination, after emptying out the fluid, the peritoneum was found throughout opaque and contracted, from chronic inflammation. The intestines were drawn back by the mesentery; and the omentum was dragged up and contracted. The colon, also, was much contracted, and the appendices epiploicæ firmly bound down upon it. The stomach presented a most remarkable appearance; instead of being collapsed and feeling soft, it projected outwards into the abdomen, and felt thick and hard, very like a tough india-rubber bottle. It was of ordinary size. When cut open, the walls were seen to be of enor-

Digitized by Google

mous size, amounting to an inch in thickness towards the pyloric end. This increase in size was due to hypertrophy of the muscular coat and development of a large quantity of fibre in the submucous coat, these two layers being about equal in thickness. This submucous tissue was of a dead white colour, and very tough; when examined by the microscope, it was found composed simply of fibre. The muscular coat external to this was nearly half-an-inch thick, and had the usual grey, translucent appearance. External to this, in some parts, the peritoneal tissue was much thickened by dense fibre, of a similar character to that next the mucous membrane. This hypertrophy of the coats extended throughout the length of the stomach, from the pylorus to the œsophagus, and a short way up the latter tube. At the lesser curvature of the stomach there existed a large gland. This, on examination, did not appear to contain any adventitious products. The large intestine was affected in a similar way to the stomach, but to a less degree; the ascending and descending colon not so much as the transverse colon, sigmoid flexure and rectum. Here the coats were excessively thickened; the muscular coat, as in the stomach, seen as a grey translucent layer, and beneath it the dense white submucous tissue. The liver and other organs healthy.

The disease here seen appears to be of the same nature as simple scirrhous pylorus, where the morbid condition is due to the production of a dense fibre in the submucous tissue, and an hypertrophy of the muscular coat. If this is supposed to be extended throughout the whole organ, the appearance presented by this stomach may be well understood.

As regards the causes or true pathology of the disease, little can be said; as to whether it arises from long-continued irritation of the mucous membrane; whether the peritoneum, being first affected, induced the change in the other tissues; or whether we must be content to look upon the disease simply as one of fibroid change, arising from some unknown cause, and to be classed, with similar affections of other organs, such as cirrhosis of lung, excessive thickening of pleuræ, &c.

Several specimens of the kind, in Guy's Museum, are styled either scirrhous or colloid; but this is owing probably to there being formerly so few terms in use to designate varieties of disease; cancer being applied to the majority of new growths, either as fungoid when soft, or scirrhous when hard and fibrous; and in the same way, when the mucous membrane was swollen or gelatinous-looking, the term colloid was employed; there being also reason to believe that the muscular coat, when separated into distinct portions by the adventitious fibrous

Digitized by Google

tissue, was mistaken for loculi filled with colloid matter. In two cases in the Museum, the œsophagus was affected in a similar manner to the stomach.

The case is interesting in respect to the obscurity of the symptoms, there being no definite morbid state, excepting the dropsy.

It is also interesting in connection with the general subject of new growths and its association with true cancer, for with this fibrous development in the submucous tissue, we may sometimes meet with a cell-growth of cancer. Also between the simple fibrous material, as seen in this specimen and true cancer, all intermediate grades of growth may occur, such, for example, as is known by the name of recurrent fibroid, a specimen of which, as affecting the stomach, has already been brought before the Society.* Dr. SAMUEL WILKS, *21st of January*, 1862.

---

12. *Chronic ulcer of the pylorus, with induration of the pancreas.*

The patient from whom this stomach was taken was a wholesale butcher, æt. 33, in easy circumstances. As a young man he had lived very freely, but since his marriage, some years ago, he had been steady; though, from his wife's account, he enjoyed what is termed good living. He was first seen by me about a year ago, when he complained of severe pain across the epigastrium. This pain was so severe as at times to simulate that from passing a gall-stone. His bowels were rather torpid. He was relieved by repeated moderate doses of calomel and opium. After a short time, he was again seized with an intense pain of the same character, extending round the margin of the ribs on either side. He was relieved by similar means, and exhorted to live carefully, and especially not to eat fat, or partake of any hard food. It is remarkable that the pains above referred to generally occurred at night, after he had been for some time in bed.

On the 17th of October I saw him at his own house, in conjunction with Dr. Jeaffreson and Mr. Taynton. We carefully examined him in bed, and could discover no tumour in the abdomen.

After a time, the pains recurred much more frequently, and followed more closely upon taking food, and were attended with vomiting. The distress consequent upon taking nutriment into the stomach was so great, that it was determined to abstain altogether from giving food by the mouth, and to have recourse to injection of beef-tea. Under this plan he obtained great relief. He was in a short time allowed a little milk and lime-water, which caused no inconvenience. He, however,

* Trans. Path. Soc., Vol. X., p. 146.

Digitized by Google

soon took meat, against advice, and a recurrence of the pain and sickness took place, after which, he for a time adhered to the instructions given him. This recurred several times. A dose of Christmas-pudding brought on an alarming attack of pain and sickness, from which, however, he recovered in some degree, by adhering to the prescribed mode of living. It is to be observed that, in all these errors of diet, nothing disagreed with him so certainly as animal fat.

After going out one day, and dining heartily in the city, he was at night attacked with great pain, sickness, and melæna, under which he sank exhausted in about forty-eight hours. I was not present at the autopsy, but was informed that the liver was in an early stage of cirrhosis. There were no other morbid appearances observed beyond induration, or cirrhosis of the pancreas, and enlargement of the stomach, with a large chronic ulcer near the pylorus, which had doubtless been the source of hæmorrhage. Dr. BARLOW, *21st of January*, 1862.

---

13. *Six inches of the ileum passed per anum, three months before death; also the part of the intestines (perfectly cicatrized) whence this portion came.*

Mrs. M., æt. 41, was the subject of some tuberculous symptoms, which were of several months' duration, but were not in a very active condition,—indeed, not sufficiently so to induce her to seek medical treatment, and she was able to attend to her household duties. She had always been thin and delicate; and two of her sisters are suffering from chronic phthisis.

She had engaged Dr. Hearne to attend her in her confinement, which she expected to take place in November, 1860, but on the 28th of October he was suddenly summoned to see her. As he was not at home, she was seen by Mr. Giles and Dr. Welch, and found to be suffering from symptoms of severe peritonitis, which had set in very suddenly. There was extreme pain, with considerable tenderness, over the abdomen, but most marked over the right side of it, especially in the region of the cæcum. There had been no prolonged constipation. Half-a-drachm of liquor opii was given at once, followed by half-grain doses of calomel and opium every four hours, and warm cataplasms were applied. These measures gave relief, and labour coming on, on the 30th of October (the *third day* from the commencement of the abdominal symptoms) she was delivered, naturally, of a living child, her sixth, which survived about three weeks. She continued, after her labour, in a very prostrate condition, with considerable abdominal pain

Digitized by Google

and tenderness. The calomel and opium were persisted in, and fluid nourishment, with stimulants, was administered.

On the 4th of November (*eighth day*), tympanitic distention of the abdomen and diarrhœa had supervened, and the pulse was from 120 to 130, with but little power. The calomel was omitted, and a mixture containing ten grains of aromatic confection, with chloric æther and liquor opii, of each ten minims, after every liquid motion, was substituted; farinaceous food and brandy being given freely. On the *tenth day* the purging was arrested, but there was constant vomiting, attended by excessive prostration. Blister to epigastrium; hydrocyanic acid, with ammonia, as an effervescing draught, every three hours. *Eleventh day.*—Symptoms slightly relieved; still a large amount of abdominal pain. Besides the mixture, calomel and opium, of each half-a-grain, night and morning. On the *twelfth day* there was immense prostration, and incessant sickness and hiccough. Vaginal discharges very fœtid since confinement. Creosote in one minim doses, with magnesia, given frequently, and as much good liquid nourishment, with stimulants, as could be taken. *Fourteenth day.*—Sickness and hiccough less troublesome; but the prostration continued very great, and the expression of countenance as bad as it could be, "strongly reminding me," says Dr. Hearne, "of that of the last stage of cholera, with the pulse as rapid and feeble as possible." The bowels were again irritable, and some mass was passed which, on examination, was found to be several inches of the small intestine. Stimulants and fluid nourishment pushed; the small doses of calomel omitted; a mixture of opium, aromatic confection, and carbonate of ammonia, administered frequently.

On the 18th of November (*twenty-second day*) a gradual improvement had taken place; the irritability of the bowels had subsided; but there was still a considerable amount of tenderness over the right iliac region. Small doses of calomel and opium again administered twice a-day. On the *twenty-sixth day* she was improved, but the bowels were again slightly irritable, so that the astringent mixture was resumed; and two days later the tenderness of the abdomen had greatly subsided, when, the gums being slightly affected, the calomel was omitted. By the *thirty-fourth day* the abdominal symptoms were quiescent; but evidence of phthisis now became very marked. The pulmonary disease gradually increased, and, without further abdominal complication, proved fatal on the 6th of February, 1861, more than three months after the commencement of the abdominal attack, and nearly three months after the passing of the portion of intestine.

At no period of her illness, prior to passing the sphacelated portion of

Digitized by Google

intestine, were the bowels more than about forty-eight hours without acting. She did not on any occasion pass any blood per anum, nor was any tumour felt in the abdomen.

The *post-mortem* examination showed much tuberculous deposit in both lungs, and cavities in their upper lobes. It was found that the portion of intestine voided was from the lower part of the ileum, about fifteen inches from the cæcum. There was no evidence that the peritonitis had been general, nor was there proof of ulceration or disease in any other portion of the intestine than in the specimens exhibited to the Society.

These specimens consisted of (1.) the portion of intestine voided per anum; (2.) the part of the bowel whence the detached portion had been separated. (Plate III.)

(1.) The portion passed per anum was six and a-half inches in length, of a very dark purplish-grey colour, somewhat sloughy, the ends being uneven and ragged; it formed a perfect cylinder, but the intestine was turned inside out, the exterior of the specimen, as voided, being the mucous membrane, and the interior of the cylinder being the peritoneal covering of the intestine.

(2.) The specimen, however, of especial interest was the one showing the part of the intestinal tract whence the intus-suscepted portion had been separated—a part, as already stated, situated about fifteen inches from the cæcum. At this point the intestine presented several peculiarities of interest. (*a*) The line of union (where the separation had occurred) ran obliquely across the intestine, but the union was so perfect that it could scarcely be detected, except by holding up the intestine between the eye and the light, when the thinness of the intestine clearly pointed out the line (or "seam") where the union had taken place. On close examination, the mucous membrane was found to present a more shining and glazed appearance along this tract than elsewhere; the tract itself, though varying, had an average breadth of from one-sixteenth to one-eighth of an inch. (*b*) Exactly at the point of union, the intestine was notably narrower than elsewhere, and slightly narrower than natural; but the intestine above this part was a little dilated. (*c*) The most remarkable condition, however, was the following:—Close to the "seam" already mentioned, the intestine formed (near its mesenteric attachment) a pouch or sac of the size of a small nutmeg, the opening into it being well defined, and measuring one inch and a-quarter in diameter. Here, jutting out from the interior of the intestine, a very peculiar body was found; it consisted of a somewhat cylindrical mass, one end of which terminated in an oblique plane, so

Digitized by Google

Digitized by Google

DESCRIPTION OF PLATE III.

Illustrating the condition of the Ileum, in Dr. Hare's case of Intus-susception, after the intus-suscepted portion had been passed per anum (p. 88).

The portion of bowel represented was situated about fifteen inches from the cæcum.

From A to B extends an oblique linear cicatrix, due to the separation of the intus-suscepted portion of bowel.

C. A pouch, the size of a nutmeg, situated immediately below the cicatrix.

D. A peculiar body, perforated vertically by a canal, and united to the parietes of the bowel, probably the upper portion of the invaginated bowel, of which the greater part had been discharged per anum.

Digitized by Google

F. Hare del. Tuffen West lith.

W West imp

Digitized by Google

Digitized by Google

that one side of it measured three-quarters of an inch in length, while its other side was only half-an-inch long; it was fully three-quarters of an inch transversely; it was perforated vertically (*i.e.*, in the same direction as the axis of the intestine) by a canal, which admitted a large crowquill; and both the canal and the exterior of the small body were covered by mucous membrane. As already stated, this body jutted out into the interior of the intestine, one side only of it being attached; but the precise position which it occupied being the middle three-fifths of the opening into the pouch or sac previously mentioned, a space of about a-quarter of an inch around it was alone left as an available opening into the sac. (*d*) No ulceration of the mucous membrane, or disease of Peyer's patches, existed in the portion of the intestine exhibited (about ten inches). (*e*) Externally there was considerable puckering of the intestine at the part corresponding with the lesions described.

Remarks.—These very interesting and rare specimens were kindly sent to me, for exhibition to the Pathological Society, by my friend Dr. Hearne, of Southampton; and as the case presented, in a practical point of view, circumstances of very unusual importance, I have ventured to give more details as to the symptoms during life, and concerning the treatment adopted, than would be necessary for a strictly pathological consideration of the case.

Portions of intestine passed per anum are occasionally met with; but it is extremely rare to get not only the part of the intestine voided, but to have the opportunity of examining, several months after cure, the part of the intestinal tract from which the portion voided per anum had been separated.

While one of the specimens, which I had thus the advantage of showing to the Society, proved that more than six inches of intus-suscepted intestine had sloughed away, the other demonstrated how very perfect the cicatrization between the remaining portions of the intestine may be at the end of three months. Indeed, a little thinning of the intestine at the point of union, a barely perceptible altered condition of the mucous membrane, and a slight contraction of the diameter of the intestine, were all the *essential* changes indicating the part affected. But in the specimen exhibited there was another "abnormity," of great interest and extreme rarity, and of which the explanation appeared at first difficult. I allude to the mass perforated by a canal, which projected into the intestinal cavity, and which I have above described. A careful examination of the specimen seemed to prove that

Digitized by Google

this peculiarly-shaped body must have been produced by the intus-suscepted portion of the intestine having laterly formed a union, over a limited area, with the sheath of the invagination, this union being effected by means of effused lymph; the part of the invaginated bowel *below* the adherent portion had sloughed off, and had been passed per anum; while, again, the *upper end of the invaginated bowel*—the upper end, that is, of that portion of the invaginated bowel which had a union with the interior of the sheath—had become separated from the non-intus-suscepted part just where this was continuous with the sheath of the invagination. Thus a small section of the upper part of the invaginated bowel having formed a vascular connexion with the inside of the intestinal canal, and having become separated above and below from the rest of the intestine, continued to live as a small mass growing from the mucous membrane of the intestine. This would explain the fact of the mass being covered with mucous membrane, and that of its being perforated vertically by a canal—this canal having, indeed, been originally the cavity of the intestine, but which had become, in time, very much smaller, partly from the exudation-matter, which during the inflammatory period had been effused into the substance of the mass, having subsequently contracted, and partly from the canal having gradually narrowed, in accordance with the law that unused cavities or canals usually diminish in size. Thus was accounted for, the curious, and perhaps unique, phenomenon of a cylinder of intestine growing, as it were, within the intestinal canal. As, moreover, this mass acted as a foreign body and a source of obstruction to the progress downwards of the fæcal matter, exactly where there was also some obstruction, owing to the puckering of the intestine, the intestine seems, by the constant pressure of the fæcal matter, to have been forced into the pouch-like dilatation which, as already described, surrounded the little mass.

Dr. HARE for Dr. HEARNE, 18*th of February*, 1862.

---

14. *Colloid cancer of the omentum, pancreas, spleen, bladder, cæcum, sigmoid flexure of the colon and rectum.*

J. G., æt. 75, a widow, was admitted into the Royal Free Hospital, on the 27th of November, 1861, under the care of Dr. O'Connor. The House-Surgeon, by whom the patient was admitted, supposed her, from the very much enlarged condition of her abdomen, to be the subject of ascites. On examination the following day, she was found to be somewhat emaciated; pulse 74, and full; the tongue was clean and moist;

Digitized by Google

the gums were of a healthy colour, but she had lost all her teeth. As she lay in a recumbent posture, she was perfectly free from pain, complained of frequent sickness and heartburn, and a constant desire to evacuate the bowels, especially after eating, but could not pass anything. The bowels had not been relieved for ten days before her admission, and what escaped before that time was squirted from her. The whole of the abdomen was very much swollen, tympanitic, and painful on pressure; the veins in the parietes were very much enlarged, but there was no evidence of fluid in the cavity. Hard masses could be easily felt, through the parietes, in different parts of the abdominal cavity. In the right inguinal region a hard superficial mass, the size of the palm of the hand, could be felt; it was very painful to the touch, and appeared to be of some thickness. On examination of the chest, the organs in that cavity were healthy. The urine was constantly dribbling, and could not be retained. The account obtained of her previous history was, that until forty years of age, at which time she was married, her health was uninterruptedly good. Ten months after marriage she gave birth to a child. Her labour was very painful and protracted: she sustained some injury at that time, and has not been able to retain her urine since. Soon after she ceased to menstruate. She frequently suffered from abdominal pains, and an occasional discharge of blood from the abdomen until January, 1861, when she was seized with sickness, accompanied with discharge of blood from the bowels; this was followed by an attack of diarrhœa, and in a few days there was a copious escape of clots of blood. For two months the diarrhœa and escape of clots of blood alternated, when both ceased. The bowels then became constipated, and the abdomen swollen and painful. She stated that there were small tumours resembling piles round the anus. Latterly, and before her admission to the Hospital, there was occasionally a discharge, of a jelly-like appearance and reddish colour, from the bowels, whilst walking or in the erect posture. The patient's appetite was good, and she took food well whilst in the Hospital, besides wine, brandy, and stout.

The bowels not having been relieved since ten days before admission, purgative medicine was ordered without effect; a dose of calomel, followed by an enema was next prescribed; the calomel produced sickness, and the enema could not be passed into the bowels, owing, it was supposed, to some obstruction. On examination by the rectum, a hard dense mass, as large as a fœtal head, could be felt. It was immoveable, but not painful. Round the anus were cancer-like growths, from which there was a jelly-like exudation. On examination by the vagina,

Digitized by Google

there was found to exist a complete occlusion of that canal. After the patient was about a fortnight in the Hospital, the abdominal pains became severe, and as the bowels had not been relieved, it was sought to promote their action by the introduction of an O'Beirne's tube; but that instrument could not be passed without considerable force, and risk of doing some internal mischief. Croton-oil was rubbed into the abdomen. The pains, however, soon subsided for a few weeks, the patient all the while taking food and stimulus, and frequently saying that her appetite was never better.

She continued in this state, with but little variation, until the 13th of January of this year, when she complained of sickness and retching. The tongue was dry; the pulse became small and quick; there was great tenderness of the abdomen; it was especially painful in the right inguinal region. The patient gradually sank, became comatose, and died on the 19th of January, her bowels not having been relieved since the 17th of November, 1861, during the whole of which time she consumed as much food and drink as any strong and healthy person of her age.

The body was examined twenty-four hours after death. On opening the abdomen, a thick layer of healthy feculent matter completely covered the intestines, which, it was afterwards found, had escaped through a rent in the cæcum, near to which there was attached a large mass of colloid cancer. The intestines were removed, and on examination there were found, on the external surface of the ascending colon, nodules of colloid cancer of a plum colour, many of them as large as a full-sized walnut. The rectum was pressed on by a large mass of the same cancerous formation. The bladder was the size of a child's head, and completely filled with cancerous growth; it did not contain any urine. On the internal surface of the small intestines there were colloid growths, varying in size from that of a pin's-head to that of a Spanish nut. The omentum was a complete network of the same growths. The diaphragm was closely attached to nearly the whole of the upper surface of the liver, and between the two there were cancerous deposits deeply indenting the liver, but not entering into its structure, which was healthy. The kidneys were healthy, but the right was firmly attached to the under surface of the liver. The pancreas was an entire mass of cancerous degeneration; and on making an incision into the spleen, which was smaller than usual, it was found to be almost converted into a similar state. The thoracic organs, as well as the brain and uterus, were entirely free from disease. The whole of the diseased masses, which are unique specimens of colloid, are now before the Society.

Digitized by Google

Dr. Bristowe has favoured me with the following account of the microscopical appearances:—"I have examined several specimens of the diseased tissues, and especially the growths involving the spleen, and found them to present the usual microscopic characters of colloid cancer. They consist of irregular inter-communicating loculi of various sizes. The loculi are formed of a delicate, indistinctly striated membrane, studded here and there with minute oil-globules, and sending off in all directions curvilinear bands and processes. The spaces are occupied by the usual jelly-like material, which even in alcohol retains its transparency. This contains a little oily matter, and here and there imperfect indications of cells, but nothing definite or characteristic. The accompanying figure (Woodcut 7) shows the

WOODCUT 7.

Represents the microscopic appearances of the stroma, in Dr. O'Connor's case of colloid cancer of the abdomen.

arrangement, as seen by a fourth object-glass, of the membranous skeleton of the cancerous growth."

Dr. O'CONNOR, 18*th of February*, 1862.

---

15. *Perforation of the stomach from simple ulceration.*

The subject of the case was a maid-servant, æt. 18, who had enjoyed tolerable health, and had lived two years and a-half in her place. She had been chlorotic for some time, but had menstruated a short period before her death. She ate a hearty breakfast, and soon after this, when

Digitized by Google

in the street, she was seized with violent pain in the abdomen, was taken home in a cab, and Mr. Barnes, of Chelsea, with whom I attended the inspection, was called to her. Her pulse was feeble, her skin cold, and she had at first the usual symptoms of perforation, but of a less formidable character than usual. She had but slight tenderness over the abdomen, and twelve hours after the seizure she expressed herself much relieved. Her mistress visited her several times in the night, and she frequently got out of bed for water, of which she drank a large quantity. Her mistress on visiting her after a short absence found her dead, so that her death must have been sudden, about eighteen hours after the perforation.

The body was plump and very white, the abdominal muscles covered with fat, nearly an inch in thickness. The lungs and heart were healthy, but the latter organ was large, fat, and flabby. The pericardium contained a large quantity of serum. The abdominal and pelvic cavities were filled with a clear yellow fluid. On the anterior part of the stomach, about midway between the two orifices, was a small aperture, which would barely admit the point of the little finger. The opening was rather larger on the internal surface, but the edges were not thickened, and it had the appearance as if punched out. Not a trace of inflammation was seen on any part of the peritoneal surface, and the remaining viscera, with the exception of the uterus, were healthy. On opening the uterus, a tumour about the size of a small walnut was seen over the entrance of the left Fallopian tube, at first sight leading to the belief that the girl was pregnant; but on examination, the body was found to be a fibrous tumour made up chiefly of fibrous tissue, and of long, narrow, spindle-shaped cells.

The remarkable peculiarities in this case are the absence of inflammation, and the ability of the patient to get out of bed up to the time of her death. The large amount of water in the abdomen, occasioned by the fluid which she drank passing from the cardiac aperture into the peritoneal cavity, may account for this; and it is probable, I think, that the suddenness of her death arose from the pressure of the fluid on the pericardial and peritoneal sacs.

I believe, as I first mentioned at the Medical Society of London ("Lancet," 1837, p. 423), that simple ulceration of the stomach is more common in young unmarried females, especially when affected with uterine irregularity. In 1843, ("Lancet") I collected fifty-one British cases—thirty-nine females and twelve males. In 1852, ("London Medical Examiner," vol. ii., p. 285), the number of cases (British) was extended to ninety, seventy females and twenty males. Of the for-

Digitized by Google

mer, thirty-seven were betwen the ages of fourteen and twenty, and twenty-seven between twenty and thirty. Nearly all of them were unmarried, and had uterine irregularity.

Dr. CRISP, 18*th of February*, 1862.

---

16. *Stomach of a patient who died from the effects of bitter almond oil.*

The man, æt. 26, took an ounce of the poison, and almost instantly fell down in the street insensible. He died on his way to the police station, without manifesting the slightest convulsive action. The interior of the stomach is intensely inflamed, being of an almost uniform brownish-purple colour. The mucous membrane is somewhat softened and roughened, and even the external coat of the stomach is congested. Dr. Harley extracted from the stomach about six drachms of the poison, and from the nerve-substance of the brain he obtained, by distillation, prussic acid in considerable quantity. Dr. HARLEY, 4*th of March*, 1862.

---

17. *Artificial anus after the operation for strangulated femoral hernia.*

The patient, from whom the preparation was taken, was a female, æt. 84. She was first seen by me late in the evening of Sunday, February 16th, and was, at that time, suffering from stercoraceous vomiting, which was incessant, and which at once indicated strangulation or obstruction of the intestines.

On examination, a hard tumour was found, occupying the situation of the femoral ring. This tumour, the patient stated, had existed for a year or two, but she had never worn a truss. It had come down two days previously during a fit of coughing, and was very painful on pressure. Owing to the painful condition of the tumour, I did not deem it prudent to prolong the application of the taxis, and as she was unwilling to submit to the operation, a grain of opium every four hours during the night was prescribed.

On the following morning, after gentle taxis which was unsuccessful, with the concurrence and assistance of my friend Mr. Hainworth, I proceeded to operate. The operation was performed in the usual manner, and the stricture was divided outside the sac, which was deeply coloured. The hernia was returned without any difficulty. The opium was continued, with the twofold intention of somewhat arresting the peristaltic movements, and of allaying a very troublesome cough under which the patient laboured.

For some days she appeared to be progressing favourably, but I could

Digitized by Google

not convince her of the necessity for keeping in a recumbent position, and continually found that she sat up in bed to take food. On the fifth day the bowels acted naturally per anum, and the wound appeared healed in two-thirds of its extent. The pulse had never risen above 90, there was no peritoneal pain or tenderness on pressure, and the case appeared in every way advancing towards recovery.

On the eighth day from the operation, however, a slight oozing appeared at the upper and ununited portion of the external wound. This gradually increased, and in two days the whole of the fæces were voided through the opening. Notwithstanding the application of oil, &c., to the skin, intense excoriation and blistering, round about the wound, were occasioned to the extent of several inches. The pain of this excoriation gave rise to great constitutional disturbance, which alone appeared to gradually exhaust her strength, for she became weaker from day to day, and died on Sunday, three weeks after the operation, there having been no inflammatory symptom existing calculated to destroy life, as manifested by the *post-mortem* appearances.

Post-mortem examination.—Externally the body had the appearance of a well-nourished female in advanced life. The integuments of the left hypochondriac, the left half of the hypogastric and pelvic regions in back and front, of the pudenda, hips and nates, were discoloured and partially excoriated, from superficial inflammation. Over the right trochanter was a small bedsore. Immediately below Poupart's ligament, on the left side, was a wound made in the operation, healed in the lower, and open in the upper, half. A hollow beneath the open half admitted a small little-finger; it was lined with a tolerably dense vascular pseudo-membrane. At the upper part, the finger was stopped by what on inspection proved to be the angle of junction of two portions of intestine of which both extremities were open.

On opening the walls of the abdomen, the cavity and its contents presented a healthy appearance, and were free from effusion or adhesion. At the femoral ring two portions of intestine, consisting of the lower ileum—one above and in front of the other—adhered firmly to the entrance of the ring, and also to each other to the extent of about an inch; these were both of a dark colour, the upper one to the extent of three or four inches, the lower about one inch and a-half. By these adhesions the ring was hermetically sealed.

A free fold of intestine had also contracted adhesions by loose filaments to the ring, as well as to the two portions above described, behind and beneath which it passed. The left side of the bladder firmly and closely adhered over a space of two inches to the side of the adhering

Digitized by Google

intestine. Immediately above, and to the inner side of these portions of the bowel, was a thickened, but pale, and partially loose, fold of peritoneum, with dense cellular tissue and fat, which suggested the notion that it constituted the apex of the inverted hernial sac.

Dr. PART, *18th of March*, 1862.

18. *Stricture of the sigmoid flexure of the colon.*

The patient who was the subject of this disease was a female, æt. 43. She had long suffered from confinement of the bowels, and at Christmas last had an attack of intestinal obstruction which, however, yielded in a few hours to the employment of aperients. The illness of which she died was of a month's duration. She was first taken on the 6th of March with pain in the abdomen, sickness, and constipation; on the 10th, as no satisfactory relief had been obtained, she was seen by Mr. Hughes of Fenchurch Street. On the 12th, and again on the 18th and 20th, slight evacuations were procured; but, from the last date, no feculent matter passed from the bowels, except that on one or two occasions the fluids introduced as enemata returned with a slight fecal mixture.

When seen by Dr. Peacock on the 29th, she was suffering from severe pain in the abdomen, of a spasmodic character, and much aggravated at intervals; there was also considerable tenderness on pressure, and great distention and constant rumbling in the bowels; everything which she took was immediately vomited, and she was much prostrated. It was evident that no possible advantage could be gained by having recourse to the employment of purgatives, and the desirableness of operative interference was discussed and suggested, but declined by the patient's friends. It was, therefore, decided to exhibit full doses of opium at frequent intervals, so as to keep the patient under its influence, and to discontinue the administration of food by the mouth, and support her by enemata composed of strong beef-tea and wine. The first effect of this plan was to afford considerable relief to the patient's sufferings; the pain became much less, the vomiting was checked, she rallied considerably, and the improvement continued for several days. On the 5th of April, however, she was found much worse; there was more pain, increased tenderness on pressure, and distention of the abdomen; and the vomiting recurred. On the morning of the 7th, she became collapsed; and died the same evening, having had decidedly stercoraceous vomiting before death.

On examination, the small intestines, and the large intestines as far as the lower part of the sigmoid flexure, were found enormously dis-

Digitized by Google

tended, their coats so intensely injected as to be of a dark-red colour, and the cavity filled with semifluid fecal matter. The obstruction in the canal was situated at the lower part of the sigmoid flexure, near its junction with the rectum. It was apparently due to the contraction of the cicatrix of an old ulcer, and there was much thickening, puckering, and induration of the intestinal tunics in that situation, especially of the submucous coat; and the peritoneal coat was opaque, thickened, and adherent to the adjacent parts. There was no appearance of any carcinomatous deposit. Immediately above the stricture, the cavity of the intestine was very large, and an ulcerated aperture, of sufficient size to admit the passage of the thumb, existed in its anterior and inner side, by which fecal matter, to the extent of three or four pounds, had escaped into the cavity of the pelvis. The extravasated matter had not entered the general peritoneal cavity, apparently from the excessive distention of the intestines, but there was some bloody serum in the cavity, without, however, any lymph or solid exudation. The stricture was so tight as only to admit the point of the forefinger, and the intestine below it was greatly contracted.

At the commencement of the patient's illness, she passed a considerable quantity of urine, but at a later period the secretion became very scanty, and was deeply loaded with lithates. The injections employed were generally retained for several hours, but the quantity of fluid introduced was intentionally small, so that they could readily be received into and retained in the rectum.

Dr. Peacock, *15th of April*, 1862.

---

19. *Enormous distention of the belly from the effects of a severe and extensive burn.*

A married woman, aged about 28 years, was brought into the General Hospital, at Montreal, in the winter of 1846, in a state of collapse, the result of injuries by fire. The wooden tenement in which she resided took fire and was soon in a blaze; the fire spread so quickly that her clothes were burnt almost completely upon her body, her sufferings were extreme, and she was rescued before life was destroyed. She had had a quantity of water pumped upon her before she was discovered.

The parts of the body found chiefly burnt were the face and neck, the anterior part of the chest, and the entire abdomen. The extremities, the hands and arms particularly, more or less so. The abdomen was actually charred in some places, so that the skin was quite dry and

Digitized by Google

shrivelled; in others the linen was adherent in burnt fragments to the denuded skin; and in other parts again there were numerous and large vesications. Most of these conditions were present also on the chest, and both mammæ were swelled and denuded of epidermis in several places. The abdomen was enormously distended, and as she had somewhat rallied, it was so extremely tender and painful, that the slightest touch caused great agony. The enlargement resembled that of pregnancy, as shown in the drawing which I exhibited to the Society. The persons who brought the woman to the Hospital, stated that she was pregnant, the appearances of the breasts favoured that view, as they were not only full and prominent, but had a well-marked dark areola round each nipple. The patient was speechless up to the period of death, which took place between five and six hours after admission.

As there was the possibility of pregnancy, my friend Dr. Long and myself opened the abdomen *as soon as life had ceased*, this was done by the sanction of the Roman Catholic clergyman present. We found no gravid uterus, the organ was in its usual situation, and of natural size. The stomach and alimentary canal—the colon especially—were enormously distended with gas, and at once bulged forwards. Here was an explanation of the cause of the abdominal distention, the bowels were filled with gas generated by the heat, in one of two ways, either from expansion of the contained flatus by rarefication, or from the rapid generation of fresh gas, I certainly incline to the latter opinion.

The interest of the case lies in the abdominal distention by a severe and probably somewhat prolonged burn, in a person who, as we afterwards learnt, had a flat belly, although she was the mother of several children. Is this a rare effect of burns about the belly? and has it been noticed by any writer on these injuries?

I have consulted the writings of various surgeons who have written upon burns, and have not met with a single instance of abdominal distention as the result of burns or scalds; the foregoing case, therefore, appeared to be so rare and so remarkable, that it was worthy of being placed on record, as a pathological occurrence of considerable interest.

Dr. GIBB, *20th of May*, 1862.

---

20. *Intus-suscepted portion of intestine.*

The subject from whom this portion of intus-suscepted intestine, probably ileum, was obtained, was 41 years of age, a patient of Dr. Woodman, of Stoke Newington. Previous to the attack, this lady was in good health, and was suddenly seized with pain in the right hypo-

Digitized by Google

chondrium, and with sickness. This condition, attended by constipation only during the first three days of illness, and at a later period by jaundice, existed during eighteen days, when the piece of bowel shown (about one inch and a-half in length) came away, and the patient gradually recovered, and is now, after a lapse of five years, in perfect health.

The case is interesting, inasmuch, as the symptoms throughout its progress threw little light upon its true nature; the pain came on suddenly, and was always referred to the same seat; there was vomiting, but the bowels were relieved on the fourth day, and occasionally afterwards, attended by tenesmus; no blood was observed in the alvine evacuations. The accession of jaundice might have led to the suspicion of the presence of a gall-stone, and indeed, both lesions may have been present. One fact is evident, that, the intus-susception did not completely close the intestinal tube. Mr. MAUNDER, *20th of May*, 1862.

---

21. *Cast of femoral hernia.*

The cast exhibited illustrates the dimensions of a femoral hernia of the right side, which existed in a female, æt. 64, a patient of Mr. Comley, of Whitechapel. She had been the subject of hernia for thirty years. Five years since, Mr. Comley saw the case, when the protrusion was small and could not be returned into the abdomen. Since that time an illfitting truss has been worn, and the hernia has been slowly enlarging, till a few days ago it became strangulated, and measured seventeen inches by twelve. While considering whether or not she would submit to herniotomy, the patient got out of bed, and suddenly expired. Mr. Maunder cut down upon the hernia some hours after death to determine the point of its exit from the abdomen.

Mr. MAUNDER, *20th of May*, 1862.

II.—LIVER AND ITS APPENDAGES.

22. *Medullary cancer and cirrhosis of the liver. Death from hæmorrhage into the peritoneum.*

History.—Patrick S., æt. 50, became an out-patient at the Middlesex Hospital under Dr. Greenhow in August, 1861. At a former period of his life, he had been very intemperate, and he had been in the habit of drinking a large quantity of spirits. For some months he had been losing flesh, and he had been suffering from occasional nausea, and other dyspeptic symptoms, and from pains in the epigastrium. Dr.

Digitized by Google

Greenhow discovered that the liver was enlarged, and distinctly nodulated below the margin of the right ribs, and recognised the peculiar physiognomy characteristic of the cancerous cachexia. There was no jaundice, and little or no ascites; and nothing was observed to indicate an immediate fatal termination.

On August 26th, the patient was brought to the Hospital, and admitted under Dr. Goodfellow, his condition having become suddenly worse about two days before. His symptoms on admission were great prostration and cachectic countenance; marked jaundice of skin, conjunctivæ and urine; complete loss of appetite; urgent vomiting; intense pain and tenderness in the region of the liver; abdomen much distended and fluctuating; small, rapid pulse.

No improvement took place; and the day after admission, the patient vomited a large quantity of dark, bloody-looking fluid.

During the night of the 27th he fell into a state of collapse, which continued until death, at 2.30 P.M. of the 28th August.

Post-mortem appearances twenty-two hours and a-half after death.—Moderate emaciation; slight rigidity; abdomen greatly distended and fluctuating; marked jaundiced tint of conjunctivæ and skin, and of the tissues generally, including the internal organs and the bones.

Between five and six quarts of dark-red, bloody serum were found in the peritoneal cavity; and lying on the upper surface of the right lobe of the liver, towards its right extremity, between it and the diaphragm, was a dark coagulum of blood, which weighed five ounces avoirdupois. The serous coat of the intestines, which was bathed by the bloody fluid, presented no abnormal injection or deposit of lymph. The liver weighed seventy-two ounces. The right lobe was relatively much enlarged, measuring nine inches transversely, while the left lobe was much atrophied and a mere appendage to the right, not exceeding one inch and a-half in its transverse diameter. The greater part of the diminutive left lobe was granular on the surface, and presented on section the appearances characteristic of cirrhosis. Corresponding to the lobus quadratus, was a rounded mass, about the size of a large walnut, attached by a narrow pedicle, and likewise composed of cirrhotic, glandular tissue. The whole surface of the right lobe of the liver was covered with prominent nodules, varying in size from a pea to a large cherry, the largest being elastic, or presenting fluctuation. These nodules were most developed near the anterior margin of the right lobe, on the upper surface. The coagulum on the surface of the right lobe was adherent at one spot near the right extremity of the organ, which corresponded to one of the softened

Digitized by Google

nodules, which was ruptured. The structure of the right lobe of the liver was extremely dense; and on making a section, it appeared to consist of two abnormal elements, a groundwork of firm, grey scirrhus-looking tissue, infiltrated with a creamy yellowish juice, and containing a number of cavities up to the size of a cherry, filled with a soft, pulpy, bright yellow substance. The whole of the right lobe appeared to be made up of these abnormal elements, and scarcely presented, at any part, a trace of the natural glandular parenchyma. The scirrhous deposit had encroached to some extent along the anterior margin of the left lobe.

On examining, with the microscope, the juice scraped from the denser scirrhous portions, it was found to contain a multitude of rounded elliptical and fusiform cells, up to $\frac{1}{300}$ of an inch in diameter, with one, or sometimes two, large nuclei, about one-third the size of the cell; many of the cells likewise included brownish pigment granules. In the softened portions similar cells were discovered, mixed up with a large quantity of oily and pigmentary matter, both inside and outside the cells.

The spleen weighed six ounces. Its structure was firm, from hypertrophy of the trabecular framework; and it contained a laminated calcareous nodule, the size of a large pea, with an empty, central cavity (Degenerated *Cercaria* or *Pentastoma?*). The mucous membrane of the stomach presented a slaty-grey discoloration, but was free from ulceration or morbid deposit. The other abdominal organs were normal. The heart was normal. The apices of both lungs were condensed and puckered, and contained encysted calcareous masses, up to the size of a pea.

Remarks.—The above case illustrates a rare mode of fatal termination of cancer of the liver. After consulting various works on Pathological Anatomy, and on Diseases of the Liver, the only similar instance that I have met with is recorded by Frerichs (*Klinik der Leber-krankheiten*, Sydenham Soc. Transl., Vol. II., p. 333, and Atlas Plate IX., Fig. 1). In Frerichs' case, the hæmorrhage would appear to have commenced about three days before the fatal termination; the appearances presented by the liver were remarkably similar to those above described. Dr. Guéneau de Mussy tells me that he once dissected a similar case, and I am informed that another observation of the same nature was made by Dr. A. Fleming, of Birmingham.

Dr. MURCHISON, *15th of October*, 1861.

Digitized by Google

23. *Two specimens of rupture of the liver, &c.*

These specimens were obtained from the bodies of two boys, who were killed by the accident on the Kew and Hampstead Railway, on the evening of September 2nd, 1861. The bodies were examined forty-four hours after death, at the Middlesex Hospital. Death in both instances had been instantaneous.

1. A boy, aged 12. There was a fracture of both bones of the forearm, about two inches above the wrist; and there were numerous subcutaneous ecchymoses on the abdomen, and in different parts of the body, with a deep lacerated wound, extending from the mastoid process to the angle of the lower jaw, on the left side. There was no fracture of the cranium, and the brain and its membranes were normal.

The left pleura contained six ounces, and the right, one ounce, of fluid blood. The left lung weighed six ounces, was non-adherent, and presented an extensive ragged laceration of the upper lobe, three inches in length, and extending transversely almost through the entire thickness of the organ. The lower lobe was intact. The left ribs, from the second to the seventh inclusive, were fractured, about an inch from the junction of the cartilage with the bone. Over the upper three fractured ribs, the parietal pleura was torn, but without exposing the fractured ends. There was extensive subpleural ecchymosis corresponding to the fractures. The right lung weighed seven ounces; the upper lobe was torn almost completely across, a portion at the apex, the size of a small orange, being attached to the rest by little more than the pleura. None of the right ribs were broken.

The heart and great vessels contained perfectly fluid dark blood.

The peritoneum contained half-a-pint of dark fluid blood; there were no signs of peritonitis. The liver weighed twenty-seven ounces and a-half; its structure was normal. On the upper surface of the right lobe, near the posterior blunt margin, was a transverse ragged rupture, three inches and three-quarters long, and at some places one inch and a-half in depth. The rest of the organ was intact. The stomach contained upwards of a pound of undigested food. Its coats in the great cul-de-sac were attenuated, but not ruptured or discoloured. In the pyloric third, was a patch of submucous ecchymosis, the size of a crown-piece.

None of the other organs were injured.

2. A boy, æt. 8. There was a simple comminuted fracture of the right femur, and a simple fracture of the right tibia and fibula. There was extensive ecchymosis about the right knee, and a few small patches

Digitized by Google

of ecchymosis on the scalp; but there was no fracture of the cranium, and no injury of the brain or of its membranes.

Both pleural cavities contained about three ounces of dark fluid blood. There was no fracture of the ribs. Beneath the parietal pleura, on the left side, was an extensive patch of ecchymosis, over which the pleura was torn. There were likewise several patches of ecchymosis beneath the pleura, covering the lower lobes of both lungs. The pleura over some of these patches on the right side was torn, but the rupture did not extend into the substance of the lung.

The heart and great vessels contained a small quantity of dark fluid blood.

One pint of dark fluid blood was found in the peritoneum. On the upper surface of the right lobe of the liver near its back part, was an extensive rupture of a somewhat stellate form, with ragged edges, measuring transversely upwards of five inches, and extending, at some places, through the entire thickness of the organ, but much more extensive on the upper surface than on the under.

None of the other organs were injured.

Remarks.—These cases illustrate the ordinary situation of rupture of the liver consequent on external compression, the injury occurring, not at the part subjected to pressure, but at the most protected part of the convex surface, owing to the organ being, so to speak, forcibly doubled upon itself.

These cases also show that the lungs and pleuræ may be extensively lacerated, without any fracture of the ribs.

In both cases, and in another recorded at p. 70, where death was instantaneous, the blood in the heart and great vessels was perfectly fluid. John Hunter long since pointed out, that after sudden death from various causes, the blood does not coagulate. (*Hunter's Works, Palmer's Ed., Vol. III.*, p. 34).

Dr. Murchison, *5th of November*, 1861.

---

24. *Obstruction of the hepatic duct by hydatids. Purpura.*

The subject of this communication was a girl æt. 16. She was admitted into the Hospital on September 25th, 1861. She was deeply jaundiced upon the skin and conjunctivæ. The urine was coloured with bile, and the motions were pale. She had no pain, and did not appear depressed by her illness. The yellowness had come on four weeks previously; having been preceded for some weeks by itching of

Digitized by Google

the skin. The menses were regular. She was purged with blue pill and senna, and a mixture was ordered containing nitro-muriatic acid. Excepting that she occasionally complained of pains in the legs, she remained without much alteration until October the 4th. The pain then affected the neighbourhood of the right hip, and a surgeon was requested to examine the patient. He ordered six leeches to be applied to the groin, and periodical doses of calomel and opium to be given. During the night after the application of the leeches, the patient lost a large quantity of blood from the bites. The effects of the loss of blood were evident in her appearance. On the 6th the bleeding was still going on, and the patient now complained of pain in the knee. A morphia draught was given occasionally. Next day she was very low, and her manner had become querulous. As other measures had failed to arrest the hæmorrhage, the superficial veins in the groin were tied. The calomel and opium were now discontinued, and a mixture containing sesquichloride of iron and chloric ether was given at intervals. On the 8th there was still some oozing from the punctures, and some old ulcers on the legs had commenced discharging blood. The back became marked with purple spots, like bruises. Stimulants were freely given, but she continued to sink. Large blotches of purpura appeared on the arms, the bleeding continued, and she died on the 11th of October.

The body was examined thirty-two hours and a-half after death. There was a large patch on each buttock, which had the purple colour of an ecchymosis, and there were many similar spots on the legs and arms. With these exceptions the body was of a bright yellow colour. It was plump and well nourished.

When one of the patches on the back was cut open, it was seen that blood had been effused in the areolar tissue, beneath the discoloured skin, and occupied the spaces between the lobules of fat. The hæmorrhage was here superficial.

The hip-joints were both natural, but a large clot of blood lay between the right iliacus muscle and the plate of the ilium, for which no definite origin could be discovered. There was a similar clot in the pelvis, immediately to the left of the bladder, in the sub-peritoneal areolar tissue.

Each of the pleural cavities contained a small quantity of bloody fluid, and each lung contained a few circumscribed patches of extravasated blood. The heart was rather flabby, but in other respects was healthy.

The liver was soft, and of a deep olive tint. Under the microscope

Digitized by Google

the cells appeared deeply coloured with bile, small, and granular. The gall-bladder contained a small quantity of green bile. It was healthy in itself, but did not occupy its usual position. It was placed in the fissure between the right and left lobes of the liver. Immediately to its right, lying on the surface of the liver, was a round tumour, about as large as a tennis-ball, by which it had been thrust out of its place. This was a cyst full of hydatids, most of which had the size and appearance of white currants. They were quite loose in the cavity. The cyst proved to be a dilatation of the right hepatic duct. The wall was thick and rigid. It was lined with an elastic membrane, deeply tinged with bile, which, under the microscope, showed the laminated structure characteristic of hydatid cysts. This lining, however, was not entire, for a long ragged piece of it had passed into the common hepatic duct, and, aided by inspissated bile, had formed an impervious plug by which the duct was obviously distended. This reached into the common duct. The cystic duct was open. The dilatation which contained the hydatids had a somewhat wrinkled exterior, as if it had once been larger.

The kidneys were of a bright yellow colour, and were dotted with minute spots of hæmorrhage throughout their cortical structure. On microscopic examination the blood was found lying in small masses between the tubes.

The mucous lining of the bladder was stained of a deep yellow colour.

Commentary.—This case is one of very infrequent occurrence. It was evident that the mother-cyst was contained in the right hepatic duct, where it had probably originated. The outer cyst subsequently ruptured, and was gradually passing with the bile into the duodenum, when the natural process of cure was cut short by the indirect consequences of the obstruction.

It may be supposed that the absorption of bile into the blood occasions some deterioration of the globules which favours transudation into the tissues. Hence the frequency with which purpura accompanies jaundice.

The clot of blood under the iliacus muscle had so closely imitated disease of the hip as to deceive a skilful and experienced surgeon. The local depletion which was resorted to, under the belief that the joint was inflamed, seemed to have contributed to the fatal result.

The altered state of the liver, much as it resembled yellow atrophy, was probably merely a consequence of the retention of its secretions.

Dr. DICKINSON, *5th of November* 1861.

Digitized by Google

25. *Cases of acute atrophy of the liver.*

This disease, one of the most remarkable and formidable to which the human body is obnoxious, was first described in this country by Bright and Graves, but has received of late fresh light from the investigations of Frerichs. Beginning apparently as a simple jaundice, it soon becomes accompanied by the most violent constitutional disturbance, high febrile excitement, nervous derangement, delirium, sometimes hæmorrhages from various parts, and finally coma. After death the liver is found to have undergone a most remarkable atrophy, being shrunken to half or a third of its natural size, and presenting, when cut, a peculiar red and yellow mottling. The microscope shows that a complete destruction of the secreting structure has taken place, and that sometimes not a single cell has been left entire. It has also been lately shown by Frerichs, that not only does an atrophy occur, but a chemical decomposition takes place in the liver, whereby new proximate principles are formed, which are carried into the blood, and thus to the various organs of the body, where they may be discovered; that they especially go to the kidney, whose duty it would be to eliminate them, and passing out by the urine, may there be detected by the microscope, and thus afford some aid in the diagnosis.

It will be seen that the second and third cases occurred before Frerichs' investigations were made known, and thus no analysis was made of the urine, although the kidneys were found gorged with new products; in the first case, however, advantage was taken of these discoveries, and the crystalline bodies were found as stated in the above-named author's work.

Case I.—E. K., æt. 17, a married woman, was a patient of Mr. Bisshopp's, of South Lambeth. She was taken ill on October 30th, 1861, with a bilious attack and jaundice. On the next day she was worse, and on the following day, November 1st, the medical man was sent for. He found her very ill, suffering from jaundice, accompanied by some febrile symptoms and vomiting; on the following day she was much the same; but on November 3rd she became delirious, had violent screamings and convulsive fits; soon afterwards she became quite unconscious. She thus continued until the following day, when I visited her. She was then quite insensible, with slight stertorous breathing, and foam on the lips, the teeth clenched, eyes closed, pupils of moderate size, and excited by light. There was no spasm nor rigidity of limbs; pulse 120. These symptoms resembled those arising from

Digitized by Google

uræmic intoxication, and no doubt were due to this; but taking the case as a whole, there could be little doubt as to the nature of the disease from which she was suffering. On percussion over the liver, the diminished volume of the organ was very evident, there being only a very narrow band of dulness over the lower ribs. No urine had been passed for twenty-four hours, and therefore a catheter was introduced, when twelve ounces of clear bilious fluid were drawn off. On making inquiry about her personal history, it appeared that she had been married very young; and that lately, her husband had been from home, and had, on his return, charged her with infidelity. A quarrel had thus ensued. She had missed three menstrual periods. During the night a large quantity of blood was passed by the vagina; this was not seen, but from the appearances presented by the uterus after death there could be no doubt that abortion had taken place. On the following morning, November 5th, she died. The whole duration of the disease had thus been only six days, and the more urgent symptoms only two days.

Mr. Bisshopp with great difficulty obtained permission to make an opening in the abdomen two days after death. The body was then undergoing decomposition; it was plump and well-nourished, as of a person dying in the vigour of life; deeply stained yellow. There was a little bloody serum in the abdomen, and ecchymoses were observed on the viscera. There was no facility for weighing the liver, but Mr. Bisshopp was quite sure that it did not exceed one pound and a-half. The gall-bladder was contracted, and contained only a little mucus. The urinary bladder was contracted. The hand passed into the chest found the lungs crepitant and apparently healthy. The uterus, a kidney, and a portion of the liver were removed for my inspection. The uterus had evidently just thrown off an ovum. The kidney was large and coarse. The liver appeared at first of a uniform dark colour from saturation with blood, but after being placed in water, a distinct yellow mottling was seen as in other cases. The urine which had been drawn off had a sp. gr. 1030, and was of a dark bilious colour. The sediment contained casts of renal tubules and quantities of epithelium and pigmentary matter. On placing some of the fluid in a capsule to evaporate for a few hours, the crystals described by Frerichs were discovered. A film which had formed on the surface, when placed beneath the microscope was found to contain numbers of round masses, consisting of crystals of *leucine*, whilst at the bottom of the capsule were the needle-shaped crystals known as *tyrosine*. Portions of liver were submitted to the

Digitized by Google

microscope, and the secreting structure was found to be wholly destroyed; not an entire cell could be found, nothing indeed, but a quantity of debris of hepatic tissue and fat—the latter being very abundant and apparently in larger quantities around the lobules, or at least it was not uniformly distributed, but coursing much in the same way as the fat in a nutmeg liver. Amongst this were seen crystals of tyrosine and leucine as in the urine. There was not enough of the liver to prove, as Frerichs has stated, that these substances are to be found only in the hepatic vein, and not in the portal vein or hepatic artery. The kidney, when a thin section was made, was found to have its tubules completely gorged or blocked, so that by the microscope they were quite opaque as if filled with injection. These contents were composed of loosened epithelium, granular matter, pigment, and the crystalline substances above-named. The ends of the cones were seen to be of a white colour from deposit; this was very rich in these substances. The Malpighian bodies were unaffected. There was no opportunity of examining other organs in order to ascertain if these crystalline bodies had been carried elsewhere. There could be little doubt from the condition of the kidney, that the urgent symptoms towards the close of the case were due to its suppressed function.

Dr. Harley was good enough to analyze a bottle of the urine brought to the Society, and his account of it is as follows:—

Analysis of the urine.

Sp. gr. . . 1028		Reaction acid?
		In 1000 parts.
Water		948·860
Solids	Organic	44·950
	Inorganic	6·188
Urea		30·000
Uric acid		0·375
Resin Bile colouring-matter and acids Urohæmatin Leucine and mucus		14·575

"The urine was of a yellow-ochre colour, had a considerable deposit of organic, with a small quantity of inorganic, matter, contained both the bile colouring-matter and bilary acids, as well as a quantity of fatty and resinous matter. On evaporation, it yielded crystals of leucine but no tyrosine."*

* On a further examination, tyrosine was found.

Digitized by Google

Case. II.—E. L., æt. 23, admitted into Guy's Hospital, under Dr. Wilks, on the 29th of June, 1859, and died on the 7th of July. There was much obscurity about her personal history, but evidently some distressing circumstances had preyed upon her mind. It was said by her friends, that she had only been married some months, and differences already existed between her and her husband; it was stated also, by others, that she was a woman of dissolute habits. She had never been pregnant. On admission, she was so feeble that she was obliged to keep her bed. She was universally jaundiced; she had slight febrile disturbance, and had vomiting. Being so ill, the question of acute atrophy of the liver was discussed, but dismissed, owing to the absence of those violent symptoms which usually accompany this disease. She was ordered taraxacum and nitric acid. She continued in the same state for four days, when she became excessively prostrate, eating nothing, and vomiting continually. She then became delirious, and thus remained until she died, eight days after admission.

The *post-mortem* examination showed ecchymosis of the lungs, heart, and other organs; also a *post-mortem* perforation of the stomach. The liver was very small, lying contracted against the diaphragm; it was soft, and had a shrivelled look. When incised, it presented two colours, red and yellow intermingled; the latter constituted the greater part of the surface. On examination by the microscope, the secreting structure was found completely destroyed; instead of cells, dark masses of biliary pigment, hæmatine, and fat-granules constituted the lobules; scarcely a healthy cell being discernible. The weight was only one pound three ounces (the specimen was exhibited to the Society). The gall-bladder was empty. The kidneys, unfortunately, were not submitted to microscopic examination. Uterus empty; adhesion of Fallopian tubes to ovary.

Case III.—E. B., æt. 30, was admitted into Guy's Hospital, under Dr. Barlow, on the 12th of July, 1859, and died on the 14th of July. She was admitted in the last stage of the disease, and little history could be obtained. She was a domestic servant, and was said to have been jaundiced for four or five weeks; but it was only at last, when the more severe symptoms came on, that she was admitted to the Hospital. She was then universally jaundiced, in a comatose state; she had vomiting, and had passed no urine. She died on the following day. On *post-mortem* examination, purpuric spots were found on the organs. The liver was small and flabby, weighing one pound nine ounces, its surface, as well as the interior, presenting a red and yellow

Digitized by Google

mottling. Although flabby, it was as tough as the healthy organ. On section, the red parts presented a fleshy appearance, and had a homogeneous surface, whilst the yellow showed the form of the lobules distinctly, as seen in cases of obstruction of the hepatic ducts. On microscopic examination, the tissue was found quite disintegrated, very few secreting cells being visible, and these small, ill-shaped, and full of granular matter. The bulk of the tissue was composed of hepatic debris, masses of bile-pigment, hæmatine, and broken-up cells. The redder portions appeared more destroyed than the yellow, showing little more than a quantity of granules, with fat-globules, whilst the yellow showed remains of the secreting cells containing bile. The spleen was rather larger than natural; the kidneys were large, flabby, and of a dark colour; the tubules were full of dark granular and biliary matter, the epithelium being in many places quite gone. The urine in the bladder was scanty, bilious, fetid, containing epithelium from urinary passages, and casts of the tubules, principally composed of dark yellow pigmentary matter. Uterus empty, excepting containing a small polypus.

As regards the immediate cause of this remarkable disease nothing is known; but those influences which predispose to its production were present in the cases just narrated. In the first case, the two causes found most prevalent were both present—nervous depression and pregnancy. The former is too well known in its effects on the liver, in the production of jaundice, &c., to need any comment; and as regards the latter, it is exceedingly interesting, in connection with an acute affection of another organ, which sometimes occurs during pregnancy. I refer to the albuminuria accompanying puerperal convulsions. Not only in this condition is the urine albuminous, but it contains inflammatory casts, and the kidney itself, by minute examination, is in no other condition than one which must be styled nephritis. These two acute affections of the kidney and liver may perhaps have something in common, and both be referred to some condition of the blood peculiar to pregnant women. Dr. Samuel Wilks, *19th of November*, 1861.

---

26. *Hydatid of the liver bursting into the right pleura.*

History.—L. R., æt. 17, was admitted into the Middlesex Hospital, under Dr. Thompson, on the 23rd of March, 1861. She was a servant-girl, and, until a fortnight before, had continued at work, enjoying good health, and not suffering from any pain or uneasiness. At this time, she was suddenly seized with severe pain in the upper part of the

Digitized by Google

abdomen and both sides of the chest, which was increased by inspiration, and was accompanied by cough, dyspnœa, and febrile symptoms. On admission, pulse 112, small and weak. Dulness and absence of breathing over whole of right side of chest, except under clavicle. There was likewise dulness, with feeble breathing, over the left lung. The hepatic dulness extended three or four inches below the margin of the ribs, in the right mammary line. There was no jaundice and no ascites. Hectic fever, with great prostration, set in, and death occurred on the 8th of April, one month after the first symptom of illness.

Post-mortem examination.—The heart was normal; the left lung was firmly and universally adherent; the lower lobe was hyperæmic, and near the base the pulmonary tissue sank in water, but it was not granular on section, and it was unusually tenacious. The right pleural cavity was filled with pus, floating in which were innumerable hydatid vesicles, from the size of a pin's-head to a man's fist. The right lung was completely collapsed and carnified, except at the apex, which contained a little air. The liver was much depressed, its lower margin reaching to more than halfway between the umbilicus and the pubis. Projecting from the posterior margin of the right lobe, was a cyst, as large as a child's head, which was firmly connected to the diaphragm; the liver was not adherent at any other part of its surface. At the upper part of the cyst, there was a rupture through the diaphragm, measuring one inch and a-half in diameter, by which the interior of the cyst communicated with the right pleura. The walls of the cyst presented the usual appearances of those of an hydatid; its interior was filled with pus and vesicles. A large number of the vesicles were examined, but not a single echinococcus or hooklet could be discovered. There was no other hydatid, either in the liver or in any organ of the body. The pelvis, calices, and upper part of the right ureter, were dilated, apparently owing to the pressure below of the displaced liver; the secreting tissue was atrophied; the left kidney was normal.

Remarks.—The complete absence of symptoms prior to the occurrence of perforation is worthy of notice. Perforation of an hydatid of the liver into the right pleura is not uncommon. It occurred in twelve out of one hundred and eighty-nine cases collected by Davaine and Frerichs (see "*Frerichs' Diseases of Liver*," Syd. Soc. Transl., Vol. II., p. 235). Hydatids of the liver may likewise burst in various other directions, as into the bronchi, pericardium, stomach and intestines, peritoneum, or externally. Of the one hundred and eighty-nine cases alluded to, eighty-one had burst, and only one hundred and eight were

Digitized by Google

found after death confined to the liver. Moreover, in most of the cases which after death are found confined to the liver, the hydatids are so small as not to be capable of diagnosis during life. According to Frerichs, although a spontaneous cure of hydatids of the liver is always possible, yet in most cases where the cyst attains to such a size as to be capable of diagnosis, it goes on increasing, if let alone, and puts an end to life in from one to four years. Death, in fact, is a tolerably certain result. Accordingly, Frerichs advocates operative interference in every case where the cyst raises the thoracic or abdominal wall, and as soon as it can be reached with certainty and safety. When perforation has occurred, the case is too often hopeless. In the above instance, notwithstanding the large size of the cyst, a diagnosis before the occurrence of perforation was prevented by the complete absence of symptoms and the deep-seated situation of the tumour.

Dr. MURCHISON, *3rd of December*, 1861.

---

27. *Syphilitic deposits in the liver of an infant.*

A dead infant, seven weeks old, was brought to the Charing Cross Hospital at seven A.M. by its mother. The body was still warm.

The mother stated, that on waking she found her child dead by her side. No marks of violence were visible on the surface; nor did outward appearance indicate that death had been caused by asphyxia.

The mother was less than eighteen years of age, and, for the last two years, had been living an impure life. She stated that she had never suffered from syphilitic disease. A rash, which was noticed on the body of the infant, is said to have first made its appearance ten days before death; and, previous to this time, the baby was considered to be perfectly healthy. Since the eruption, however, it has been constantly ailing, and, as it were, pining away. At two A.M., the mother retired to bed, when the child was sleeping quietly by her side. As above stated, she awoke at seven o'clock and found it dead. It had not appeared to be worse on the preceding day, nor had its general condition created any alarm.

The eruption, already alluded to, was well-marked, as round, copper-coloured spots of syphilitic lepra, occupying the forehead and sides of the face; spots, here and there, were scaly. The characteristic wrinkling about the mouth was present; and there was true desquamation on the soles of the feet. Excoriation of the genitals existed.

On *post-mortem* examination the body was found to be generally emaciated; and no especial disease of any internal organ was seen, except of

Digitized by Google

the liver, which presented the normal colour and size, but was studded throughout with tubera uncapsuled, and varying in dimensions; the largest not measuring more than a garden-pea, and the smallest of the size of a pin's-head. (Plate IV.) Their colour was light fawn; and their consistence rather softer than putty. No cicatrices existed on the surface of the liver. There was, everywhere, an absence of scrofulous deposit. Mr. CANTON, *3rd of December*, 1861.

28. *Case of waxy or amyloid disease of the liver and spleen and fatty kidneys, with observations on waxy degeneration.*

History.—W. L., was for twenty-six months, from November 30th, 1858, to January 27th, 1861, a patient in the Middlesex Hospital under Mr. Shaw, suffering from caries of the left hip-joint, which had commenced about nine months before admission.

At the date of his death, on the 27th of January, he was nine years of age.

Post-mortem examination.—The body was extremely emaciated, the joints being large in proportion to the limbs. The total weight of the body was only thirty-one pounds three ounces, or four hundred and ninety-nine ounces avoird.; the length of the body was three feet and a-half. The abdomen was remarkably tumid and hard, more particularly in the right hypochondrium. There was much swelling about the left hip-joint, with numerous sinuses passing into the bone. The left thigh was flexed forwards and immoveable. The entire head of the left femur was absent, and the end of the bone was carious. The acetabulum was likewise diseased, the bone being exposed and carious, and at one part deficient, so that there was an opening into the pelvic cavity.

The child's head was remarkably large in proportion to the body, its circumference being twenty-one inches and a-half. The brain was very large, weighing fifty-five ounces and a-half; its structure was normal. Each of the lateral ventricles contained three drachms of serum, and at the base were two fluid ounces. The membranes were normal; the sinuses were full of dark coagulum.

The lungs presented no trace of tubercle, and, as well as the heart, were normal.

The liver was enormously enlarged, and very dense. Its weight was sixty-nine ounces avoirdupois, or nearly one-seventh of the weight of the whole body, the normal ratio for a child nine years of age being only about one to twenty-four. It reached as far as the umbilicus,

Digitized by Google

Digitized by Google

DESCRIPTION OF PLATE IV.

Fig. 1. (*a*, *b*) illustrate Mr. Canton's case of Syphilitic Deposits in the Liver of a Child (p. 114).

Fig. 2. Illustrates Dr. Wilks's specimen of Deposits in the Liver, following the course of Glisson's Capsule; from a case of Anæmic Lymphatica (p. 229).

Digitized by Google

Fig. 1a

Fig. 1b

Fig. 2

Digitized by Google

Digitized by Google

and moulded itself over the different organs. Its tissue was very firm, so that the organ retained its form when laid with its convex surface on the table. Its external surface was perfectly smooth, and exhibited impressions of the adjacent organs. Its cut surface was of a greyish-pink colour, and translucent, and presented a network of opaque yellowish streaks, apparently corresponding to the outline of the enlarged lobules, and enclosing the firm translucent material in its meshes. A tolerably distinct bluish tint was developed, on the addition of solution of iodine, followed by dilute sulphuric acid. On microscopic examination, the hepatic cells appeared to be coherent, and could not be isolated. The nuclei were distinct, but the outlines of the cell-walls were scarcely appreciable at many places, the nuclei appearing embedded in a translucent homogeneous mass. At some places even the nuclei could not be distinguished. Towards the circumference of the lobules, the cells were more distinct, and at some places contained a good deal of oil.

The spleen weighed eleven ounces and three-quarters, and presented a dense glistening surface on section, with a faint amyloid reaction.

The kidneys were large, the right weighing five ounces, and the left five ounces and a-quarter. They were not at all dense, but on the contrary, very flabby. Their capsules were non-adherent, and their surfaces were perfectly smooth and pale-yellow, with a beautiful network of injected veins. The cortical substance was hypertrophied, pale-yellow, opaque and soft. The renal epithelium throughout the kidneys was loaded with fine molecules and oil-globules, and at many places the uriniferous tubes appeared blocked up with oil.

The mesenteric glands were slightly enlarged. The peritoneum, stomach, intestines, pancreas, and supra-renal capsules were healthy.

Remarks.—Different statements have been made as to the mode of deposit of the morbid material in waxy liver, some observers stating that it is deposited *between* the secreting cells, which become atrophied and destroyed from the pressure exerted upon them; while others, as Virchow and Frerichs, believe that it is deposited *in the interior* of the cells, instead of the natural contents, the cell-walls of adjacent cells coalescing, and the nuclei ultimately disappearing, till at last the place of the cells is occupied by a homogeneous structureless material. My own observations confirm the view that the deposit takes place first in the interior of the cells. The deposit likewise takes place in the coats of the minute vessels, more especially in the branches of the hepatic artery.

Digitized by Google

Still greater difference of opinion has existed respecting the chemical nature of the morbid material. Meckel believed that it was of a fatty nature, and closely allied to cholesterine, but against this view it has been urged that the so-called amyloid reaction is developed after the affected organ has been boiled in ether. In consequence of the blue colour developed on the addition of iodine and sulphuric acid, Virchow and others believe the substance to be closely allied to vegetable cellulose, and hence the designation "amyloid." It is to be feared, however, that this view has been too readily accepted. The researches of Friedrich, Kekulé and Schmidt have shown that the substance contains a large proportion of nitrogen,—a discovery, which, if true, at once removes it from the vegetable carbo-hydrogens. Moreover, I have frequently failed to discover any "amyloid reaction," in cases of undoubted waxy degeneration, and this has been the experience of many other observers, more especially in Edinburgh. (See "British Med. Journ.," Feb. 16th, 1861, p. 181). There seems far more reason to believe, with Dr. W. T. Gairdner, of Edinburgh, and Professor Frerichs, that the substance is a modification of one of the albuminous compounds.

The relation between the fatty and waxy degeneration is of considerable interest. It is well known that after death from pulmonary tubercle, the liver is found sometimes fatty, and sometimes waxy. Again, in the case above detailed, and likewise in another body that I have dissected, the liver and spleen were waxy, but the kidneys were fatty. In two other cases, I have found the kidneys waxy, and the liver fatty; while, in a fifth case, the spleen was waxy, and the liver fatty. Lastly, I have met with two instances in which the liver presented an advanced stage of both fatty and waxy degeneration. At some parts, the fatty degeneration predominated, and at some, the waxy; while, at others, the two forms were intermixed. In both cases, it was distinctly observed that the parts affected with fatty degeneration were those in the vicinity of the branches of the portal vein, and at the circumference of the lobules, whereas the waxy parts were arranged round the hepatic veins, and occupied the centre of the lobules. Simple waxy degeneration, it may be mentioned, almost always commences at the centre of the lobules; fatty degeneration at their circumference.

As to the frequency of waxy disease, I may mention that I have met with it in twenty-three out of two hundred and sixty-five *post-mortem* examinations at the Middlesex Hospital, making a proportion of one to eleven and a-half.

Digitized by Google

Although waxy degeneration has now been found in almost every organ of the body, the organs most frequently affected are the kidneys, liver, and spleen. The following Table shows the comparative frequency with which the different organs have been affected in the cases that have come under my notice:—

Kidneys	16	Liver fatty ..... 2 Liver waxy ..... 3 Spleen waxy 2
Liver	7	Kidneys fatty ... 2 Kidneys waxy .... 3 Spleen waxy 5
Spleen	7	Liver fatty ..... 1 Kidneys fatty .... 2 Kidneys waxy .... 2 Liver waxy 5
Brain	1	
	31	
Subtract cases where more than one organ was affected	8	
	23	

Age does not appear to exercise much influence over the occurrence of waxy degeneration. The youngest of my patients was six, and the oldest fifty-eight years of age.

The disease, however, appears to be far more common in the male than in the female. Of the twenty-three cases, 17 were males and 6 females. Of the total number of bodies examined, 146 were males, and 119 females, so that of the males 1 in $8\frac{13}{17}$ had waxy degeneration of some organ, and of the females, only 1 in $19\frac{5}{6}$. Of sixty-eight cases of waxy liver, collected by Frerichs, 53 occurred in the male, and only 15 in the female sex, although, as he observes, the conditions which predispose to waxy disease are as common in the female as in the male.

Waxy degeneration usually makes its appearance in persons whose nutrition has been seriously impaired by other diseases. According to Frerichs, the pathological processes which most commonly predispose to it are diseases of the bones, constitutional syphilis, the cachexia of intermittent fever, and tubercle of the lungs and intestines, &c. He likewise publishes a case where waxy disease of the liver and spleen supervened upon cancer of the uterus and stomach. The following Table shows the circumstances under which the disease was developed in my twenty-three cases:—

Digitized by Google

There was recent tubercle of the lungs, &c., in	14
Caries of the bones	4
Cancer of cranium, 1—of mediastinum, 2	3
Syphilitic disease of liver, 2—and dura mater, 1	2
Valvular disease of the heart	2
Pyæmia	1
	26
In 3 cases, caries and tubercle were combined	3
	23

I am unable to state how many of the patients suffered during life from constitutional syphilis.

Frerichs states that in the great majority of cases where the liver is found diseased, after death from tubercle, the disease is fatty and not waxy, and this statement is probably correct. Of fifty-two cases of persons dying from tubercle, I have found the liver fatty in 20, and waxy only in 6, and three of the six had likewise caries of the bones. Still of the fifty-two cases of tubercle, 14 had waxy disease of either the kidneys, liver, or spleen, or 1 in 3½. The proportion of tubercular males in whom waxy disease was found, was more than double that of females. Thus of 33 tubercular males, there was waxy disease in 11, or 1 in 3; whereas of 19 tubercular females, only 3, or 1 in 6⅓, had waxy disease.

Dr. MURCHISON, *17th of December*, 1861.

29. *Complete obstruction to the bile and pancreatic ducts.*

The case was one of great obscurity. The patient, a gentleman, æt. 50, had, up to fourteen or sixteen months before his death, been very healthy. He then became yellow, and this yellowness increased to actual jaundice. At the early part of this illness the gall-bladder was not only to be felt, but was actually visible under the false ribs. After an attack of purging of what was called bile, this swelling suddenly disappeared, and was never again visible. There was no tumour; but at this stage of the disease an eminent physician believed it to be organic disease of the pancreas or liver. The stools were clay-coloured; and except this and the jaundice there were no symptoms of biliary calculus. Dr. Harley saw him first in October last. The patient was then passing fatty matter by stool, which fatty matter was at first supposed to be from the bile; but, on examination, it turned out to be a fish-oil—cod-liver oil modified, nothing being left but margaric and stearic acids. It was then supposed that there was a stoppage of the

Digitized by Google

pancreatic duct. In the urine were found the biliary acids as well as the colouring-matter of the bile, and the diagnosis accordingly was obstruction both of the pancreatic and the bile-ducts. Fourteen days later there was tenderness over the region of the liver. The urine was several times examined, and, on one occasion, was found to contain tyrosine and leucine. As Frerichs stated that these substances are found in cases of contracted liver, Dr. Harley requested Mr. Prance to examine his patient again, and the report being that the liver was getting smaller, they saw the patient together, and made a careful examination of the organ. Another point of interest in the case was that the urine, which was constantly examined, was free from albumen. The uric acid was in small quantity only, which favoured the idea of there being no malignant disease of the liver. There were passed in the day twenty-seven grammes of urea, which showed that the digestion was good; but gradually the urea diminished, and at length only fifteen grammes were found in it. Three weeks before death sugar appeared in the urine, and this was looked upon as a bad omen, as Dr. Harley had, in other cases of chronic disease, found sugar in the urine a little time before death. After death the urine was found highly saccharine. At the *post-mortem* examination it was ascertained that the gall-bladder was much enlarged, and was filled with tarry, viscid bile. The cystic duct was much dilated, and the common bile-duct was at least two inches in breadth. The liver was small and dense, and bile oozed out of it in every direction. After death distinct crystals of tyrosine and cystine were detected in the liver. The head of the pancreas was enlarged, and on section a quantity of pus flowed out. There was as great dilatation of the pancreatic duct as of the bile-ducts. On opening the duodenum, there was found a sinus communicating with an abscess in the head of the pancreas. The tumour of the pancreas was inflammatory only. In the kidneys were found abscesses, and the structure which was left was extremely fatty. On examining the urine after death, scarcely any albumen was discovered. This is a most instructive case, as it shows how valuable an adjunct chemistry is to the other methods of diagnosis in disease of the abdominal organs.

Dr. Harley, *21st of January*, 1862.

---

30. *Obliteration of the biliary ducts in an infant.*

F. B., was a patient of Dr. Wilks, at the Royal Infirmary for Children. The mother stated that at birth the child had no dark motion (meconium) as is usual, but a white one, and this continued without

Digitized by Google

any exception until death. When a fortnight old jaundice appeared, and he was then brought to the Infirmary. A little grey powder and rhubarb were ordered, and no fear expressed as to the result of the case. The jaundice however continued, and death took place when the child was six weeks old.

Post-mortem examination.—All organs healthy. Liver of usual size, and of a very dark green colour, as usually observed in cases of fatal jaundice. On examination of the under surface, there appeared to be no gall-bladder existing, but on dissecting the cellular tissue which occupied its place, there was found in its midst a narrow channel just able to hold a bristle, and which, no doubt, was the representative of the gall-bladder. On endeavouring to find a continuation of this into the bile-ducts, none could be discovered; and then, on searching for the bile-ducts themselves, these seemed totally obliterated,—merely some cellular tissue existing between the hepatic artery and portal vein. In the duodenum the opening of the duct was found as usual, and a probe passed freely into the pancreas, but no passage could be found into a bile-duct. It thus appeared as if they had all become closed, and wasted away.

Dr. Samuel Wilks, 18*th of March*, 1862.

---

31. *Large abscess of the liver consequent upon dysentery, without the usual symptoms.*

A married woman, æt. 37, was admitted into St. George's Hospital on the 19th of March. She was much emaciated. Her complexion was sallow and unhealthy, and the feet were slightly œdematous. She complained of pain in the right hypochondrium, and on examination of this region, a large tumour was felt, extending from the position of the liver to below the umbilicus. The bowels were confined; the urine flocculent with albumen.

She said that she had been ill for one year, that she had continuously lost flesh and strength, and had had pain about the region of the liver. She had never been out of England, nor did she admit that she had ever had any looseness of the bowels.

While in the Hospital the bowels were constipated, so that aperient medicines were required. She generally lay still, making no complaint, and taking little notice of anyone. She took nourishment freely, but became prostrate, and died on the 27th, without any further symptoms, excepting a trivial attack of diarrhœa the day before.

When the body was examined, nothing was found which requires

Digitized by Google

notice except in the abdominal cavity. When the walls were turned aside, the liver was seen to be enormously enlarged, extending quite into the umbilical region. The left lobe was thrust to the extreme left, and did not seem to participate in the enlargement. When the lower edge was raised, a vast quantity of pus suddenly broke loose, and overflowed the table. It was estimated that at least a gallon must have thus escaped. As it ran out, it, the right lobe of the liver, was seen to shrink, and it was found that this portion of the organ had been converted into an abscess, containing the stated quantity of pus. The lobe was almost of a globular shape. It was reduced to a mere cyst, with exceedingly thin walls. The inferior wall seemed scarcely to contain any liver-substance, but was formed by the right kidney, the supra-renal body, flattened out, and the layers of omentum. The latter had been torn when the liver was separated from the bowels, and thus the pus had escaped. When the pelvis of the right kidney was cut open it was seen to contain a number of rounded masses of stratified coagulum, of brownish colour. The gland itself was healthy. The kidney and the other structures which assisted to confine the pus were cemented by firm adhesions to the liver and to each other.

The upper part of the large intestine was in a state of ragged ulceration, such as occurs with dysentery. It ceased abruptly at the edge of the ileo-cæcal valve. The absorbent glands in the neighbourhood were red and swollen.

The cavity of the peritoneum contained a small quantity of turbid fluid.

Commentary.—This case offers a striking illustration of the insidious course which dysentery sometimes pursues. An abscess of the largest size was found in the liver, without any suspicion during life of the disease. The ordinary symptoms of dysentery were, as far as could be ascertained, altogether absent. The concentric fibrinous coagula, which were found in the pelvis of the right kidney, prove that successive hæmorrhages had taken place into that cavity. There seems to be no way of accounting for this occurrence but by supposing that inflammation, probably circumscribed, had from time to time been lighted up in the tissue of the organ by the process of adhesion which rendered the kidney part of the wall of the abscess.

Dr. Dickinson, 1*st of April*, 1862.

Digitized by Google

32. *Specimens of cavernous growth in the liver.*

These are generally found at the edges or under surface of the liver, and are met with accidentally in the body, being unattended by any symptoms during life. They are probably often overlooked or regarded as mere masses of blood, of the nature of apoplexies of other organs. If, however, they are washed of their blood, and more carefully examined, they will be found to be composed of a delicate reticulated tissue, resembling very much that of the corpora cavernosa penis, or erectile tissue in other parts of the body. Several specimens are contained in the Museum of Guy's Hospital, and have been described as hæmorrhages resulting from injury, as nævi, and as cancers. In one or two cases, a history of a blow in the region of the liver has existed, but if this is to be regarded at all as important, it is only as the starting-point of a new growth, and not as instrumental in producing a condition which was thought to be merely a network of hepatic tissue, remaining after the part had been crushed. The idea of cancer was obtained from the fact of one patient, in whom this growth was found, having cancer of the bladder, and the opinion was strengthened by the observations of Rokitansky, who has described a highly vascular network as constituting sometimes the basis of cancer. The designation, nævi, originated simply in the belief, which still prevails with some, that all highly vascular growths, or sanguineous multilocular cysts have probably a congenital origin, and thus tumours of the kind here described as occurring in the liver have been styled nævi when met with in the various internal organs of the body. There is no reason, however, to doubt the fact, that growths of a similar kind may originate from injury or otherwise in various parts of the system in adult life.

Dr. Samuel Wilks, *15th of April*, 1862.

---

33. *Obstruction of hepatic veins and vena cava by fibrous deposit in liver.*

G. W., æt. 34, a sailor, had been in the tropics. He was admitted into the Hospital with ascites and swelling of the legs. This was thought to be dependent on hepatic disease. He was tapped, with relief; but on a second occasion the operation was followed by peritonitis and death. He had scars in the groin, as from old buboes, and also an excavation on the penis, near the frœnum.

On *post-mortem* examination, the liver was found very firmly adher-

Digitized by Google

ent to the right side, and also to the diaphragm above. When the latter was removed, a quantity of very tough yellow material was cut through. This substance, which was seen on the surface, penetrated the liver tissue, and occupied a large portion of the posterior part of the right lobe. There was a mass of this substance as large as the two fists put together. It was tough, yellow, and dry, resembling what, in other cases, has been called syphilitic deposit. This mass was made up of a conglomeration of a number of round nodules, about the size of marbles, on the circumference of the mass. Some of these were almost isolated; and, at a greater distance, there were smaller distinct deposits of the same character. The most important fact, in connection with this adventitious material, was its surrounding some of the hepatic veins, as they entered the vena cava, and even encroaching on the cava itself. Thus the lower part of this vessel was of the usual size, but as it passed through the liver it was encroached upon, and much diminished in calibre, by the protrusion into its interior of one of these hard nodules. Close to this, two openings of the hepatic veins were seen; one was very small, and the other closed, or if not entirely closed, so small as only to admit a probe forced through it. On opening the latter, the vein was seen to dilate behind its closed mouth, and this dilatation continued into the substance of the liver. The vein was also occupied by an ante-mortem softening coagulum. This adventitious fibrous material had also continued its course along two or three of the principal branches of the portal vein, and thus Glisson's capsule was occupied by the same hard, yellow substance. This continued in one or two cases to the surface of the liver, and the transverse sections of the portal vessels showed them surrounded by a wide ring of this substance. The liver was extremely congested, and in parts actual extravasation of blood had taken place. Ducts apparently healthy, and of natural size; so also the arteries. Other organs healthy.

This case is interesting, both as to its diagnosis and pathology, for it shows how obscure still must be our knowledge of the functions of the liver, when the principal symptom denoting such an entire alteration in its structure, as seen in cirrhosis, is simply that which is due to obstruction of the circulation, and which, as seen in this case, may be accidentally produced by altogether different means.

As regards the nature of the disease, it is one about which further information is required, and especially as to whether the deposit, as here seen, was formed or grew there as such? or whether it was the remnant or result of a more fluid inflammatory process? Constantly, on examining the bodies of those who have been in the tropics and

Digitized by Google

suffered from hepatic disease, the livers may be found containing an amorphous white, firm, substance, and in some cases some softer material, like dried pus, intermixed with it; and the question has consequently arisen, whether an abscess has once existed in the organ, and the more fluid parts of its contents having been absorbed, this firmer and cheese-like substance has been left, or whether this firmer material, as finally discovered, was not primarily formed as such. In some of these cases, a dysentery has been known to exist, together with the hepatic affection; and therefore it may be surmised, that just as a suppuration may occur in the course of the portal veins, together with abscesses in the substance of the organ, so a plastic lymph may sometimes be thrown out instead, productive of a hard fibrous matter, in the same channels and in the substance of the liver itself.

The question of syphilitic disease could not be discussed, as there was no history of the disease having existed; and, according to modern ideas, the scars on the genital organs and groin would be no proof that the constitutional form of the malady had ever been present.

Dr. Samuel Wilks, *15th of April*, 1862.

34. *Scirrhous enlargement of the pancreas.*

This case occurred in the practice of Mr. Barnes, of Chelsea. I performed the *post-mortem* examination with this gentleman and his son. A man, æt. 62, about two years since complained first of symptoms of indigestion, with pain in the back. He was sick occasionally, and was subject to frequent heartburn. About five months since he became jaundiced; but this yielded to medicine, and the yellowness of the skin disappeared for a short time, but it soon returned, and he was jaundiced up to the time of his death. He gradually became emaciated and lost strength, the leading and prominent symptom *being a constant dull aching pain in the back:* he had no symptoms that indicated the presence of gall-stones. The motions were always clay-coloured, but they were never fatty when examined. The bowels were very much constipated, so that the use of enemata was constantly required. Two or three months before his death, when on the night-chair, he felt something, as he said, give way in the bowels, and he thought that he had ruptured himself. He gradually became weaker, and died in April last.

The body was extremely emaciated; the skin of a deep yellow colour; the lungs sound; the heart very soft and flabby; its muscular structure, as was that of every part of the body, very lax; the liver rather soft

Digitized by Google

and mottled. The gall-bladder contained about twenty biliary calculi, varying in size from that of a pin's-head to that of a small nut; the hepatic ducts were much thickened, but pervious; the pancreas throughout was hard and scirrhus-like, its head much enlarged; the gland weighed five ounces and a-half. All the normal secreting cells were replaced by irregular elongated cells, many of them tadpole-like. The lobes were surrounded by a large amount of fibrous tissue. The kidneys and their capsules were normal; the colon and rectum were much distended with soft clay-coloured fæces; and several ruptures of the peritoneal coat of the first-named intestine were present—some longitudinal, some transverse; one in the former direction was nearly three inches long and an inch wide in one part. Several of these ruptures exhibited traces of reparative action. In some of the smaller, the muscular fibres of the intestines were partially separated. The brain was not examined.

This case in many particulars affords, I think, matter for profitable contemplation. The numerous ruptures of the peritoneal coat of the large intestine, as far as I know, are lesions very rarely met with. There is but little doubt that some of them took place when the patient was on the night-chair, and when he thought "that he had ruptured himself." When, however, the general laxity of the tissues, especially of the muscular fibre, is taken into account, the occurrence becomes less remarkable.

The pancreas was, when taken from the body, of a stone-like hardness; but this hardness diminished greatly on immersion in spirits. The patient digested fats apparently as well as any kind of food, and, indeed, was said to be very fond of fat. The constant pain in the back, over the seat of the pancreas, is another feature in the case of practical interest. Mr. Barnes had long diagnosed disease of the pancreas, and he was induced to form this opinion chiefly from the character of the jaundice, he having witnessed a similar case, in which the same kind of pancreatic lesion was present. Dr. Crisp, *6th of May*, 1862.

Digitized by Google

V.—DISEASES, ETC., OF THE GENITO-URINARY ORGANS.

SUB-SECTION I.—KIDNEYS, BLADDER, CALCULI, ETC.

1. *Stone in the bladder. Lithotomy. Death.*

G. A., æt. 66, admitted into the Norfolk and Norwich Hospital, under my care, in August, 1861. A healthy, hard-working farmer. Symptoms of about three years' duration; rather severe; he micturates every hour or two, with cutting pain after each act, lasting fully a quarter of an hour; urine slightly turbid; sp. gr. 1020, faintly acid; contains a trace of albumen, but little mucus, and seldom any blood.

He was sounded two or three times, without feeling the stone; but by passing an instrument with a short sharp curve (which it was not easy to do), I readily felt a calculus, which was not small, behind an enlarged prostate; there appeared to be a bar at the neck of the bladder, and a deep prostatic sinus in front of it.

August 16th.—I cut him by the median method. There was some trouble, and considerable traction requisite, to drag the stone through the enlarged prostate. A small oval fibrous tumour came away, during the operation, in the forceps, but not with the stone. There was free bleeding, but no vessel visible; a tube was introduced and the wound plugged.

The stone was composed of lithic acid, was oval and hard, and weighed one ounce and a-half.

For six days the patient prospered well; his pulse averaged 70; his tongue was clean, and appetite good; clear water passed freely by the tube; the plug was gradually removed; and on the seventh day I withdrew the tube, and at my visit then, I considered it impossible for him to be doing better. He was cheerful, ate a chop for his dinner, and drank some wine and water. Towards evening the water did not pass so freely; still, he did not complain. At midnight he was seized with violent rigors, which he compared to an ague he had suffered from a few years previously; his pulse became small, quick, and thready; he soon vomited, and the bowels acted, and water passed freely. At half-past three A.M. I visited him. His skin was hot and dry; pulse about 130, small and weak; could scarcely speak, and was only half conscious; he got gradually weaker, and died about nine A.M., only seven or eight hours from his seizure.

Post-mortem examination.—All the organs of the body were healthy.

Digitized by Google

The kidneys contained serous cysts, one being very large. The bladder was observed to be discoloured on its outside by ecchymosed blood, not in any quantity, but it reached up each side of the bladder, and showed through the peritoneum. There was no trace of urinary infiltration, no slough or pus anywhere. The bladder itself was rather full of, but not distended with, urine; its mucous membrane was pale, and without any sign of inflammation. Here and there a small spot of ecchymosis was observed, but on the whole it was remarkably healthy; there were several minute sacculi, and one very large one, which latter gave the bladder the appearance of being divided into two nearly equal compartments. The aperture of communication was just large enough to admit the tip of one's forefinger, and was placed about the middle of the right side. The muscular wall was rather thicker than usual, and many fibres spread over the sac.

The prostate gland was enlarged to the size of a common orange, the left lobe somewhat larger than the right, and projecting somewhat into the bladder. Each lobe was seen to be made up of fibrous tumours, which were easily enucleated with the handle of the knife, leaving a considerable thickness of prostatic structure outside. The surface of the lobes was slightly lacerated by the dragging of the calculus over or through them.

There was a small ovoid enlargement projecting into the bladder, about three-quarters of an inch behind the base of the prostate: probably it was a fibrous tumour, and was, though it seemed not to be, connected with the gland.

The wound made at the operation cannot now be accurately seen; it was enlarged by the manipulation; it traversed the whole length of the membranous urethra, and extended about half through the base of the prostate.

I cannot satisfactorily account for this man's death. Up to the seventh day he seemed to be doing quite well. The first indication of his going wrong was after removing the tube. Six days had elapsed, and I thought, considering the time, and how favourably he was progressing, that it might fairly be withdrawn. I now regret that it was removed, for, owing to the enlarged and tumefied state of the prostate, he began at once to fail in his power to void water. During the remainder of that day the bladder filled gradually, and although a good deal was expelled, it was not able entirely to empty itself.

Mr. Henry Thompson, for Mr. Cadge, *15th of October*, 1861.

Digitized by Google

2. *Enormous sac connected with the kidney, recognised as such during life, and repeatedly emptied by tapping.*

Mr. S., from whom I removed this interesting morbid specimen, first sought my advice on May 21st, 1851. He was at that time suffering from much pain in the left side in the region of the kidney. There were considerable enlargement and tenderness on pressure extending over the left hypochondriac, lumbar, and iliac regions. Dulness on percussion also existed in these regions. I ascertained that he had had symptoms of disease of the kidney for a considerable period—such as retraction of the testis, pain in the left loin, and over the side of the hip; indeed, all those sympathies which are usually aroused in diseases of that organ.

The surgeon in attendance assured me, that he had witnessed precisely the same state of things as described above, and that the patient had become suddenly relieved after passing, all at one time, more than a "pôt-de-chambre" full of water, of the colour of Port wine.

As I had no reason to doubt the correctness of his observation, and as the case did not seem to require any immediate surgical relief, we agreed to wait, and in about a week the sac appeared to have entirely emptied itself through the ureter, bladder, &c. The symptoms disappeared, and the patient (May 31st) apparently soon recovered.

On November 28th he began again to suffer from the same symptoms, which increased in intensity up to January 27th, 1852. At this time he had all the symptoms before described. The side was greatly enlarged and tender. There was an obscure sense of fluctuation on percussion, and the dulness extended towards the right as far as the linea alba; backwards as far as the spine; downwards to the lowest part of the iliac region; and above, the diaphragm and lung were pushed upwards, and the heart also was found pulsating much higher in the chest than natural. His sufferings were now so great, that I determined to draw off the fluid with the trocar, and it only remained to decide upon the part where it should be introduced. I had no doubt that the sac containing the fluid was a dilated kidney, or a cyst having some connection with the pelvis of that organ; and in either case I selected the interval between the two last (floating) ribs, near their anterior extremities, at which to introduce the trocar. I fixed on this spot for the following reasons:—

1.—Supposing the fluid to be contained in a sac having communication with the pelvis of the kidney, the kidney would lie behind the sac, partly upon the last two ribs, and partly upon the quadratus

Digitized by Google

lumborum muscle, its normal situation on this side; and if the instrument were introduced at the place indicated, and its point directed a little forwards, it would penetrate the sac without any risk of wounding the kidney.

2.—If the sac consisted of a dilated kidney, the point selected would still be the best, as it would be near the part (central) at which the organ began to dilate.

3.—It would be behind the peritoneum, and therefore there would be less risk of wounding that membrane.

4.—If the patient had been tapped in front, the trocar must have passed through the peritoneum twice; first, that portion lining the abdominal muscles, and second, that in front of the sac; and supposing no adhesion to have taken place between these two parts, when the instrument was withdrawn, some of the contents of the sac might have escaped into the cavity of the peritoneum, and given rise to inflammation. Besides, there would have been more danger, I think, of wounding some of the bowels, should any portion have become adherent by inflammation between the walls of the abdomen and the sac.

I therefore performed the operation between the two last ribs, near their extremities. An incision was made through the integuments and muscles; a small exploring trocar was then introduced; and, as there was evidence of the existence of fluid, a larger instrument was inserted with its point directed slightly forward, and eight quarts of dark-coloured fluid were drawn off. It is a singular fact, which will perhaps be explained on examination of the specimen, that soon after this fluid was removed, the further contents of the sac flowed in the natural direction, along the ureter, &c. This could be ascertained from the quality and altered condition of the urine.

I need not waste your time by unnecessary particulars. The patient soon recovered, but it was necessary to repeat the operation on December 1st, 1852. On this occasion, three quarts and a-half of fluid were extracted; soon after which, as before, the sac emptied itself through the natural passages, as evidenced by the colour, &c., of the urine.

The patient soon got well, and did not require the operation again until 24th March, 1860. At this time seven quarts of fluid were taken away; not long after which, the fluid again found its way along the natural passages, and the patient again made a quick recovery, and remained well until September 23rd, 1861, when I was requested to see him. I found him suffering from considerable pain and fulness of the left side; indeed, a return of all his symptoms. The disease appeared to be progressing, as on former occasions, until the 5th of October, on

Digitized by Google

which day, at five o'clock A.M., I was suddenly summoned. He had been suddenly seized with pain in the abdomen, more especially at the lower part, difficulty of micturition, cold perspirations, quick respiration, rapid pulse and anxious countenance. The abdomen was full and tense, and there was a sudden suspension of the action of the bowels. The right side of the scrotum was distended as in hydrocele, and it was decided, under the circumstances, to tap this, in order to examine the inguinal canal, and ascertain the possibility of rupture. No hernia existed. His symptoms, therefore, were attributed to rupture of the sac. He took calomel with large doses of opium every three hours, and a mixture composed of salvolatile and compound spirits of sulphuric ether and camphor mixture, and a large blister was applied over the abdomen. Under this treatment in two days his bowels acted freely, and he seemed to be going on favourably, until Friday, October 10th, when he suddenly became much worse and died.

A *post-mortem* examination was made on Sunday morning, October 12th. The body was plump and in good condition. He had assisted in getting in his harvest, and expressed himself as being as "strong as a lion" before the commencement of this his last illness.

There was much fat between the skin and muscles of the abdomen; and on opening the cavity of the latter, there were unmistakeable proofs of peritoneal inflammation. Much lymph was poured out upon the bowels, which were glued together; and there was a considerable quantity of sero-purulent fluid in the cavity of the pelvis. Three pints of dark-coloured water were removed from the right hypochondriac and epigastric regions, like that contained in the sac, which is exhibited to the Society, and which occupied the left lumbar region; extending upwards and downwards, and having such relations as I have before described. (The descending colon being before and towards the left side of the sac; the aorta towards its right; the spleen above and behind, and the diaphragm also above; the ureter below, entering the sac at its lower part anteriorly, and passing obliquely through its parietes to the cavity). At least four pints of fluid were removed from this sac, in which a hole was discovered towards the left side, and anteriorly, where the rupture had taken place. On putting my finger through this opening, I felt a loose, hard, calcareous or cretaceous body, which is also exhibited. A large opening was made in front of the cyst, through which the fluid was removed. Another opening will also be found, more to the side, which was accidentally made with the scalpel; but it is easy to see which was the *ulcerated* one. The ureter, which is observed entering the cavity *obliquely* through the wall of the cyst,

Digitized by Google

will probably account for the *closure* of that tube, by pressure, when the sac was full; and the *open* state of it, when the sac was empty. I have no doubt the rupture took place on the 5th of October, when the peritonitis began, and in all probability there was some escape of fluid, but not much, at that time; and that there was a further and larger escape on the 10th, when he suddenly died; more especially as this fluid was *like that contained in the sac*, and as it occupied *the upper part of the abdominal cavity, and was not mixed with inflammatory products, or with that which was contained in the pelvis.* There was no stone in the bladder, or obstruction in the ureter. The early history of the case makes me think the patient passed urinary calculi; but after I was called in to see him I could never discover any; nor were any discovered at the *post-mortem* examination.

Mr. Henry Thompson *for* Mr. Joseph Thompson,
5th of November, 1861.

3. *Adipose transformation of the kidney, following calculus and abscess in that organ, opening through the lumbar muscles.*

J. C. R., æt. 11, always pale and delicate, two years ago had an abscess in the left loin, which had, since that period, left two or three sinuses discharging pus. He was brought to me, at the St. Pancras and Northern Dispensary, on the 23rd of October, 1861, complaining of general ill-health, presenting a pale anæmic aspect, with the usual indications of general debility, but without pain. One sinus then existed about an inch below the last rib, on the left side of the spine. No indications of vertebral disease existed, nor ever had done; but on examining the abdomen, a tumour was found in the left lumbar region, which, from its situation and character, was diagnosed as renal. A few days afterwards, before I again saw him, he was attacked with peritonitis and double pleurisy, with a rapidly fatal result. It was ascertained, on visiting him at home, that scarlatina had attacked two other members of his family, one of whom had died about a month previously, and that this child had suffered from sore-throat and submaxillary swelling a fortnight before; but there was seen no rash, and no desquamation of the cuticle existed; and I had no opportunity of examining the urine.

On examination after death, a probe, introduced into the sinus in the loin, passed through the lumbar muscles into the psoas magnus. There was much turbid fluid, with flakes of lymph, and recent deposit of lymph in both pleural and peritoneal cavities. The right kidney was

Digitized by Google

enlarged, and in a state of acute chocolate-coloured congestion, soft and very lacerable. The left lumbar region was occupied by the tumour now shown, which could only be removed by dissecting it out, and was situated in the position of the left kidney, and was closely attached to the psoas magnus, a portion of which was removed with it. It measures six inches and a-half by three inches and three-quarters, and consists almost entirely of dense adipose tissue. On making a longitudinal section, small abscesses are shown, and a calculus is found in one of them. These are connected with each other, and, through a sinus, with the psoas muscle, and evidently communicated with the opening in the loins of the patient. A mere trace of renal structure occupies the centre of the fat-mass, indicating faintly the outline of the original kidney. The abscesses seem to have been situated in what were the pelvis and calices of the organ, a probe passing from one to the other. The microscope reveals adipose tissue and loose fat-granules, and some traces of Malpighian bodies in the small outline of the cortex, before mentioned. There appears no trace of ureter, or of the normal renal vessels.

This case appears to have originated in calculous pyelitis, leading to the formation of abscess, penetrating the psoas and lumbar muscles, and opening externally, being followed by atrophy of the renal structure, infiltration of the whole organ with adipose tissue, and hypertrophy of the fat-growth enveloping the kidney. Such a condition is described by Rokitansky as an essential disease, but this case goes far to prove the ætiology of such cases; as, had the abscess healed up, the calculus having also disappeared in the discharges, its origin might not have been indicated or suspected.

Dr. J. Hullett Browne, *5th of November*, 1861.

---

4. *Horse-shoe kidney, affected with Bright's disease.*

The patient was a young man, æt. 27, who was the subject of anæmia lymphatica, and who died in the Charing Cross Hospital, under Dr. Willshire's care, on the 25th of May, 1861, with general dropsy. He had been subject to enlargement of his lymphatic glands for two years. The cervical, axillary, inguinal, and other glands were much enlarged during life. The urine was albuminous and smoky some months before death. *After* death the liver and spleen were found greatly enlarged; the former weighed five pounds and a-quarter, the latter one pound and three-quarters; the kidneys were mottled, and united by a lobe at their inferior part, which crossed over the spine

Digitized by Google

(Woodcut 8). This band of union was an inch wide, and consisted of

WOODCUT 8.

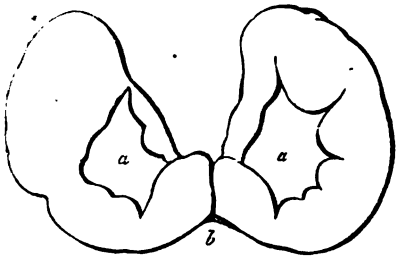

Represents the horse-shoe kidney, in outline.
a a. Pelvis on either side.
b. Groove or sulcus.

a fusion of the substance of the one with the other. A distinct pelvis was present in the body of each half, supplied each with a single ureter. The entire organ was affected with Bright's disease. All the cavities of the body contained serum, and nearly all the internal and external lymphatic glands were enlarged.

I thought at first that this peculiar malformation of the kidney was rare; but on looking through the London Museums, I have met with as many as nineteen different examples, presenting various anomalies in regard to the number of the ureters and renal arteries.

The following Table shows the Hospitals containing them, with the number of specimens in each, to the end of June, 1861:—

Charing Cross	1
St. George's	1
Guy's	3
St. Bartholomew's	3
Middlesex	2
St. Thomas's	2
University College	1
St. Mary's	3
College of Surgeons	3
	19

In Guy's Museum one of the preparations is connected by a band of fibrous tissue at the lower part, rather than of glandular structure; and one of the ureters is nearly or quite obliterated. The specimen marked 109, in St. Bartholomew's Museum, is the largest I have as yet seen.

Digitized by Google

In the Museum of the College of Surgeons, one of the specimens is from a fœtus. In St. Mary's Museum, one of these double kidneys has three ureters, two being from one half, and one from the other. Another specimen there, besides renal arteries, has a supply of blood from a large vessel, given off near the division of the aorta, which bifurcates and enters the convexity of the kidney.

Besides the horse-shoe kidneys, there is a kidney in St. Bartholomew's Museum elongated to twelve inches; and Mr. McWhinnie tells me that he examined a case of diabetes in which there was but one kidney; and another in which both kidneys were situated low down in the loins, and were supplied indiscriminately by a large number of vessels from *all* sources.

In Vol. VI. of our "Transactions," Mr. Henry Thompson describes a kidney with a double pelvis and ureter, the other kidney being I presume normal. In Vol. VII. a horse-shoe kidney is described by Dr. Bence Jones; the specimen is preserved in St. George's Hospital Museum. Dr. GIBB, *3rd of December*, 1861.

5. *Fragments of a large stone, broken up in the bladder by means of forceps, and removed by lithotomy, from a sacculated bladder.*

G. W., æt. 43, was admitted into St. George's Hospital on the 10th of December, 1861.

For twenty-five years he had occasionally found that pieces of sand, resembling mortar, had passed away. At one time he suffered severe pain in his back, but until the last two months he had experienced no pain in the neighbourhood of the bladder. Since that period he found that he was perfectly unable to retain his water, which dribbled from him as he walked, or as he sat at work.

A sound introduced struck upon a stone before it entered the bladder, and there was difficulty in passing the instrument beyond this point. It was therefore supposed that a calculus might have lodged in the prostatic portion of the urethra, and that this part of the canal had consequently lost its elasticity, and its power of preventing the escape of the water.

After the patient's admission into the Hospital, a sound was twice passed, and upon each occasion it was stopped before it could have been in the bladder. The examination caused considerable pain, and as the patient, who was of a very nervous excitable temperament, was extremely unwilling to have the operation repeated, it was resolved to

Digitized by Google

defer any further investigation into the exact nature of the case until he should be placed under the influence of chloroform.

He remained in bed in the Hospital until the 19th of December, when he was taken to the operating theatre, and placed in the usual position for lithotomy. A staff, almost straight, was introduced until stopped by the stone. Upon this, an incision was made in the median line of the perinæum, and the finger introduced into the wound was met by a large calcareous mass, evidently adhering to the surrounding parts, and immoveably fixed. The idea at once presented itself of breaking up this mass with a lithotrite; but a careful examination of the part showed that there was no room for the passage of the instrument to the back of the stone. It was therefore determined to attempt its extraction by the forceps. In order to facilitate this operation the parts nearest the neck of the bladder were divided laterally on each side. The incisions, therefore, resembled those which would be made in the bilateral operation for lithotomy. Another difficulty now presented itself. Upon introducing the forceps, it was found that they would not grasp the stone. The blades of the largest pair of forceps in the Hospital were so far separated when placed upon the opposite sides of the stone that they failed to seize it fairly in its diameter. The forceps consequently slipped from the surface of the stone, which remained fixed in its position. A pair of forceps were therefore used, the inner surface of the blades of which was strongly indented. By this means portions of the outside of the stone nearest the perinæum were broken off; and in this way, after several fragments were removed, a nucleus was reached, which was extracted entire. But even after this, a large mass of stone was felt by the forceps and scoop, further up in the bladder, and apparently adhering to its parietes. This was at length all removed in fragments, partly by the forceps and partly by the scoop, and the patient was sent to bed. The fragments of stone which were collected, after having been repeatedly washed, were sufficient to displace seventeen drachms and thirty-three grains of water. It was of a light material, the specific gravity of the nucleus being 2·543, and the weight of the fragments collected being thirty-one drachms and sixteen grains. The composition of some of the fragments was examined by Mr. Schweitzer, and found to consist principally of the urates, with a smaller amount of triple phosphates. Some of the outer portions of the stone presented a rough uneven surface, indicating probably the parts that had been adherent to the mucous membrane of the bladder.

The day following the operation, December 20th, the patient said

Digitized by Google

that he had had a very bad night, but was not in pain: "is stronger this morning, and feels very well." Pulse 110. Skin moist.

At one o'clock the pulse was 120. Had slight pain at the bottom of the stomach, but did not feel "constitutionally ill."

At nine P.M. the pulse was 112, and the face covered with perspiration. Still felt some pain at the bottom of his stomach, which he attributed to "wind."

December 21st.—Said that he had passed a pretty good night, and did not feel as an invalid. Had pain, off and on, in the stomach; tongue slightly coated; pulse 120, regular, but feeble; complains chiefly of the taste of the chloroform in his mouth.

One P.M.—Pulse 140, occasionally intermitting. Profuse perspiration.

Nine P.M.—Pulse 120, very feeble and intermittent. He described himself as pretty comfortable, and in no pain, except now and then from wind in the stomach.

December 22nd.—Said he had passed a very nice night, but wished he could get the taste of the chloroform out of his mouth. Pulse very feeble, 104. Had some hiccough this morning at five o'clock. He died at three P.M.

On making a *post-mortem* examination of the body, the whole of the lining membrane of the bladder was found greatly congested. The cavity was small, and must have been very nearly filled with the stone. It presented several pouches of considerable size, and at the neck of the bladder was a dilatation, about half the size of the bladder itself. (Plate V.)

The other pouches were of different sizes, one of them large enough to contain a chestnut, but with a comparatively small opening into the bladder. The dilatation at the neck of the bladder had no doubt been filled with stone for a considerable period, and as this had encroached upon the urethra, it had in all probability destroyed the natural elasticity of this part of the canal. The absence of pain for so long a period in this case, may probably be attributed to the calcareous matter having been deposited upon, and adhering to, the mucous membrane. The bladder, under the circumstances, could scarcely be said to contract upon the stone, inasmuch as it was always in contact with it. The urine, when secreted, might lodge in the various pouches formed in different parts of the bladder, but the bladder itself would admit of very imperfect distention. There was a little atheroma on the aortic valves, which, however, would close perfectly. The lungs were full of frothy fluid; the bronchial tubes congested, and choked with

Digitized by Google

Digitized by Google

DESCRIPTION OF PLATE V.

The Plate represents **Mr. H. Lee's case of Sacculated Bladder, from which a large Stone had been removed by Lithotomy (p. 136).**

Digitized by Google

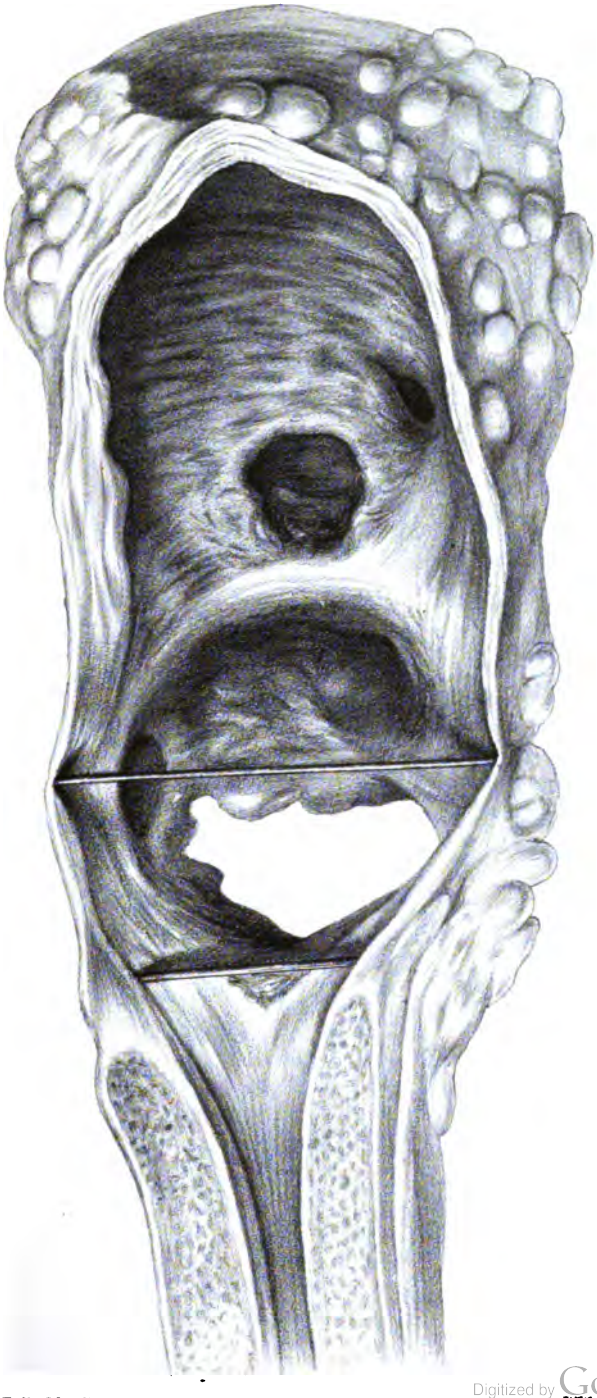

Tuffen West. lith.

Digitized by Google

W. West imp.

Digitized by Google

mucus. There was no peritonitis. The liver was pale and fatty; the kidneys healthy; the other viscera natural.

I am informed by Mr. Hearne, of Southampton, that in May, 1860, he removed a calculus, five ounces six drachms and a-half in weight, the smallest circumference of which was seven inches. In this case there were no forceps, in an ordinary lithotomy case, which would grasp the stone, and it was removed by a scoop. Had the stone not been adherent in my case, a similar plan might have been adopted.

Through the kindness of Mr. Charles Hawkins, I have an opportunity of showing another specimen, in which very extensive deposit of stone had taken place upon the mucous membrane of the bladder, and formed a cast of that part to which it adhered.

Mr. H. Lee, *4th of February*, 1862.

---

6. *Kidney distended into a large cyst, which subsequently became filled with colloid matter, mistaken during life for ovarian disease.*

This preparation was sent to me by Dr. Cecil Hastings, in whose practice the case occurred. The following history accompanied the specimen:—

It was taken from a woman more than 70 years of age. Ten or twelve years before her death, a tumour appeared in the left side of the abdomen, which all the practitioners who saw her agreed in regarding as ovarian. This gradually increased; but her health, in other respects, remained for a long time unaffected. Her chief inconvenience was due to the irregular action of the bowels, diarrhœa alternating with constipation. Latterly she was in the habit of relating, that "nasty stuff" frequently passed from the urethra, the tumour at the same time diminishing in bulk. This coincidence, however, does not appear to have been credited by her medical attendants. She never suffered from dropsy, or from severe pain. Until within forty-eight hours of her decease she was able to sit up, in the enjoyment of tolerable comfort. The immediate cause of death appeared to be a severe attack of diarrhœa, with bloody stools.

Post-mortem examination.—The belly was occupied by a large tumour, over the surface of which the descending colon was stretched, and to which it was united by adhesions. The tumour proved to be the left kidney, which was dilated into a vast bag, with membranous walls. The cavity was subdivided by septa into a number of compartments, all of which communicated with the pelvis, and thus with each other. In many places the septa were perforated. The whole cavity was filled

Digitized by Google

with gelatinous matter resembling colloid. (Woodcut 9.) The walls,

WOODCUT 9.

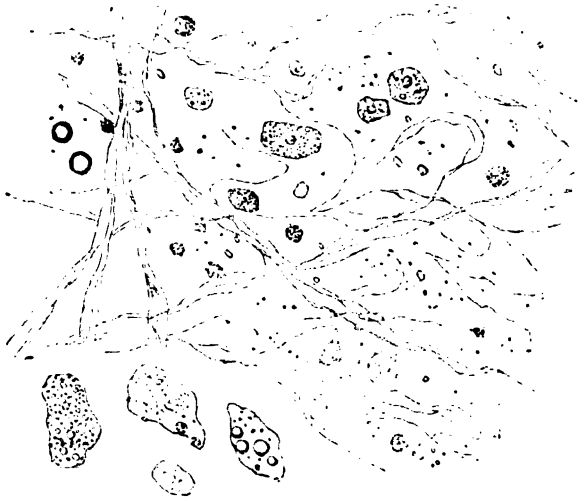

Represents some of the colloid matter removed from the kidney, as seen with a magnifying power of four hundred diameters. The reticular part resembles white fibrous tissue.

though generally thin and membranous, were coated in some places with a deposit of considerable thickness, which was in some places evidently a collection of colloid cysts. Adhering to the outer wall, at several points, were some irregular stony masses, some as large as chestnuts, which, on analysis, were found to be pure phosphate of lime. At the upper part of the mass, the supra-renal capsule was found still attached to the outer surface. The cavity communicated freely with the ureter, which was larger and much longer than usual, and was open without interruption as far as the bladder. The tumour still retained the shape of the kidney. The organ was not measured until its size had been much diminished by immersion in strong spirit. The greatest circumference, which was in the vertical direction, was then thirty inches and a-half; the long diameter was eleven inches; it measured in the horizontal direction, round the central or narrowest part, twenty-one inches; from before backwards the diameter was six inches and a-half.

The right kidney was healthy, excepting that the surface was slightly granular. The other organs were all healthy.

Digitized by Google

Commentary.—It appeared that the accumulation of colloid matter must have been a subsequent event to the dilatation of the organ. The deposit was everywhere separable from the walls. Although at the time of death the ureter was quite unobstructed, it is probable, that at the commencement of the disease, this was not the case. The masses of phosphate of lime which were attached to the walls were possibly mere renal calculi, one of which had for a time blocked up the ureter, and thus given rise to the distention of the organ. This condition was most likely increased by the accumulation of the colloid material.

The long duration of this tumour, the comparatively unimpaired health of the patient, until within two days of her death, the absence of any variety of malignant disease in any other organ, and the easy separability of the growth from the walls of the dilated kidney,—all conduce to a belief, that colloid growths, though often associated with acknowledged forms of malignant disease, and in some respects allied to them, have such points of difference as entitle them to a separate classification.

A drawing is annexed, which will show that the microscopic structure of the gelatiniform substance was such as usually belongs to colloid growths, with the addition of large cells, like some form of fatty epithelium. Dr. DICKINSON, *4th of February*, 1862.

---

7. *Renal calculi.*

The specimens now exhibited were sent to me by Dr. Roome, Physician to the Dartmoor Prison. They were all removed from the right kidney of a convict, æt. 60, who, it appears, had lived a very dissipated life prior to his conviction. During the two years succeeding his conviction, he suffered from gastric derangement, but never manifested the slightest symptoms that would lead to the suspicion of renal disease. This is the more surprising, seeing that five ounces and a-half of calculi were, after death, removed from one of his kidneys (the left contained none), and that one of the calculi alone weighed no less than three ounces and three-quarters. This, the largest, is of a most peculiar form. It looks exactly like a fœtal pig made in marble, the head being surmounted with a circular crown of sparkling crystals. Several of the smaller calculi show very beautifully where the friction has taken place between their surfaces. One or two of them have apparently some blood mixed up with the inorganic matter; but, notwithstanding this, there is no evidence of the patient

Digitized by Google

ever having suffered from hæmaturia. The man died from cancer of the pylorus, which caused a stricture of the part, hardly admitting of the passage of a crow-quill. It is not at all improbable, that any slight renal symptoms, if there were any, were masked by the more serious disease of the stomach.

Dr. GEORGE HARLEY, *4th of February*, 1862.

---

8. *Existence of a calculus in the urethra, for a long period, probably fifty years, during which it increased greatly. Accompanying symptoms, and coincident state of bladder-disease. Nature of the calculus. Question as to the mode of formation.*

W. A., Esq., a remarkably hale, vigorous man, of some literary repute, a most inveterate bibliomaniac, and rather a free liver, had for some years a variety of occasional illnesses of the gouty order; amongst which were a patch of psoriasis on the leg, after that headaches, then, in each of four succeeding winters, an attack either of bronchitis, or of gouty inflammation of the bladder. The symptoms of this last-named malady were such as are usual; frequent and copious deposit of mucus, the urine rendered alkaline by the mucus, but itself containing an abundance of crystalline lithic acid. These attacks were treated by purgatives and hip-baths, and soon subsided, so as to leave the urine nearly free from mucus, the bladder able to hold it with comfort, and the patient able to pursue his usual recreation, which was to walk immense distances through the most obscure parts of London, examining the book-stalls, and buying any rare specimens he might find, with which he loaded himself, bringing them home on foot in a bag. These details will give some idea of the patient's general habits and condition; and it may be observed, that although he often complained of "gravel," and the urine was often loaded with mucus, yet that his occasional coughs and headaches were far greater sources of trouble to him, and more frequently mentioned to his medical attendant. In August, 1856, being then seventy-seven years of age, in consequence of severe urethral pain, he pointed out with much reluctance a hard swelling in the perinæum to his usual physician, Dr. Druitt, who called me to consult on the case.

Behind the scrotum, and encroaching on it, was a round symmetrical tumour, intensely hard, inelastic, not painful under touch, and over which the skin was healthy.

According to our patient's account, he discovered some tumefaction after an attack of gonorrhœa when a young man, and the growth of the

Digitized by Google

tumour had been very gradual. Still, on the present occasion, he could not say that it had ever troubled him. He would allow no examination to be made except with the finger, as for many years he had resolved never to allow the urethra to be explored. I could come to no conclusion whatever, and could not even venture to guess at the nature of the affection.

For the next twelve months, or more, this gentleman was always complaining of urethral pain after making water, but as his general health did not give way, nor his appetite fail, nor his power of taking exercise diminish, it was, in consequence of accompanying symptoms, attributed to senile catarrh of the bladder, with occasional exacerbations from gouty inflammation.

Dr. Druitt was sent for on the 13th of June, 1858, after an unusually long absence. The patient was feverish and slightly delirious at night. There were frequent micturitions with scantiness of urine, symptoms which always accompanied a gouty attack. The next day he was no better, and as the scrotum had commenced to swell, and was red, I was again summoned in consultation.

I suspected the occurrence of extravasated urine. I was not allowed by my patient to attempt to pass a catheter, nor to examine the bladder by the rectum.

At my visit on the following day, I found my suspicions respecting the extravasation realized. The scrotum and the penis were immensely swollen and discoloured, and the prepuce on the verge of sloughing. The bladder was very much distended. The delirious and irrational condition afforded opportunity for acting, and I commenced by puncturing the bladder through the rectum, and withdrew a very large amount of fœtid urine. I next proceeded to explore the urethra, but I could not find the meatus, till I divided the black blistered and infiltrated integument. A catheter was readily passed to the urethral swelling, where it came in contact with a calculus. I now quickly cut into the perinæum, and removed the stone; not with ease, however, for it adhered much to the sac around it, which seemed to be merely dilatation of the urethra.

There was loss of the delirium, and so much improvement for a day, that it seemed probable recovery would ensue, but in the next twenty-five hours prostration set in, and was quickly followed by death. No *post-mortem* examination was allowed.

Now as regards the calculus; it had remained unnoticed among others that I have removed by lithotomy, till a few days ago, when I was making a minute inspection of these specimens. It measures two

Digitized by Google

inches and a-quarter by one. (Woodcut 10). There is an absence of

WOODCUT 10.

Represents the calculus, on its external surface, and in section.

any apparent nucleus, and the whole seems as if made up of several masses of phosphate of lime, and triple phosphate pressed together, with intervals or markings irregularly dispersed, and evidently composed of organic deposit, thicker in some parts, and withal displaying faint indications of concentric layers, especially at one end. But the most remarkable objects are two minute prostatic calculi, which happen to have been cut across, lying together near the circumference of the stone at the side, but just within it. They form pretty microscopic objects.

I searched for other prostatic calculi in vain.

I have brought this case forward as one of urethral calculus, as distinguished from prostatic calculus, on account of its variety, and the obscurity that surrounds the pathology. Although I have made no extensive search among surgical records for any such, I have certainly looked into all the surgical works to which I had easy access; and the only case bearing any resemblance is mentioned by Mr. Erichsen, as having come under the notice of Sir R. Caswell, in whose collection, at University College Museum, is a drawing of the parts, with stone, which was in the front portion of the urethra, and equal in bulk to two horse-chestnuts. No more is said of the matter.

Large calculi have been found in the urethra, coincident with one, or more, in the bladder. I assisted Mr. Lawrence in private to remove, by perinæal incision, what was supposed to be a stone embedded in the membranous part of the urethra of several years' standing. It was necessary to cut into the prostate. It proved very large. Mr. Lawrence put his finger into the bladder, detected a stone there, and removed it also. Mr. Fergusson exhibited, during the past year, at the Pathological Society, one very large calculus taken from the bulb of the

Digitized by Google

urethra, and one from the membranous portion, and a small one from the bladder of the same patient.

During my house-surgeonry at St. Bartholomew's Hospital, a patient was admitted by me, having a collection of minute calculi, in a large sac, apparently at the bulb of the urethra. They were tightly packed, and when handled felt like emery in a bag, and emitted a creaking sound. No operation was performed.

In the Museum of St. Bartholomew's Hospital, is a part of one hundred and forty-six calculi taken from a sac connected with the middle of the spongy portion of the urethra. It was not certain whether the sac was formed by the urethra dilated behind a stricture which existed immediately in front of it, or was formed after ulceration of the urethra in the tissues around it.

It cannot be determined how the stone was formed in the present case. It is not impossible, I think, that with stricture of the urethra, a calculus may there be deposited. At first, I suspected it probable that the prostatic calculi had acted as nuclei for this mortar-like deposit, but from their position and the existence of the concentric lines alluded to, I think that such a theory is untenable.

Mr. Haynes Walton, *4th of February*, 1862.

---

9. *Atrophy of the right kidney, probably from former distention of the pelvis and calices by urine, with proportionate hypertrophy of the left kidney.*

R. E. C., æt. 46, a tailor, admitted into the Middlesex Hospital, under the care of Dr. Goodfellow, on the 10th of February, 1862, at ten P.M.

From his wife's account, it appeared that his illness commenced four days previously, with pain in the right side of the chest, difficulty of breathing, cough, and sickness. Two hours before his removal to the Hospital, his wife, on her arrival home, found him lying on the floor insensible, and foaming at the mouth. In this state he remained until his admission. At this time he was insensible; his breathing was stertorous, spasmodic, and superficial; the pupils were equal, slightly contracted, and acted sluggishly to changes of light. There was trembling of the limbs, but no rigidity. After removal to bed, he became partially conscious; he protruded the tongue when asked, but could not answer questions intelligibly, though he appeared to understand their purport. The limbs were extremely tremulous, as was the tongue, which was dry and red. The tremblings very closely resembled

Digitized by Google

those of *delirium tremens*. There was no paralysis. Small crepitation and bronchial breathing were detected over the lower lobe of the right lung. The heart-sounds were distant; no murmur; pulse 142, very small and compressible. Abdomen was flaccid. Urine, drawn off by catheter, was found to contain albumen, which was precipitated by heat and nitric acid, in a state of minute division.

He soon relapsed into profound coma, the pulse became weaker and weaker, and he died the same night at half-past one A.M., without any convulsions.

Post-mortem examination, twelve hours and a-half after death. *Head.*—Dura mater firmly adherent to upper edge of hemispheres. A warty-looking growth, about the size of a large pea, and composed chiefly of fat, was attached to the superior surface of the dura mater; it was lodged in a depression in the frontal bone on the right side, about an inch from the junction of the coronal with the sagittal sutures. The dura mater was not adherent to the opposite layer of arachnoid in this situation. Surface of brain opaque; much gelatinous infiltration beneath the arachnoid. The meningeal vessels were much distended with blood. Beneath the velum interpositum, and on the optic thalami, there were two or three patches slightly raised above the surface, and of the diameter of mustard-seeds, which resembled tubercle. The brain-substance was pale and rather soft. About four ounces of limpid serosity in lateral ventricles; these were considerably enlarged, as if the quantity of serum had previously been greater. A considerable quantity of serosity escaped on removing the brain.

Chest.—About one ounce of thick yellow serum in the pericardium. This membrane was rough and injected, and there were some shreds of recent lymph upon its visceral layer. Weight of heart, eleven ounces and a-quarter. Right lung, fifty-six ounces, universally adherent, and at the base and posterior surface of the lower lobe, there was a thick false membrane. The upper lobe was very œdematous, and slightly emphysematous, and contained several hard calcareous deposits of a nearly black colour, which resembled tubercle, and which had undergone the process of obsolescence. Some were softer, and somewhat cheesy in the centre. The lowest and middle lobes were in a state of grey hepatisation, shaded off at the edges and near the surface with irregular patches of red hepatisation, which were interspersed with other patches of simple inflammatory engorgement. The left lung was also œdematous, and in upper lobe emphysematous. This lobe also contained several deposits of obsolescent tubercle. It was also universally adherent to chest-wall, but there was no dense false membrane.

Digitized by Google

Abdomen.—Liver, ninety-one ounces; capsule thickened, and, at the posterior edge of right lobe, it was much injected; tissue of the organ very pale, and apparently fatty; substance firm. Spleen the same as liver. Left kidney, eleven ounces and a-half; a cyst, about the size of a small pea, on its posterior surface; the organ was congested, and somewhat fatty; the capsule was not thickened, and was easily separated from the surface, which was smooth.

The right kidney (Woodcut 11) weighed five drachms; capsule

WOODCUT 11.

thickened—it could not be separated without tearing the substance; surface deeply lobulated; substance tough; calices considerably enlarged. Impacted in one of them was a calculus of about the size of a pea. The renal artery about one-third the normal size; the ureter a little more than half the natural size. About an inch before its termination in the bladder, the calibre would only permit the passage of an ordinary-sized bristle. The walls of the bladder were much thickened and contracted. On examining the structure of this kidney by the microscope, the tubes

Digitized by Google

could be distinctly seen. There was a considerable quantity of fat, both in the tubes and between them.

The following is the description of the calculus, by Mr. Thomas Taylor, who was so good as to analyze it:—"It is of an irregular figure, and has a polished tuberculated surface of a dark colour. The interior is imperfectly laminar. When heated, it gives off an urinous odour, blackens, and finally leaves a large white ash, which has an alkaline reaction. It affords decided evidence of the presence of uric acid. I should describe it as a mixed calculus, consisting of phosphate of lime, with phosphate of magnesia and ammonia, uric acid, and a little oxalate of lime."

The great point of interest, for which I have been induced to place this case on record, is the extreme atrophy of the right kidney, and the proportionate increase of size of the left. The cause of this remarkable difference in size and structure between the two organs, is to be explained in the following probable sequence of events:—The impaction of a calculus at some former time in the lower part of the ureter, by which the escape of the urine was rendered for a time impossible. The consequent accumulation of the urine in the upper part of this canal, in the pelvis, and calices (and perhaps also the tubes); and the distention of these parts. Atrophy, from pressure, of the structure of the kidney, arising probably in two ways, firstly, by cutting off in great measure the supply of arterial blood to the secreting tissue; and secondly, by absorption of the compressed substance itself. The increasing distention of the ureter, and the great pressure of urine behind the seat of obstruction, ultimately forced out the impacted calculus, but not before it had produced permanent thickening and stricture of the ureter, by the inflammation set up by its residence there. The obstacle to the passage of the urine from behind having been removed, the ureter, the pelvis, and the calices, gradually returned to the dimensions observed after death. The small amount of functional work performed by the atrophied organ for so long a time, imposed supplementary duty upon the left kidney, and hence the hypertrophy of this organ, in obedience to the physiological law of increased growth in proportion to increase of function.

It is to be regretted that the upper part of the ureter was overlooked at the *post-mortem* examination, and also that no history of the passing of a calculus, or of the suffering occasioned by its impaction for so long a period of time, could be obtained. It was at first supposed that there was no right kidney; and it was only by carefully dissecting out the aorta, and tracing the wasted right renal artery to its destination, that

Digitized by Google

the small kidney was found, embedded as it was in a considerable quantity of fat. The discovery of the strictured portion of the ureter near the bladder, and of the mixed calculus filling up and firmly fixed in one of the calices, renders the above conjectural sequence of changes, almost certain. At first, and before the finding of the stricture, I was disposed to regard it, in part, as a rudimentary kidney, rendered still smaller by the gradual reduction of its functional activity.

Dr. GOODFELLOW, 18*th of February*, 1862.

---

10. *Malposition of the left kidney, and sigmoid flexure of the colon.*

This specimen was obtained from a man, æt. 27, who died of bronchitis, in the Charing Cross Hospital. There were no symptoms during

WOODCUT 12.

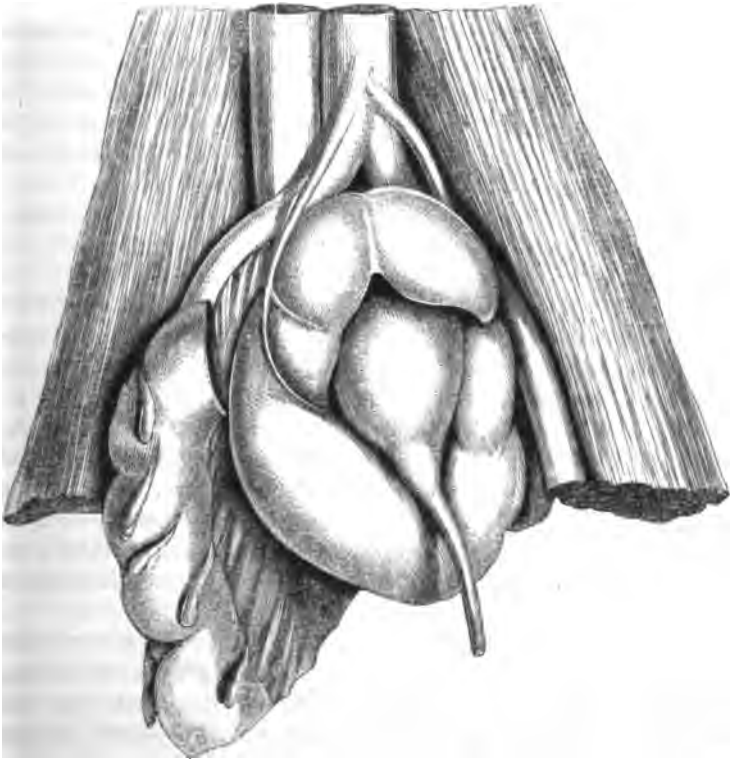

Represents the lobulated appearance of the kidney, and its relations to the aorta and sigmoid flexure of the colon.

Digitized by Google

life which bore reference to the kidneys. The right gland was found in all respects normal. The left one was situated below the bifurcation of the aorta, as shown in the engraving. (Woodcut 12). The ordinary reniform character was wanting, and, in some parts of the surface, lobulation persisted. The pelvis of the organ was directed, almost immediately, forwards; and the upper portion of the ureter was distended by the impaction, within it, of an oxalate of lime calculus weighing two drachms and a-half. The left emulgent arteries were two in number, and sprang from the forepart of the aorta, at a short distance above its division. The sigmoid flexure of the colon was placed on the right side of this kidney.

The left supra-renal capsule was in its natural situation. This circumstance I have noticed in two or three other instances, where the corresponding kidney has been out of place, and it is thus remarked upon by Cruveilhier* :—"In the numerous cases in which the kidneys occupy some unusual position, the supra-renal capsules do not accompany these organs in their displacement. Thus, when the kidneys are situated higher than usual, the capsules are placed on their inner side, and correspond with the renal fissure; when the kidneys occupy the pelvic region, the capsules undergo not the slightest change in their position, and no longer have any connection with them."

Mr. CANTON, *18th of March*, 1862.

---

11. *Two pounds of fat removed during life from a cyst near the bladder.*

This was sent up to the Museum of Guy's Hospital by Mr. Pretty, of Fressingfield, in order to obtain an opinion as to its nature; accompanying it was the following history:—

G. M., æt. 21, of previous good health, sent for me on December 31st, 1861. I found him suffering intense pain, and unable to void his urine, except in quantities of about an ounce at a time. He stated that he had for the last twelve months experienced more or less difficulty in passing his water; that on the 15th of December, when on a visit to some friends in Norfolk, he was seized with the most intense pain from not being able to micturate. A surgeon was sent for, who attempted to pass a catheter, but failed; a hip-bath was then recommended, which proved partly successful, and was persisted in daily. On December 25th he was enabled to return home, when, becoming worse, I was requested to see him on the day above stated. I found him in great pain, with the right side of the abdomen greatly distended,

* Descriptive Anatomy. Transl. in Tweedie's Library, Vol. I., p. 592. Lond., 1851.

Digitized by Google

with what appeared to be the bladder. I introduced a catheter, and drew off upwards of five pints of urine, leaving the instrument in the bladder. On examination *per rectum*, I perceived a very hard tumour, which I then thought might be an enlarged prostate; I ordered leeches to the perinæum, and a hip-bath. On the following day he was better, but the catheter having been inadvertently removed, I had some trouble in re-introducing it. He continued thus for some days, passing his water through the instrument, but the tumour could still be felt through the rectum. At the same time his health appeared to be retrograding, and the constitutional disturbance was increasing. I therefore requested Mr. Read to see the patient with me on the 9th of January, when, after removing all the water from the bladder, there remained a distinctly fluctuating tumour, extending upwards about three inches above the pubes, but extending more to the left than the right side; a further examination also, *per rectum*, showed the presence of a tumour towards the left side. On the 10th he was seen again by Mr. Read and by Mr. Gramshaw, when we passed a very long catheter into the bladder; the instrument was found to pass to the right side, but was unable to be turned to the left. The strength of the patient was now daily diminishing, his appetite was failing, febrile disturbance was great, and the abdomen was tympanitic. There were also occasional hiccups, rigors, and other severe symptoms. On February 6th, being dissatisfied with the progress of the patient, I requested Dr. Miller and Mr. Read to see him with me, when we determined to explore the tumour with a small trocar. I passed a small instrument into it through the rectum, when there flowed out a few drops of a greasy semi-transparent substance, which became solid on cooling. I then with a larger, longer, and curved trocar, again pierced it, and drew off about two pints of an oily matter, which soon became solid on cooling. This was found to be two pounds in weight. The patient made a rapid recovery.

The fatty matter has undergone no change by keeping, it is soft, has no odour, and a general resemblance to fresh butter. It melted readily at ninety degrees, and was soluble in ether. It exactly resembled in character the fatty matter which is sometimes found in the dermoid ovarian cysts, being fluid at the natural temperature of the body, and readily solidifying as soon as removed. A great uncertainty must remain as to the nature of the cyst, seeing that no similar cases are on record whereby to suggest its character. The only tumours known to contain a material of this kind, are those dermoid cysts which are occasionally found in various parts of the body as congenital growths.

Digitized by Google

The probabilities are therefore in favour of the existence of some such cyst from the period of birth, and which has gradually been pouring out this fat from the sebaceous glands, which cover its interior.

Dr. Samuel Wilks, 18*th of March*, 1862.

---

12. *Membranous bag said to have been passed from the female bladder.*

J. F., æt. 29, three months advanced in pregnancy, was admitted into the London Hospital, September 7th, 1861, with retention of urine consequent on retrocession of the uterus, and also with a silver female catheter, which had been employed on the 4th to evacuate the bladder, in the cavity of that organ. During the above interval, futile attempts were made to remove the foreign body, both by forceps and lithotrite, and the patient being now in great pain, and the bladder greatly distended, Mr. Maunder enlarged the anterior half of the urethra in a direction downwards and outwards, with a bistoury, and removed the foreign body with the finger introduced into the bladder. A large quantity of urine, highly charged with blood, was poured out.

On September 10th, the patient was placed under the care of Dr. Barnes, and symptoms of acute cystitis prevailed for many days, when, at length, she exhibited the membrane shown to the Society, as having been passed from her bladder. She has since been delivered of a living child, but has been unable to retain the urine since the first attack of retention.

Mr. Maunder, 15*th of April*, 1862.

Report on Mr. Maunder's case.—We have carefully examined the membrane, said to have been passed from the bladder of a female, and exhibited by Mr. Maunder at the last meeting of the Pathological Society.

We find it to be made up mainly of interlacing bands of muscular fibre, and apparently of the tissue of the bladder itself, in its integrity. The opening of one ureter, if not those of both, is distinctly visible.

We have no doubt that the membrane in question is the bladder of some animal, most probably that of the bullock; and that it has not been passed in the manner which the patient represented.

Dr. Murchison,
Mr. Henry Thompson, 6*th of May*, 1862.

Digitized by Google

13. *Congenital hydro-nephrosis. Artificial production of acute albuminous nephritis.*

The subject of this case, E. J., was under the author's observation from two years of age until his death, August, 1861, at six and a-half years of age. He was throughout the interval an in- and out-patient of the London Hospital.

When first seen he had been treated for ascites, and was relatively as large as a woman at the full period of gestation. His mother stated that the child was born with a preternaturally large abdomen, and that it had gradually increased without any alterations of size, except such as she attributed to a full meal, or temporary confinement of the bowels. The child was of spare figure, dark hair and eyes, face pale, but he appeared to enjoy good health. The only injurious effect of the large abdomen was greatly to limit exercise.

Careful examination of all the functions failed to throw light upon the origin of the swelling, or to indicate which, if any, of the organs of the abdominal and pelvic cavities was connected with it. It was simply diagnosed to be "a congenital abdominal cyst." Paracentesis was delayed lest the cyst should not be adherent to the abdominal walls, so as to enable that operation to be performed without danger of escape into the peritoneum of fluid foreign to that sac. This unfortunate result had occurred to a hospital patient of the author's, who was tapped for simple serous cyst, connected with the under surface of the liver.

Firm bandaging, inunction of iodine, mercury, and the usual expectant treatment having been employed in vain, the tension having augmented, the thorax and the abdominal viscera becoming much interfered with, and the health disturbed by the tension, pain, and restlessness, and the chances of adhesion to the peritoneum having increased, the parents being willing also to incur the risk of any operation, paracentesis was performed, when he was three years and a-half old. The fluid evacuated was limpid and colourless, and the specific gravity 1·004. Recovery from operation was as prompt as from ordinary paracentesis abdominis. A tight bandage was applied, but the cyst refilled in a few weeks as large as before. Paracentesis was repeated at intervals of about three months. On the third occasion, Dr. Little noticed a faint urinous odour in the evacuated fluid, and the presence of urinous substances was proved by Dr. Letheby. The renal character of the cyst and its dangerous nature were now manifest. The parents were informed, in answer to their earnest applications for per-

Digitized by Google

manent relief, that the child must bear the burden of this swelling through life, and that no operation beyond paracentesis, such as injection of the cyst, incision or removal, was exempt from the gravest danger to life.

At the fourth tapping, July, 1860, the dimensions of the abdomen were, at the epigastrium, twenty-seven inches; at the umbilicus, thirty inches; at the hypogastrium, twenty-eight inches. The fluid then had a stronger urinous odour, and contained both urea and uric acid.

At the fifth time of tapping (October 26th, 1860), he measured two inches and a-half more. One hundred and forty-five ounces of strong urinous fluid were drown off, slightly acid, specific gravity, 1·010, containing urea, uric acid, chlorides, sulphates, and triple-phosphates. The urine passed by urethra was at this time, specific gravity, 1·114.

November 6th, 1860.—The parents, disappointed at the continued refilling of the cyst, were not unnaturally anxious that something else should be attempted, even at the risk of life, if it offered any prospect of ameliorating the child's condition, by enabling him to run about without the burden of the tumour, and the periodical distress to breathing and digestion, which the recurring large swelling induced; it was determined, therefore, in consultation with Mr. Adams, by whose opinion and operative interference in the case I had already profited, to endeavour to form a fistulous opening. At this period the case was considered to be a congenital urinary cyst, springing from and developed at the expense of a single kidney—in fact, an expanded uriniferous tube, calyx or pelvis of a kidney, probably similar to some of Rayer's cases—with some remains of cortical structure on the interior, or communicating with it. The tumour was now so considerable, as to bulge out on either side of the spine behind. Mr. Adams selected, as the most favourable spot for this operation, the right flank immediately below the last rib, where the walls of the cyst and the integuments appeared to be most thinned. A piece of elastic catheter was passed through the canula of the trocar, before its withdrawal, and was left in the puncture. Sixty-five ounces of fluid only were purposely drawn off, specific gravity 1·113, similar to that of the last tapping, but more urinous in odour. The urine passed by the urethra the same day, before the operation, was reported scanty, specific gravity 1·022. The object of the operation being at least to secure a fistulous opening, it was considered desirable not entirely to evacuate the cyst, but to allow the fluid to flow off at intervals, and the cyst gradually to contract; from which we hoped that the inflammation likely to result from leaving in

Digitized by Google

the catheter would be limited in degree and extent, and perhaps nephritis be avoided. On the day after the operation, the report was:—Expression good; tongue clean; skin moist; pulse 130, quick; no complaint of pain; but was sick; fluid dribbles occasionally from the catheter. On the second day after operation sickness was troublesome, but he had good appetite, slept well, and had no pain. On the seventh day after operation report stated:—Catheter removed on account of constitutional disturbance; sickness continues; moans and cries frequently; pulse very frequent. On the ninth day the skin was cooler; less pain, pulse 100, still very feeble; an ecthymatous eruption on abdomen; urine found albuminous to-day; occasional sickness. It may be here remarked, that until this period of the case the constitutional disturbance was regarded as the consequence of inflammation of the renal cyst, and of the remains of the kidney with which it was assumed to be connected, excited by the temporary presence of the catheter. But with the appearance of albumen in the urinary secretion discharged by the urethra, as no communication with that tube was supposed to exist on the part of the renal cyst, and the remains of the kidney from which it was supposed to spring, albuminous nephritis of the hitherto sound kidney was suspected.

On the tenth day appetite returned; urine albuminous; lithates copious; abdomen has rapidly refilled since removal of the catheter, and healing of the puncture. On the fifteenth day, pus abundant in urine; abdomen tense, covered with purpura-like patches and boils. On the twenty-first day, abdomen much larger than before last operation; no sickness; dozes a good deal. On the twenty-fourth day, still pus in urine; dimensions at epigastrium, twenty-six inches; at hypogastrium, thirty inches; at umbilicus, thirty-one inches. Tapped again to-day. One hundred and ninety ounces of very thick stale-smelling fluid removed, urinous and alkaline, containing a large amount of pus, a good deal broken up, some epithelium, urea, uric acid, phosphates, and lithates, specific gravity, 1·030. Examined for urea by Davey's process, 20m = ·07 cubic inch of nitrogen, = 1·008 grains of urea per ounce (nearly), or 191·5 grains of urea in the whole quantity. On twenty-fifth day easier, a little sick. On twenty-eighth day, better, but weak and fretful; cyst rapidly refilling; thirst; tongue red, clean and moist; passes hardly any urine, and that in the bed. Thirty-first day, the urine collected to-day has specific gravity, 1·015, contains gr. 1·44 per ounce of urea; still passes most urine in bed. Thirty-sixth day, very sleepy, great prostration, appetite good. At the eighth week report says:—Emaciated; but cyst larger than before;

Digitized by Google

two hundred ounces removed by tapping. At the tenth week, cyst distended to nearly the same size; general health improved; urine dribbles away; gets up daily for a short time; appetite good.

At the fourth month reported getting fatter; can walk with assistance; urine still a little puriform. From this time he improved rapidly, and quitted the Hospital (April, 1861) five months after the attempt to make a fistulous opening; but with the cyst as large as when admitted. He was re-admitted into the Hospital in June, for the purpose of being tapped; one hundred and twenty ounces were removed; specific gravity, 1·005, neutral; no urinous odour perceptible, purulent, odour peculiar; some crystals of cholesterine observed. The operation was repeated in July. He left the Hospital after this tapping, pale, hectic, emaciated, walking about; still some pus in the urine. He died out of the Hospital on August 6th, 1861, having been convulsed and comatose forty-eight hours.

Post-mortem examination, thirty hours after death.—The body was much emaciated, and the abdomen was not distended; there was no rigor mortis.

On opening the abdomen, the parietal peritoneum was found firmly adherent, on the right side, to what proved to be a large cyst, occupying the right half of the abdominal cavity, nearly to the middle line, though not descending into the iliac region. This cyst appeared to enclose the right kidney, was firmly adherent to the cæcum, ascending colon, portions of ileum, the right lobe of the liver, and to the diaphragm. The ureter ended in the cyst-wall, and through it a puriform fluid, containing shreds like lymph, could be pressed into the bladder. The left kidney had also expanded into a cyst, though a much smaller one, about the size of a large cocoa-nut, and communicated freely with the bladder by means of the corresponding ureter; the fluid in this cyst was tolerably clear.

The liver was pushed entirely over to the left side. Below it were the stomach and spleen, the intestines occupying the small remaining space. These organs all appeared healthy.

The bladder, the walls of which were much thickened, contained a fluid similar to that in the larger cyst. The lungs were studded with small tubercles; heart was healthy; other organs not examined.

The larger or right cyst had, after removal from the body and careful separation of adherent tissues, the appearance represented in Plate VI., Fig. 1.

On the side farthest from the spine, the kidney appeared as if spread out into a layer nearly half-an-inch thick, about eight inches long by

Digitized by Google

Digitized by Google

DESCRIPTION OF PLATE VI.

The Figures illustrate Dr. Little's case of Congenital Hydronephrosis (p. 154).

Fig. 1. The right kidney and ureter.

Fig. 2. The left kidney and ureter.

Both figures are much, but proportionately, reduced in size. The kidney represented in Fig. 2, was as large as a cocoa-nut.

Digitized by Google

Fig. 2.

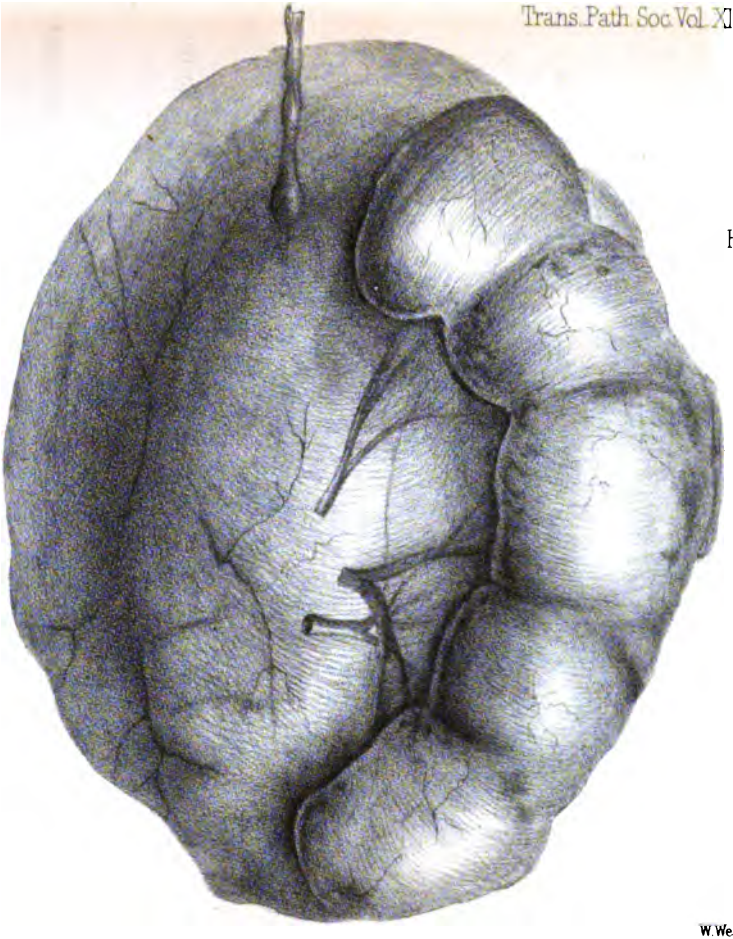

Fig. 1.

Tuffen West. lith.

W. West. imp.

Digitized by Google

Digitized by Google

four wide, obscurely lobulated. The cyst was almost collapsed, and contained not more than a pint of fluid, although very little had escaped at the *post-mortem* examination. It measured twenty-three inches in circumference at the longest part, and sixteen in circumference at the widest part.

The interior of the larger cyst presented a smooth surface like that of a serous membrane. On one side of the cyst were eight large apertures, varying from half-an-inch to two inches in diameter, near one another, opening into recesses in the wall of the cyst, which was here about one-third to one-half of an inch thick, being the remains of the expanded kidney. These openings corresponded probably to the calices of the healthy kidney, in some cases several calices forming one of these apertures. No distinction could be made out with the naked eye between cortical and tubular substance, owing probably to the great expansion the kidney had undergone, as in other respects the tissue appeared normal.

The ureter opened into the cyst opposite the remains of the kidney, with an aperture of scarcely more than normal size.

The smaller or left cyst, represented in Plate VI., Fig. 2, had the same characters, except that the remains of the kidney were much thicker, and the openings into the cyst, or calices, smaller; in fact, this kidney and cyst presented the same appearances in a less advanced stage. Dr. W. J. Little, *15th of April*, 1862.

---

14. *Case of enlarged kidney with an irregular shaped calculus firmly impacted and moulded into the calices of the pelvis.*

Nothing is known of the history, except that it was taken from the body of a man of middle age, who had been treated for renal disease at one of the large Metropolitan Hospitals, and, not being satisfied with the results of his treatment, insisted upon leaving the Hospital. During his removal from the Hospital to St. Pancras Workhouse in a cab, he died.

The stone was of a very irregular shape, elongated, and beset with five or six rounded processes, which were firmly embedded in the calices. In general shape the calculus was not unlike a piece of coral.

Dr. Hillier, *15th of April*, 1862.

---

15. *Two large calculi and a portion of the prostate removed in the operation of lithotomy.*

Mr. H., a robust healthy man, æt. 72, had suffered with symptoms

Digitized by Google

of stone in the bladder for nearly ten years. The pressure on the bowel and the disposition to strain at stool were so great, that he believed himself to be suffering chiefly from piles, and for these he had been more than once under medical treatment; now there are only a few external ones to be seen.

The bladder-irritation had been excessive, he micturated every half-hour or less; there was incontinence of urine, and he was constantly wet; this point is worth remembering in connection with his present state.

His general health was good, he had an intermitting pulse occasionally, but there seemed nothing besides this to contra-indicate an operation.

Feeling sure that the stone was large, I preferred to cut him by the lateral method, and Mr. Henry Thompson kindly assisted me by holding the staff, November 4th, 1861. I found the prostate gland so much enlarged, that my finger (a tolerably long one) could not reach the bladder or touch the stone, nor could I of course discover the precise condition of the prostate towards the bladder. A longish pair of forceps was used, and a full-sized stone readily seized and soon removed, though with a good deal of pressure and tractile force. In the forceps, between the stone and the joint of the blades, there came away three masses, which were found to be apparently fibrous outgrowths of the prostate; the largest was about the size of the last joint of the finger; together they weighed one drachm two scruples.

A second calculus was easily removed, of the same size and shape as the first. They were apparently composed of lithic acid, and weighed nearly four ounces.

The patient went on well for a time; the urine was slow in coming by the urethra; the wound became sloughy, the urine fœtid and alkaline; large quantities of phosphatic mortar-like matter were passed chiefly by the wound, and some by the urethra. In about two months, the wound was perfectly healed; the urine is still neutral and contains mucus; and there is incontinence, which may be in great part due to the removal of the prostatic tumour, but it must be remembered, that it also existed before the operation. He is strong and well in all other respects.

It has happened to me twice before to remove small fibrous tumours of the prostate gland during the operation of lithotomy, and apparently without harm to the patient.

It is curious that this accident (as I suppose it may be called) of lithotomy remains unnoticed in standard Surgical works. The mode

Digitized by Google

of its occurrence is worth ascertaining, and I know of no better account than that contained in a letter from a medical friend, one of the most expert and experienced of modern lithotomists; he says, "It has occurred to me eight or ten times to bring away portions of the prostate, and without noticeable injury to the patient. In more than one instance it was the prominent third lobe which got up between the handles *anterior* to the hinge, and was torn off entire. In others, the same occurred as did to yourself, the lobe or portion was within the triangle between the hinge and the stone, the stone in this case bringing with it the knob of prostate. In still other cases, a round fibrous body, like a beech-nut, has been enucleated by the pressure of extraction from the substance of the gland."

He also adds, "although I have never known unpleasant results to the patient, and that sometimes he has been benefited in after life by having got rid of a useless impediment to a natural function, I would not willingly that such an occurrence should happen, and I try to avoid it by turning the blade of the forceps to the lower angle of the wound as I leave the bladder; but, when it does occur, I lay no account by it."

Mr. H. Thompson for Mr. Cadge, *6th of May*, 1862.

---

16. *Medullary cancer of the bladder.*

This was removed from a man, æt. 64, who died in the Westminster Hospital under the care of Mr. Barnard Holt. Six months before his death he had applied to Mr. Heath, at the St. George's and St. James's Dispensary, for relief from pain in the bladder and penis, bloody urine, and loss of health. He was sounded for stone but none was found, but *per rectum* a tumour was felt, between the bladder and rectum, immediately behind the prostate. He continued to lose large quantities of blood to within a month of his death, when he passed hardly any blood and very little water, and that with great difficulty and straining. The passage of a catheter was excessively painful.

Occupying the "trigonum vesicæ," and extending, in a semicircle of one inch and a-half diameter from the back of the prostate, was a mass of medullary fungus, which, when the parts were in their normal position, filled up the neck of the bladder almost completely. The prostate and urethra were uninvolved, and were perfectly healthy. The orifices of the ureter were situated in the mass, and were partially, if not entirely, occluded, a probe being passed with great difficulty, and the ureters being dilated to twice their usual size. Nodules of soft can-

Digitized by Google

cer were developed under the mucous membrane at several points throughout the lower part of the organ.

The mucous membrane of the rectum was healthy, but about two inches up a hardened mass could be felt, which extended for some distance up the outside of the bowel, and was caused by a deposit of cancer between the bladder and rectum, which involved the vesiculæ seminales. Mr. CHRISTOPHER HEATH, *20th of May*, 1862.

---

17. *Left kidney extensively sacculated, and containing numerous minute calculi. Obstruction of ureter by three calculi. Right kidney condensed in structure, and studded with minute calculi.*

S. B., æt. 6, admitted into Middlesex Hospital under Dr. Stewart, on the 8th of April, 1862.

On admission she presented the following symptoms, for an account of which I am indebted to Dr. Stewart. There was considerable prostration; a listless expression of countenance; the eyes were dull; the skin was hot and dry, with numerous marks of fleabites in it; the tongue was moist and white; no appetite; bowels irritable; motions mixed with blood; no tenderness or gurgling in the right iliac fossa, nor tympanitic distention of abdomen; inflammation of both anus and vulva; pulse 120, small and feeble; heart-sounds healthy; some sonorous and sibilous rhonchi scattered over the chest; urine scanty.

On the 9th.—On account of epigastric pain and frequent vomiting of greenish fluid a sinapism was applied to the epigastrium, and five minims of chloric ether in mucilage were given to her occasionally. There were frequent slimy stools, which, as well as the urine, were mixed with blood, coming apparently from the anus, which was very painful, and superficially ulcerated; there was more irritation of the vulva; otherwise the same as yesterday.

11th.—Heat and dryness of skin, looseness of bowels, and oozing from anus and vulva continue; much less vomiting; urine voided without difficulty, but always mixed with blood.

Tinct. ferri sesquichloridi ♏xv. acidi hydrochlorici ♏i. potassæ chloratis gr. iii. aq. menth. pip. ad ℥iss, 6^tis^ horis.

13th.—Grows weaker; diarrhœa continues; motions slimy, mixed with blood; ulceration spreads around anus and vulva; pulse rapid and feeble. Vini rubri ʒiv. indies. Lotio potassæ chloratis, ano et vulvæ.

14th.—Much as yesterday; motions still frequent, flaky, mixed with blood; the urine, which is passed at stool, also mixed with blood; no

Digitized by Google

Digitized by Google

DESCRIPTION OF PLATE VII.

To illustrate Dr. Goodfellow's case of Sacculated Kidney, with Obstruction of the Ureter by Three Calculi (p. 159).

Digitized by Google

E. Burgess del. Tuffen West. lith.

W. West. imp.

Digitized by Google

Digitized by Google

complaints of pain; can bear firm pressure on abdomen without flinching.

April 15th.—At midnight, on account of profuse diarrhœa, pulv. cretæ co. cum opio gr. v. were ordered, and to be repeated in four hours, if necessary. She died rather suddenly at half-past four A.M. on the 16th.

Post-mortem examination about thirty hours P.M. Skin of a dusky-red on the arms, and back of trunk and neck. Body moderately nourished. A good deal of ulceration and exudation within the vulva, but not extending into the vagina, which was moderately vascular.

Lungs emphysematous in the upper lobes, congested in the lower. The bronchial tubes much injected, and containing muco-purulent secretion. Heart and liver normal. Spleen pale. Intestinal canal throughout very vascular, but there was no ulceration in any part. About the hepatic curve of the colon there were several small extravasations beneath the mucous membrane. The sigmoid flexure was very pale, the solitary glands there being very apparent, semi-transparent, and about the size of rape-seed.

Right kidney, small, pale, condensed in structure, and studded with minute calculi varying in size from that of a medium-sized pin's-head, downwards. These calculi were composed of phosphate and oxalate of lime. Left kidney externally lobulated; the structure was completely atrophied, and replaced by numerous sacculi, varying in size from that of a small hazel-nut to that of a large pea (Plate VII.). In these sacculi there were numerous minute calculi, resembling in form and composition those found in the right kidney. The calices and pelvis were considerably dilated; so also was the ureter. At the lower end of this canal there were three oval calculi, of about the size and of somewhat the form of a small horsebean. These consisted for the most part of the phosphate and oxalate of lime. The coats of the bladder were much thickened, and the lining membrane injected.

This case is interesting, as showing an unusual tendency to the formation of calculi. This tendency seems to have been due to some constitutional condition. An elder sister, aged about seven years, had a calculus of some size removed from the urethra. The subject of the present case never had any attack of pain in the loins, or other very evident symptoms of calculus.

For about five weeks prior to her admission, she had been under the care of Dr. Priestley, and for a week previously to that under Dr. Clapp. She then complained of pain in the knees and ankles, and general feverishness. There never was any anasarca, and no dropsy

Digitized by Google

followed an attack of scarlatina, which she had about three years previous to her death. Dr. GOODFELLOW, *20th of May*, 1862.

SUB-SECTION II.—GENITAL ORGANS, MALE.

18. *Cancer of the penis.*

The patient, B. A., is a plethoric man, æt. 47, and married. He is accustomed to hard labour, and free living, being by occupation a coachsmith.

About twelve months since, he began to complain of considerable uneasiness in the penis, upon the left side, and immediately behind the glans; in which situation a small nodulated tumour, implicating the deeper structures, whilst the skin moved freely over it, could be distinctly felt. The hardness, size, and pain of this swelling gradually increased with time; and though various sedative applications were tried, their success was but partial.

The pain up to the last three months occurred in paroxysms, at night more particularly, and was at all times referred to the indurated tumour; never to the groin, nor to the posterior portion of the organ. It was of a dull, aching character, never lancinating, nor root-like.

For the last six months, the patient had more or less mucous discharge from the urethra, which became gradually dark and sanious.

Some three weeks ago, I requested Mr. Henry Thompson to see the patient in consultation with me as to the propriety of removing the diseased organ; but as the swelling was extremely limited and small, we decided to wait a little longer, and, in the meantime, to try further soothing applications.

The pain, however, greatly increased, both by day and by night. On the morning of the 12th instant, the patient called on me urging the necessity of operation, and begging me, on account of the excessive pain, to have it, if possible, performed the same day. I accordingly called on Mr. Thompson, who made an appointment for three P.M. Chloroform was administered, and the organ removed in about twenty minutes by means of the écraseur. For the first three minutes afterwards there was no sign of bleeding, then a little oozing commenced, and it was therefore deemed advisable to secure three or four vessels; after which it ceased. Firm evidence was thus given of the efficiency of the écraseur to reduce hæmorrhage, both during and after the operation. The patient progressed most favourably, and on visiting him the morning following, he declared himself absolutely free from pain, and as

Digitized by Google

Digitized by Google

DESCRIPTION OF PLATE VIII.

Illustrating Mr. B. Holt's case of Strictured Urethra, in which the strictures were ruptured after death by the striture dilator (p. 161).

In the figure, the urethra is represented laid open, and the strictures only are seen to have been split by the passage of the instrument.

Digitized by Google

Clerevaux del et lith.

Digitized by Google

Digitized by Google

having passed a better night than he had done for eight months previously. Mr. Thompson examined the tumour, and recognised it as a scirrhous nodule, which had opened by ulceration into the canal of the urethra.

Mr. H. Thompson *for* Dr. Trouncer, *15th of October*, 1861.

---

19. *Case of stricture of the urethra, in which the strictures were ruptured after death by the employment of the stricture dilator.*

J. R. was admitted into the Westminster Hospital under my care in October, 1861. He had been the subject of stricture for eighteen years, and for the last twelve years the bladder had been relieved with increasing difficulty until he could only pass his water in drops. I endeavoured to introduce a No. 1 catheter, but found the impediment too contracted to admit even that size, and he was sent to bed with directions to take castor-oil and remain quiet for a few days. In the meantime he was attacked with fever, and he died on Sunday, November 10th. The friends objecting to a general *post-mortem* examination, I ultimately succeeded in persuading them to permit the urethra to be examined, which I was exceedingly anxious to do, for the purpose of ascertaining what was the precise effect produced by the passage of the dilator and its large tube. With some difficulty I introduced the dilator through two strictures, one within four inches of the meatus, and the second at the bulb, both apparently about half-an-inch long. The sensation was like that I have frequently experienced during life, and the dilator having fairly reached the bladder, I passed the No. 12 tube, split the strictures, and before withdrawing it rotated the dilator in the manner already described. My friend Mr. Heath now removed the penis with a portion of the bladder and rectum; and having laid open the urethra, the two strictures, as is shown in the drawing (Plate VIII.), *and the strictures only*, were found to be split at the under portion of the canal, the rent being directly in the median line and limited to the extent of the obstruction, so far proving what I had already predicted, that it is the dense fibrous structure forming the stricture that gives way and not the healthy urethra. The contiguous structures were uninjured, and the divided mucous membrane gaped to an extent sufficient to permit the passage of a large bougie. Mr. B. Holt, *3rd of December*, 1861.

---

20. *Syphilitic testicle with nodes on the femur and tibia.*

The subject, from whom these specimens were removed, was brought

Digitized by Google

to the anatomical rooms attached to the Charing Cross Hospital. The accompanying certificate stated the age to be thirty years, and the cause of death "ascites."

The muscular system was well developed. Irregular cicatrices were present in either groin, and some inguinal glands were enlarged. The lungs were healthy, quite free from tubercle. Heart normal. Liver and kidneys without disease.

The preparations show well-marked examples of deposits in the testicle associated with extensive nodes of the femur and tibia (Plate IX.); and an interesting point, in connection with them, is the illustration they present of "symmetry of disease;" for, the corresponding bones of the other leg were precisely in the same condition, and the opposite testicle had deposits in its substance corresponding with those in the organ exhibited. In addition to which, the inguinal regions, as I have stated, were in a parallel manner implicated. That, which Mr. Paget* has remarked with respect to the pelvis of a lion in the College Museum (No. 3030) when speaking of the symmetrical disease affecting it, may be appositely introduced here, in regard to the tibiæ and femora of this subject: "multiform as the pattern is in which the new bone is deposited—a pattern more complex and irregular than the spots upon a map—there is not one spot or line on one side which is not represented, as exactly as it would be in a mirror, on the other. The likeness has more than Daguerréotype exactness."

I am unable to state the exact nature of the deposits in the testicles, inasmuch as the organs were removed from the body when decomposition had so far advanced as to render a microscopical inquiry worthless. It will be observed, that there is considerable thickening of the coats of the gland, and the deposits have encroached greatly on the tubuli testis. There do not appear to be any of those more minute depositions which are so commonly to be noticed in cases of tubercular disease of the testis; and the epididymis is unimplicated. It is remarked by Mr. Langston Parker† that "syphilitic sarcocele occurs under two forms; one of chronic or subacute inflammation of the testicle and its coverings; the second, of a specific character, in which a change of structure, or deposit of a specific morbid character takes place in the substance of the testis itself." Mr. E. Canton, *17th of December*, 1861.

* Lectures on Surgical Pathology, Vol. I., p. 18. Lond., 1853.

† The Modern Treatment of Syphilitic Disease. Fourth Edition. *Note*, p. 18. Lond., 1860.

Digitized by Google

Digitized by Google

DESCRIPTION OF PLATE IX.

Illustrating Mr. Canton's case of Syphilitic Testicle, with Nodes on the Femur and Tibia (p. 162).

Fig. 1. Section of testicle with syphilitic deposits.
Fig. 2. Femur with extensive nodes.
Fig. 3. Tibia with ditto.

Digitized by Google

Fig 2.

Fig 1

Fig 3.

Lens Aldous del et lith

Printed by Harrison & Sons, St Martins Lane.

Digitized by Google

Digitized by Google

Digitized by Google

DESCRIPTION OF PLATE X.

To illustrate Mr. Canton's case of Ectopia Vesicæ (p. 163).

Fig. 1. Represents the malformed bladder and penis.

Fig. 2. Represents the pelvis from the same case; and shows the strong ligament stretching across between the widely separated ossa pubis.

Digitized by Google

Fig. 1

Fig. 2.

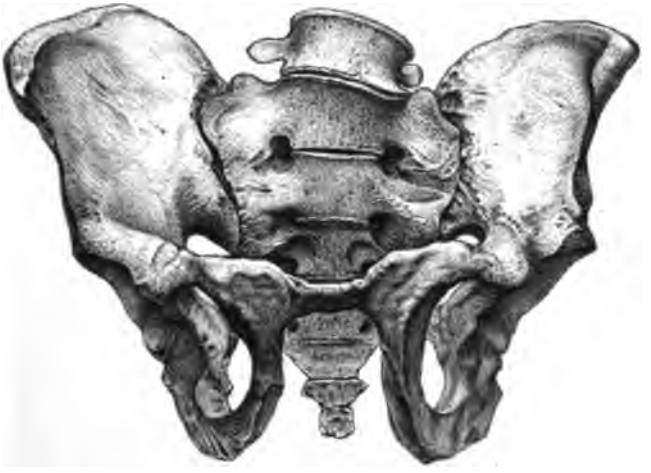

Lewis Aldous delt. et lith

Printed by Harrison & Sons St Martins Lane.

Digitized by Google

Digitized by Google

21. *The genito-urinary organs and pelvis from a case of Ectopia vesicæ.*

The patient from whom these specimens were removed was a man, æt. 24, who was admitted into the Charing Cross Hospital, and placed under the care of Dr. Chowne.

He was six feet in height, and was habited in the dress of a female, which costume, from a mistake made in regard to his sex he had worn since childhood. The name of "Elizabeth" had been conferred on him. The pelvis at the highest and broadest part was thirty-seven inches in circumference, and was flat in proportion to its breadth. The right thigh and leg were rather smaller, weaker and shorter than the left. On the lower part of the abdomen, a little above the pubes, there was absence of the anterior wall of the belly, and of the anterior portion of the bladder, the posterior part of which protruded forwards into the opening, and was everywhere cicatritially united to its margin, except at the lower part. The surface of the projecting portion of the bladder had a circumference of about two inches; it presented a highly vascular mucous membrane of a bright-red colour, and covered with the natural mucous secretion. At some parts the mucous membrane was absent over a small space; this, according to the account of the patient, occurred at different times at different parts, the places being afterwards again supplied with the red mucous covering; the whole of the exposed surface was very tender to the touch. At the lower part of the surface of the bladder the ureters opened; their situations were obvious, although it was difficult to distinguish their exact orifices; on the left side there was a protuberance, or fold of the bladder just over the part, so as to make the opening still more obscure. The apertures were nearly horizontal to each other.

The urine constantly passed in small quantities from the ureters, but, at times, an amount equal to a drachm from each ureter would appear to have been retained, and was forced out when any bodily exertion was made. The penis (Plate X., Fig. 1) occupied its natural situation, and was capable of vascular turgescence, as when fully formed, although in a minor degree. Including the glans, it was about two inches in length, and never at any time exceeded three. There was no more of prepuce than a small fold of skin at the under part of the glans, where it existed in connection with a distinct frænum; the glans were quite exposed. There was no canal constituting an urethra, but a longitudinal depression on the upper side, giving the appearance of a groove; it was covered by a thin, pellucid membrane, and continued to the extremity of the glans. The organ at its termination, therefore, seemed bifid, and

Digitized by Google

when the lateral portions were brought together, and made to meet above, the orifice at the extremity corresponded with that of the meatus. The upper surface of the part rested against the projecting portion of the bladder. Between the most posterior part of the organ, and the lowest part of the projecting portion of the bladder, there was no union by cicatrix, as at the other parts, but the appearance of an undefined, rather deep opening. The scrotum was naturally formed. The testicles were of dissimilar size, the right natural, the left about half the normal volume; both of them, together with the spermatic cords, were more than usually tender on pressure. On either side was a large oblique inguinal hernia. The scrotum and inguinal regions were supplied with hair; it became scanty, however, on each side of the projecting bladder, and finally disappeared above the bladder, and in the line of the linea alba there was none. The anal orifice was close to the scrotum and where the perinæum in well-formed subjects commences; so that a perinæum might be said not to exist.

On either side of that which, under natural circumstances, would be the pubes, a bony projection might be felt by the finger, at which point the osseous structure of the anterior part of the pelvis terminated; the interspace was supplied by strong ligament; this was perceptible both by external and internal examination. There was no vestige of an umbilicus. At one point of union between the parietes of the abdomen and the protruding portion of the bladder, there was a cicatrix, but it did not at all resemble the navel, and there were other similar cicatrices all around at the points of union.

The extent to which the exposed bladder protruded varied very considerably with the position of the person, and in accordance with the amount of straining exercised, from any cause. When the patient had been for some time up, it had three times the volume which it presented when he had been, for a while, reclining on his back. Position exercised the same influence with respect to the herniæ. At the point immediately below the inferior margin of the exposed bladder, as already stated, there was not any cicatrix, but instead, the appearance of a deep, penetrating wound; within this, but near the surface, the vasa deferentia terminated abruptly. This is found to be common in examples which have afforded opportunities of *post-mortem* examination. In the present case, the characteristic secretion which occasionally flowed indicated the proximity and termination of these vessels.

At the expiration of twelve months the patient died of pneumonia, and opportunity being afforded of careful dissection of the malformed parts, I am enabled to offer to the Society the following account of them.

Digitized by Google

Abdominal parietes. Anterior portion, corresponding with the situation of the bladder, wanting, as are likewise absent the anterior wall and cervix of this organ; its posterior portion is fitted into the aperture in the hypogastric region. More than the usual amount of fat exists beneath the peritoneal covering of the protruded part of bladder. Prostate gland wanting. Vesiculæ seminales of about half the natural length, of usual breadth, and inclined towards the wonted situation, but with the peritonæum reflected over them. Vasa deferentia normally placed in regard to the vesiculæ; they pass downwards and inwards to the extent of an inch and a-half from the internal abdominal ring, then passing transversely meet one another without forming an angle at their junction. They are very large at their union with the vesiculæ, and terminate at the point where, under natural circumstances, they would meet the prostate. Ureters natural, and pass through the posterior part of the bladder.

Spermatic arteries of normal size; the right one arises from a subsidiary branch of the internal iliac on the left side, then passes a little to the left of the median line, anterior to the left vas deferens, then above this tube to the abdominal ring of the right side; the left vessel is derived from the right one, at the point where it passes the left vas deferens, and proceeds to the left abdominal ring. *Arteries of vesiculæ seminales.*—The left is derived from the spermatic artery which goes to the right abdominal ring; the right is given off from a small branch of the internal iliac of the left side. *Obturator arteries* spring on each side from the internal epigastric. *Rectum* almost straight, and closely corresponds to the anterior surface of the sacrum. *Sphincter ani* much developed and almost close to the scrotum. *Levator ani* large and thick. *Crura penis, bulb of urethra, and transversalis perinæi muscles* greatly developed.

Herniæ.—The right is an ordinary oblique inguinal; the left is of the congenital variety. The former has the sac passing between the vessels of the spermatic cord, with the vas deferens and its artery lying at the posterior surface, and the other constituents of the cord placed on the anterior and external surface.

Pelvis.—(Plate X., Fig. 2.) Symphysis supplied by a strong ligament, stretching across between the ossa innominata. The height of the pelvis from the highest point of the iliac crest to the lowest of the ischiatic tuberosity is, on the left side, eight inches and three-eighths, and on the right side eight inches and three-quarters; from the brim, anterior to the acetabulum, to the lowest part of the tuberosity of the ischium, on the left side four inches and a-half, right side four inches

Digitized by Google

and one-eighth. Length of sacrum six inches; coccyx one inch and three-quarters. Antero-posterior diameter of brim four inches and three-quarters; transverse six inches and a-half; oblique six inches and a-quarter. Obturator foramina larger than natural, and misshapen. Sacrum measures across, at its junction with the os innominatum, five inches and a-quarter. Instead of being concave, or possessing a hollow throughout, this bone is slightly convex at its upper third, where the first joins the second piece; lower two-thirds slightly curved. It has anteriorly four pair of foramina: the third pair with their grooves, very large and defined. Junction of the different pieces of sacrum incomplete anteriorly.

Slight lateral curvature of lumbar part of spine.

Mr. E. CANTON, *7th of January*, 1862.

---

22. *Cancerous disease of the testicle.*

The specimen exhibited was removed, in Guy's Hospital, by Mr. Durham, from a young German, æt. 19, who had uniformly enjoyed good health, until about six months before admission, at which period he began to suffer from severe pain in the right testicle extending along the cord and across the loins. The pain continued, being very much more severe at intervals, and the testicle rapidly increased in size.

On admission, the patient appeared pale and cachectic, and complained bitterly of intense pain in the testicle, and across the lower part of the abdomen and loins. The testicle was as large as a goose's-egg, very weighty and hard, much harder in some parts than others. Manual examination gave rise to great pain. The abdominal muscles were very tense, and consequently the enlargement of the lumbar glands, which must have existed, could not be felt, although repeated and careful examinations were made. The cord appeared healthy.

The testicle was removed on the 24th of December. The patient experienced but little diminution of pain in the lower part of the abdomen after the operation, but the wound appeared healthy, and was healing favourably. On the 5th of January he died quite suddenly. The testicle removed was evidently cancerous in nature, exuding, when cut, a milky juice, containing nucleoli, nuclei and small nucleated cells. It consisted very largely of fibrous tissue, which gave it the firmness and hardness it presented. In some spots yellow deposits of decayed cancer-tissue were to be observed.

On *post-mortem* examination, no explanation of the sudden death of the patient was afforded; the heart and large vessels were in vain

Digitized by Google

examined for emboli. The lumbar glands were one large mass of soft cancer (in many places almost more than semifluid). One small cancerous deposit was found in the liver; the other organs were apparently healthy. Mr. DURHAM, 21*st of January*, 1862.

---

23. *Cystic disease of the testicle.*

The specimen exhibited was removed by Mr. Cock from a healthy man, æt. 22. The testicle was first observed to be of unnatural size when the patient was five years old, and had gradually increased to such an extent, that for four or five years the patient had been unable to follow his occupation. On two occasions it was tapped, and a small quantity of glairy fluid drawn off, but no perceptible diminution in size resulted. Various modes of treatment were tried ineffectually, and among them strapping, at different periods; but this gave him so much pain that it was very soon discontinued.

The testicle, when removed, was about eight inches long, and five or six inches through at the thickest part. On section it was seen to present a very good example of cystic disease. The cavity of the tunica vaginalis was completely obliterated. Immediately under the tunica albuginea were the modified remains of the tubular structure of the organ spread out in a thin layer. This was very distinct, inasmuch as many portions of tissue, evidently the altered tubuli, could be made out on microscopic examination. The bulk of the tumours consisted of an immense number of cysts, of different sizes and various contents. Some were comparatively large (half-an-inch or more in diameter), and filled with clear glairy, and some with thick dark-coloured, material; other cysts were very small. In the fibrous connective tissue between the cysts, small portions of bony tissue were found in several places. Mr. DURHAM, 21*st of January*, 1862.

---

24. *Epithelial cancer of the mucous membrane of the urethra.*

The following case is important on account of the age of the patient, the part in which the cancerous growth began, and its very rapid progress.

A healthy-looking young man applied to me one day at the Metropolitan Free Hospital, under the impression that he had some venereal disease. His penis was greatly swollen, the prepuce being phymosed by œdema, and there being a dusky, brawn-like induration in the under part of the organ, just behind the glans. This induration had

Digitized by Google

already ulcerated in its centre, and he said that his urine escaped through the opening. Thinking that there must be a phagedenic chancre concealed, I at once slit up the prepuce. No sore, however, existed beneath it. I now freely incised the induration below the urethra, and in so doing cut through a considerable thickness of white curdy material. Although puzzled with the case, at this time no suspicion crossed my mind that the disease was cancer. The man was only twenty-two, and looked in perfect health. He had noticed the swelling only about three weeks before, and had not had the slightest difficulty in micturition for more than a month previously.

The man continued to attend as an out-patient for about a month, and at each visit the granulations presented an appearance more and more suspicious. I now lost sight of him for awhile, but three weeks later he applied for admission into the London Hospital, and again came under my care. There was now no doubt as to the nature of the disease. All his urine passed through the ulcer under his penis. This ulcer was about the size of a halfpenny, and covered over by warty fungating granulations, like exaggerated cauliflower buds. Some glands in both groins were enlarged and hard. I removed a small portion of the edge of the ulcer, and found on microscopical examination the usual elements of epithelial cancer. Most of my surgical colleagues saw the case, and agreed with me in the diagnosis as to its nature. Amputation of the penis was performed in November. Although I removed the organ as low as possible, yet the urethra at the point of section was found distended by soft warty granulations, and I was obliged to dissect out the corpus spongiosum for another inch, in order to get to a healthy part. Having thus removed the urethra so far down into the scrotum, it seemed best to provide for the freedom of micturition by making an opening into the perinæum. This was accordingly done, and a catheter passed by it, and retained in the bladder. The man made a good recovery, and the artificial meatus in the perinæum answered its purpose well. Some of the urine still, however, passed in front. About three months after the operation, a small mass of fungating granulations showed itself in the scar, close to the urethral orifice. In the course of a week, these had increased to the size of a large nut, and pretty exactly resembled those of the original one. These were destroyed by repeated applications of chloride of zinc.

The man is at present, eight months after the operation, in good health. The inguinal glands have diminished in size, but can still be felt.

On laying open the urethra of the amputated part, it was found occu-

Digitized by Google

pied in all parts by soft warty growths. The microscopic structures of epithelial cancer were everywhere abundant and definite.

The tendency to growth rather than ulceration was a peculiar feature in this case, and was probably connected with the early age of the patient. It is perhaps worth mention that the patient's skin seemed to be remarkably prone to the production of ordinary warts, of which he had great numbers on the hands, scrotum and thighs.

Mr. HUTCHINSON, *18th of February*, 1862.

---

25. *Urinary organs from a patient who was the subject of Syme's operation for stricture, between six and seven years ago.*

W. B., æt. between 50 and 60, had been the subject of severe stricture of the urethra for many years, when he came under the care of Mr. Gaye, of Williton, Somerset, in 1851, who, finding it not amenable to dilatation, performed external division on a small grooved-staff, in the manner of Mr. Syme. The patient was much benefited, but after a period of two or three years, the symptoms returned, and Mr. Gaye again cut him in September, 1855. Since this period he has been free from obstruction, and has himself passed from time to time, without difficulty, a No. 10 catheter, to prevent recontraction. He has suffered much from disease of the kidneys and bladder lately, but ever since the last operation, has had no difficulty in passing his water. He died on the 9th of January last.

The kidneys, the bladder, and part of the urethra, are presented for examination.

The bladder is sacculated, and its mucous membrane much diseased. The prostatic urethra is somewhat dilated, and the whole canal exhibits some traces of chronic inflammation. On carefully examining the portion on which the operations were performed, I can find no trace whatever of cicatrix, not even a line sufficiently distinct to indicate the exact situation of the incisions made. Seven small calculi were found in the bladder, composed of phosphate and carbonate of lime.

Mr. HENRY THOMPSON for Mr. GAYE, *6th of May*, 1862.

SUB-SECTION III.—GENITAL ORGANS, FEMALE.

26. *Unilocular ovarian tumour, successfully removed.*

L. H., æt. 21, single, subject to swelling in the abdomen, which commenced two years ago, and has gradually enlarged. She was

Digitized by Google

tapped a year ago, and again in March, 1861, and four gallons of fluid drawn off a second time. Her general health was good. She was recommended to me for the purpose of undergoing ovariotomy by Dr. Gibb, and being a most suitable case for the operation, it was performed on the 19th of September. After making the incision through the walls of the abdomen, the cyst was tapped, and seventeen pints of fluid drawn off; the tumour was withdrawn free from adhesions; and the pedicle, which was not large, was enclosed in a pair of callipers, and retained outside. These were removed in two days, and she made a most excellent recovery. The tumour consisted chiefly of one large cyst, with some smaller cysts at its lower part; evacuated of its fluid contents, it weighed two pounds six ounces. The fluid was examined by Dr. Gibb, who found it of a specific gravity of 1·015, and to contain albumen, gelatine, and chondrine, in nearly equal proportions, without a trace of fibrine; it possessed a clear yellowish colour, with a tinge of green, and felt somewhat unctuous.

Dr. GIBB for Mr. BAKER BROWN, *15th of October*, 1861.

---

27. *Uterus and its appendages, at the catamenial period.*

This specimen is as rare as it is interesting. It consists of the uterus and the appendages of a married woman, æt. 23, who, on account of a quarrel with her husband, after sitting up all night carousing at an "Irish Wake," drowned herself in the Serpentine. Judging from the appearances of the specimen, it may be said that menstruation would have commenced in a very few hours. When in the fresh state, the whole organ was congested and enlarged to about one half more than its usual size. On section, the uterine tissue was found of a rosy tint, and the open mouths of its blood-vessels were distinctly visible. The vagina was also somewhat congested externally, but of the normal colour internally. The mouth of the womb was filled with a white tenacious mucus, while the interior of the organ presented a very peculiar appearance; the mucous membrane, throughout its whole extent, being hypertrophied and of a pink colour, which gradually increased in depth towards the fundus of the organ, at which point it attained to a dark livid colour, and was covered over with a quantity of blood. The blood was in greatest quantity at the mouths of the Fallopian tubes; but neither the congested nor hæmorrhagic state of the mucous membrane extended beyond the openings of the tubes. Their interior was quite white and clean at the uterine extremity, but highly congested, and filled with a milky fluid, towards the fimbriated end.

Digitized by Google

On microscopic examination, this mucous secretion was found to be loaded with ciliated and other epithelium, A, B, C, D. (Woodcut 13.)

WOODCUT 13.

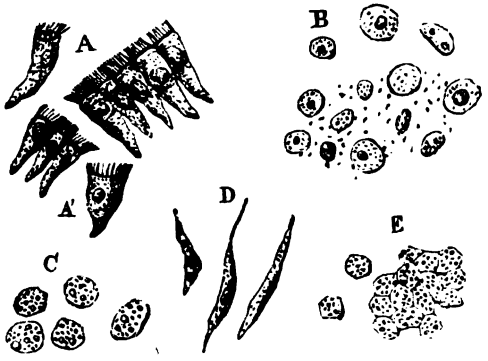

Represents the contents of the Fallopian tubes, &c.

A. Ciliated epithelium from right Fallopian tube, near its fimbriated extremity.
A'. The large cell, with double nucleus, was taken from the left tube.
B. Mucus cells.
C. Cells loaded with fat, from Fallopian tube.
D. Caudate cells found in right Fallopian tube.
E. Cells composing the membrana granulosa of the Graafian vesicle.

The ovaries were enlarged, especially the left one, which contained a Graafian vesicle the size of a marble (three-quarters of an inch in diameter), ready to burst, and which actually burst while being handled.

The vesicle contained a clear, dark, straw-coloured serum, with a few flakes of the membrana granulosa floating in it (E). On the interior of the vesicle were numerous blood-vessels, which gave to it a highly congested appearance. The right ovary also contained a congested Graafian vesicle, but it was not larger than a pea, and still deeply embedded in the tissue of the organ. A well-marked corpus luteum was also present.

The opening of the Fallopian tube at the fimbriated extremity is not at the end of the fingers, but in the palm, and in this case was large enough to admit readily of the passage of a crow-quill.

Remarks.—The above specimen shows—1. The source of the menstrual *blood* to be the fundus of the uterus, not the ovaries or Fallopian tubes.

Digitized by Google

2. The serum from the Graafian vesicle, as well as the milky-coloured mucus from the Fallopian tube, probably form part of the menstrual *fluid*.

3. The dilated condition of the Fallopian tubes, and active state of their mucous membrane at the catamenial period.

4. The enlarged and congested condition of the entire uterus and its appendages at this time. Dr. HARLEY, *5th of November*, 1861.

---

28. *Cancer of the ovaries and stomach.*

This specimen of cancer of the ovaries and stomach was removed from an unmarried female, æt. 34. For four years she had suffered from constipation, relieved only by constant recourse to purgatives. Twelve months since, when I first saw her, she had pain and sickness after taking food; of these symptoms she was relieved, and I saw nothing of her until November last. She was then, and had been for two months, suffering from intense pain in the right lumbar region, darting down the course of the crural nerve to the inside of the thigh, and knee, pain in the left hypochondrium, and a sense of weight at the chest, also constant vomiting of mucus and any food that she took. It was considered at first that gravel in the pelvis of the right kidney was the cause of many of her symptoms. Others considered she was labouring under hysteria, and displacement of the womb. Obstinate constipation suggested an examination *per rectum*, when a tumour was discovered, about the size of an orange, lying between the rectum and uterus. The appearance, about the same time, of five or six nodules in the abdominal walls, decided the diagnosis in favour of cancer, certainly of the stomach, but of what organ or tissue in the pelvis it was not quite clear. The *post-mortem* examination revealed the existence of cancer diffused between the muscular and peritoneal coats of the stomach, throughout nearly their whole extent. The ovaries were enlarged to about the size of oranges, with cancer rather soft in consistency, and in parts considerably softened. The lumbar glands were not affected, nor was there any deposit in the liver.

Mr. J. B. CURGENVEN, *4th of February*, 1862.

---

29. *Ovarian tumours removed by ovariotomy.*

These were specimens of the ovarian cysts and tumours removed by Mr. Spencer Wells during the present session of the Society. Some of them were very large, others smaller, all multilocular, and one solid, or

Digitized by Google

fibrous. Mr. Wells also exhibited the parts concerned in the operation in fatal cases, to show the connection between the uterus, the pedicle, and the cicatrix in the abdominal wall; as well as the uterus and portions of an adhering cyst, in which the pelvic adhesions alone had led him to refuse to perform ovariotomy in a case otherwise favourable. The patient had died of the natural progress of the disease, and after death it had been found almost impossible to separate the adhesions between the cyst, the bladder, the uterus, the rectum, and the opposite ovary. Mr. Wells stated that his success had been proportionally less than in the former session, which he attributed to the fact that he had operated in many cases in which the tumour had been very large, the general health broken down, and the hope of success, therefore, small. Of twelve cases seven had died; while in the last session, of seven cases six recovered. We were now arriving at a knowledge of those conditions which absolutely forbid ovariotomy by showing that recovery after it cannot reasonably be expected. We recognise cases in which the prospects of success and failure are about equal; and those in which the expectation of recovery may be very confidently entertained. Four years ago, when he began to exhibit such specimens in that room, he was told that we need not look too curiously for the precise causes of death after ovariotomy; that the mere fact of such an operation as ovariotomy having been performed was sufficient to account for the death of the patient. Now that stage was gone by; the inquiry into the causes of death had led to improved modes of operating, and to more accurate diagnosis, and the operation was being introduced into France by their distinguished visitor, M. Nélaton, who had witnessed the removal of one of the tumours now before the Society. Mr. Wells added that he had operated on thirty-six patients; two were still in Hospital, nineteen had recovered, and fifteen died. But he could say that very few, indeed, had died in whom the conditions before operation were favourable. Mr. Spencer Wells, *20th of May*, 1862.

VI.—DISEASES, ETC., OF THE OSSEOUS SYSTEM.

1. *Fracture of the os hyoides. Faulty osseous union.*

The specimen was obtained from an adult male subject, about whose history, during life, nothing was known. The bone had been originally fractured at the junction of the right inferior cornu with its body; it had united in a faulty position, causing the cornu to become shorter

Digitized by Google

than its fellow, and projecting inwards at its terminal end. The proximal end of the fractured horn is overlapped by the body of the bone to the extent of nearly a quarter of an inch. The terminal end of the same cornu gives evidence of its having formed a distinct joint surrounded by a proper capsule.

It is quite certain that the fracture must have occurred at least a couple of years before death, in consequence of the appearances presented by the bone (Woodcut 14), together with the formation of a

WOODCUT 14.

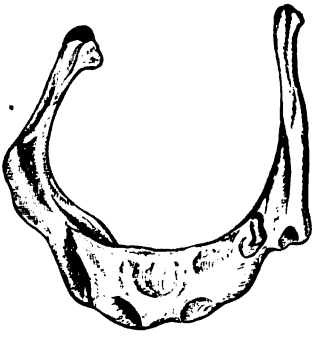

Represents the hyoid bone. The seat of the fracture and subsequent union are distinctly seen.

thyro-hyoid joint. It may be reasonably assumed also, that the fracture originated from manual violence, the chief force being exerted by the pressure of the thumb of the right hand of the person who inflicted the injury.

Of thirteen cases, which I have collected and published in my Essay "On the Diseases and Injuries of the Hyoid Bone," as the result of injury (excluding those arising from hanging), seven occurred from manual violence or throttling, and six from accident. Amongst the former the right horn was broken four times, the left twice, and both horns once. Those arising from accident included three from muscular action, and three from direct injury; the horns were broken in all, excepting the body in one instance, among the latter.

For this very rare and, at present, unique fracture of the hyoid bone, I am indebted to the kindness of Mr. Edwin Canton.

Dr. GIBB, *15th of October*, 1861.

Digitized by Google

2. *Hypertrophy and eburnation of the femur after amputation.*

The specimen was taken from the body of a man, æt. 61, who was admitted into the Royal Free Hospital, on the 12th of July, 1851, having sustained a severe injury to the left leg, from the passage of the wheel of a loaded waggon over it. There was no fracture of the bones, but the result of the injury was the death of the tibia. An attempt was made by Mr. Gay, on the 16th of September, 1851, to save the limb, by the removal of the necrosed portion of the bone. At the time of the operation, however, it was discovered that the entire tibia had perished, and accordingly amputation was performed above the knee, at the lower third of the thigh.

The stump never fairly healed, and for some years the patient was harassed by the frequent recurrence of suppuration within it. Several operations were undertaken, with a view of removing dead bone; and it is stated by the daughter of the patient, that on one occasion, in St. Bartholomew's Hospital, a piece nine inches long was removed; ultimately the remains of the limb became riddled with fistulous openings, leading down to the femur, which was much enlarged, and apparently covered with a quantity of soft plastic material, deposited in the surrounding structures. The patient died from erysipelas of the head and face, in May, 1861, nearly ten years from the date of the amputation, at which period he was under my care.

The stump and remains of the limb were carefully examined. The whole of the thigh seemed to be a solid mass, for the tissues were so blended together, that it was almost impossible to separate one structure from another. The periosteum could, however, be distinguished in some places, where it was immensely thickened, in others it had mostly coalesced with the neighbouring parts. The various sinuses appeared to have closed.

The femur was removed and cleaned; and although the lower third of the bone had been included in the amputated limb, the remaining portion of the bone weighs sixteen ounces (the entire femur, in health, of a strong man, weighs about eighteen ounces). The anterior surface of the bone is expanded fully one half, measuring in circumference six inches, that immediately below the trochanter being four inches; the entire length of the bone is ten inches. A number of osteophytic growths are present, chiefly on the posterior aspect. One resembles a hook, and another forms a distinct bridge. The extremity of the bone is rounded and smooth, and the medullary opening is obliterated. A cloacal opening, the size of a pea, exists on the inner portion of the

Digitized by Google

anterior surface, which communicates with a small abscess in the expanded part of the bone. The head of the femur is denuded to some extent of its cartilage, and the ligamentum teres has been absorbed.

A section of the bone shows that its structure is almost wholly made up of hard, compact substance, in parts resembling ivory. The medullary canal is almost entirely obliterated. A cavity an inch long and half-an-inch wide formed an abscess lined with a distinct pyogenic membrane. The diameter of the bone at its widest part is two inches, the greater part of which is composed of solid, compact bone, of extreme hardness.

The specimen is a good illustration of true hypertrophy of bone, combined with eburnation, most probably taking its origin in inflammation of the periosteum or medullary membrane.

Mr. T. Carr Jackson, *5th of November*, 1861.

---

3. *Case of Colles' fracture of the radius, with fracture of the styloid process of the ulna.*

The case was recent and ununited, the injuries having been inflicted shortly before death. There was some effusion under the periosteum, around the fracture. The fracture of the radius was half-an-inch from the wrist-joint, and oblique from before, upwards and backwards.

The fracture of the ulna separated only the styloid process, which had been torn off, apparently by the strain upon the internal lateral ligament. The specimen was shown as illustrating a combination of fracture with Colles', not usually considered as frequent. The probability of its occurrence has an important bearing upon the method of treatment often employed in Colles' fracture, viz., the use of an adducted hand-splint, which would be objectionable as tending to displace the broken styloid process of the ulna. Two splints, anterior and posterior and straight, should be indicated in such a combination of fractures as in the specimen exhibited. The presence of the fracture of the styloid process would be difficult to determine, when inflammation and swelling had supervened.

A somewhat greater looseness of the articulation, with pain, and perhaps slight crepitus felt on pressure at the inner side of the wrist-joint, would give the surgeon some idea of its presence. In all doubtful cases it would be better to employ the straight splints.

Mr. John Wood, *19th of November*, 1861.

Digitized by Google

4. *Colles' fracture of the radius, with fracture of the styloid process of the ulna.*

The bones were from the left arm of a male subject, æt. 55, in the dissecting-room of the Westminster Hospital.

The radius had been fractured obliquely, the line of junction running from a point half-an-inch from the articular extremity on the inner side to one nearly an inch from the extremity of the styloid process on the outer side of the bone. The fracture must have occurred many years before death, as the bone was so thoroughly smoothed down on the anterior and posterior surfaces, that the fracture would have been unnoticed but for the lateral displacement, which was to the outer side, and caused the lower portion to project to the extent of about half-an-inch. A transverse vertical section through the end of the radius showed that impaction had occurred on the outer side to some extent, the line of compact tissue of the shaft being distinctly traceable in the cancellated structure of the articular extremity.

The styloid process of the ulna had been broken off at the base, and was united by fibrous tissue. The triangular ligament had been found uninjured when the limb was dissected.

Mr. CHRISTOPHER HEATH, *3rd of December*, 1861.

---

5. *Syphilitic induration of the bones of the skull, with deposit on parts of their inner surfaces. Cicatrices in the liver.*

In the *post-mortem* theatre of the London Hospital, one afternoon in October, 1861, my attention was almost accidentally drawn to the body of a man who had died of pneumonia, which had come on whilst he was under treatment for tertiary syphilis. He had been under the care of one of my colleagues, and the chief facts which I obtained as to his illness, were, that he had been admitted with a large cellular node above his right elbow, and that there was a history of constitutional syphilis extending over several years. I at once determined to avail myself of the opportunity of examining his liver and brain. It should be stated that no special symptoms had been noticed, having reference to either of these organs.

Post-mortem examination.—In the lungs there were evidences of extensive broncho-pneumonia, and both pleural sacs contained blood-stained serum with shreds of lymph.

The liver presented on its surface several well-marked cicatrices; one on the front aspect of the right lobe was three inches long and

Digitized by Google

considerably puckered; a section proving that it involved a considerable depth of structure of the organ. The liver-tissue, adjacent to the scar, was indurated and pale.

The pericranium adhered to the calvaria more firmly at some parts than at others. The diploe* between the tables was lost in almost all parts, and in some there was considerable increase in the thickness and density of the bones. The dura mater adhered very closely at some parts, and in tearing it off, shreds of attached membrane were left behind. At these spots the inner surface of the bone was roughened and vascular. At two parts, one on the posterior half of the right parietal, and the other on the left side of the frontal bone, were deposits of new bone, much resembling sawdust stained with blood, and scattered over a surface in each instance about as large as a crownpiece. It was evident that there had been for long chronic inflammatory changes in the bones and their membranous investments.

There was no disease of the brain itself, nor of any of the abdominal viscera, excepting the liver.

Mr. HUTCHINSON, *3rd of December*, 1861.

---

6. *Case of transverse fracture of the patella, in which the fragments were two inches and a-half apart, but united by true ligamentous tissue.*

Mr. Holthouse observed that, in the year 1850, Mr. Wm. Adams directed the attention of the Society to a mode of connection of the fragments of a patella fractured transversely, that had not, up to that time, been recognised. He demonstrated that certain cases which were usually regarded as examples of true ligamentous union, in which the ligament had become elongated, were in reality cases of non-union; the connecting material being no new structure interposed between and uniting together the fractured surfaces, but simply the fascia which passes over the patella, in a thickened condition and having incorporated with it the bursa patellæ. "In true ligamentous union the separation of the fragments is generally from half-an-inch to an inch," and Mr. Adams had not seen seen it exceed one inch and a-half.

The specimen exhibited was removed from a patient of Mr. Holthouse, who died in the Westminster Hospital; but as the lesion was not observed till after death, no history of it could be obtained. A longitudinal section, through the two fragments and their connecting medium, showed the latter to consist of true ligament, two inches and

* The man's age was about thirty-five.

Digitized by Google

a-half in length, uniting the fractured surface of one fragment to that of the other, and enclosed between the fibrous capsule of the joint on the outside and the synovial membrane on the inside. The ligament was strong and thick at its attached extremities, but became somewhat thinner towards its centre. Mr. Holthouse observed, that he considered the specimen worthy of exhibition on three grounds.

1. Because it showed that a separation of the fragments of a broken patella to the above extent is not necessarily a proof of non-ligamentous union.

2. Because it illustrated the extent to which the new material may become elongated; for he supposed it would not be disputed that at one period the fragments must have been, if not in actual contact, at least in much closer apposition than at present, or no new uniting material would have been thrown out.

And lastly, because it demonstrated the importance of not using the limb till the uniting medium had become sufficiently firm to resist the action of the muscles which flex and extend the leg.

Mr. HOLTHOUSE, *21st of January*, 1862.

7. *Chronic thickening (node) of the anterior part of the shaft of each tibia, about the centre of the bone.*

Upon a section, the enlargement was found to consist of firm osseous substance, deposited beneath the periosteum; the bony matter of this deposit was distinctly vascular, while that of the adjacent shaft had its natural appearance.

The medullary canal of the bone presented no unusual appearance.

The periosteum covering the node was not apparently thickened. No history of this case could be obtained, but some scars upon the body seemed to indicate a syphilitic taint.

Mr. PARTRIDGE, *4th of February*, 1862.

8. *Transverse fracture of the sternum, between its junction with the cartilages of the third rib on each side.*

The periosteum was torn across over the fracture on the posterior aspect of the bone, but was uninjured on its cutaneous surface. A very little blood was effused on the surface of the pericardium opposite the fracture. The ninth and tenth ribs on the left side were broken; the former at its angle, and the latter about two inches from its spinal end.

Digitized by Google

This patient died from other severe injuries, produced by falling from a great height, a few hours after the accident.

Mr. PARTRIDGE, *4th of February*, 1862.

9. *Recent comminuted fracture of the lower end of the right radius.*

The bone was broken across on its anterior aspect, one-third of an inch above its lower end, and just below the pronator quadratus muscle. Another oblique fracture had separated the ulnar corner of the lower end of the radius, which gives attachment to the triangular fibro-cartilage. Anteriorly, a third *vertical* fracture extended into the wrist-joint, separating that part of the bone which is grooved for the extensor tendons of the wrist and fingers.

The styloid process of the ulna was also broken off, so that both the radial and the ulnar attachments of the triangular fibro-cartilage of the wrist-joint were separated from their respective bones.

The shaft of the ulna was broken obliquely about three inches below the olecranon. The wrist and lower end of the forearm presented the usual appearance of "Colles'" fracture, except that the hand was less than usually abducted.

The patient was a man, twenty-two years of age, who died almost immediately from other serious injuries produced by a fall from a considerable height. Mr. PARTRIDGE, *4th of February*, 1862.

10. *Cast of a compound incomplete lateral dislocation of the terminal phalanx of the right thumb inwards.*

Of the extreme rareness of this injury, Mr. Holthouse remarked, there could be no doubt, as he could find no similar case upon record.

Malgaine refers to two examples of lateral dislocation of the *fingers*, one recorded by Dugès of a lateral dislocation of the last phalanx of the forefinger outwards, and one by Gogue, of a compound lateral dislocation of the last phalanx of the ring-finger inwards, the distal end of the second phalanx projecting through a transverse wound of the skin on the outer side. Both these injuries occurred in a similar manner, namely, from falls on the hand, the ends of the fingers striking the ground. The patient from whom the cast was taken, met with the accident in the same way. On the 6th of last December, while endeavouring to escape being run over, she fell on her hands, and dislocated the ungual phalanx of the right thumb inwards; a portion of the articular head of the proximal phalanx protruding outwards, through

Digitized by Google

a wound of the integuments. There is also a slight torsion, or axial twist of the wrist inwards. The cast accurately represents the deformity; the thumb is seen to be extended, and its two phalanges, instead of being in line, form an obtuse angle with each other, the apex or convexity of which is outwards, and the concavity inwards or towards the fingers. The prominence which forms the apex of the angle, is a part of the articular head of the first phalanx which projected through the wound.

As regards the movements of the joint, flexion to a slight extent could be made passively but not actively.

Reduction was easily effected by extension with the clove-hitch; the thumb was placed on a splint, the wound closed and sealed up with collodion. So much inflammatory swelling, however, followed, that it became necessary to remove the dressing and the splint; a fœtid discharge issued from the wound, and some days afterwards the deformity recurred. It was at this period I first saw the patient, and having satisfied myself that the protruding bone was really the articular end of the first phalanx, a mould of the parts was kindly made me by Mr. Beadles, our house-surgeon, and the cast exhibited was taken from that mould. Mr. Holthouse, 18*th of February*, 1862.

---

11. *Parts removed in excision of the ankle.*

The portions of bone, I now exhibit to the Society, are the lower ends of the tibia and fibula, and the upper articulating surface of the astragalus, which I removed from a woman, æt. 25, in resecting her ankle-joint, 1st of March, 1862.

The method of operating chosen was that of Moreau; an L-shaped incision being carried behind and below each malleolus, and the lower part of the fibula being dissected away, the foot was dislocated outwards, and thus the lower end of the tibia was made to protrude through the inner wound, and the end sawn off. A narrow-bladed saw was then passed between the anterior and posterior tendons, and the articulating surface of the astragalus removed. The part of this bone left behind was sound, except at the anterior edge of the cut surface, where the gouge was used pretty freely, and extirpated the diseased portion. This operation, though requiring much care, has the great advantage of dividing no important part, except the bones themselves; all the tendons at the back and front are left, and no vascular or nervous branch is severed.

The slice removed from the tibia is tolerably thick, for while operat-

Digitized by Google

ing, three or four points showed the disease to penetrate deeply; that taken from the astragalus is thin, since the articulating portion of the bone had been so much diminished by ulceration. These portions of bone show very extensive disease; all the joint surfaces are extremely rough and carious. The whole of the cartilages and the articular lamellæ having disappeared, the cancelli are laid bare, and out of them crop weak, flabby and fatty granulations.

The patient seemed, up to early the next morning, to be doing very well; then commenced an oozing from the general surface of the wound; menorrhagea came on, although she had only menstruated a week before; a violent shivering supervened, and bleeding of about twelve ounces from the nose, on the fourth day. I mentioned, at the time of showing these specimens, that when anæsthetics were first introduced, and ether was the one employed, it had appeared to me that oozings from the wounds became more frequent than formerly; such consequences are less marked and less constant after chloroform. But in this particular case, there was at the time nothing to show whether the bleeding was due to hæmorrhagic disposition, to intolerance of chloroform, or to other causes; but afterwards it was discovered that the girl was labouring under syphilis, there being in the groin of the non-operated side a bubo that was still open.

Mr. Barwell, *4th of March*, 1862.

---

12. *Separation of the lower epiphysis of the radius.*

This specimen is illustrated in Plate XI., Fig. 1. It consists of the radius of a boy of sixteen, who was admitted into the London Hospital, suffering from various severe injuries sustained in a fall. He died a few days after his admission, and an opportunity then occurred for examining his arm. The dissection was made, and the specimen preserved, by Mr. Fred. Poulden, the dresser of the patient. Unfortunately no notes of the symptoms during life have been kept.

The specimen shows complete detachment of the carpal extremity (epiphysis) of the radius. The detached fragment bears its normal relations with the carpal bones, none of the ligaments having been injured. The line of separation (proximal aspect of the epiphysis) is everywhere covered with cartilage, excepting that, on its dorsal aspect on the inner side, a small portion of bone has been broken from the extremity of the shaft, and carried along with the epiphysis. The lower extremity of the shaft presents no cartilaginous covering, but shows numerous rounded elevations which had fitted into corresponding depressions in

Digitized by Google

Digitized by Google

DESCRIPTION OF PLATE XI.

The Figures illustrate Mr. Hutchinson's cases of Separation of Epiphyses (pp. 182 and 264).

Fig. 1. Lower end of the radius, showing complete detachment of the epiphysis from the shaft. The detached fragment bears its normal relations with the carpal bone.

Fig. 2. Lower extremities of radius and ulna, showing arrest of growth in the former, consequent probably on separation of its epiphysis.

Digitized by Google

Fig. 1.

Fig. 2.

Digitized by Google

Digitized by Google

the cartilage of the epiphysis. Its surface is entire and unbroken, excepting at the back, from which the small fragment of bone above mentioned has been detached. The thickness of the epiphysis, at its ulnar border, is nearly a-quarter of an inch; at its outer border, including the styloid process, it is three-quarters of an inch.

The head of the ulna having been removed, it was, therefore, impossible to state, whether or not the styloid process of that bone, or the triangular ligament connecting it with the radius, had been injured.

In exhibiting this specimen, Mr. Hutchinson remarked, that he had only seen two or three others similar to it. The accident illustrated was, however, one of considerable frequency. It was occasioned by falls forward, striking the palm of the hand forcibly against a hard floor, and was in young persons the analogue of Colles' fracture of the radius in the adult. It was very commonly indeed mistaken for dislocation of the wrist. Not unfrequently great difficulty was experienced in effecting complete reduction, and in afterwards retaining the two portions in accurate apposition. As a rule, the shaft of the radius came forward, the wrist and hand being displaced behind. In one instance, recently under his care in the London Hospital, this displacement was so great, that the lower end of the shaft was in front of the radial artery. Even in cases in which perfect reduction was not effected, the patients usually recovered with very useful arms, and in course of years all trace of deformity might be expected to be removed. In some instances however, the growth of the bone was much interfered with.

Mr. HUTCHINSON, *1st of April*, 1862.

---

13. *Separation of the lower epiphysis of the femur.*

The subject of this case was a child, aged eighteen months, who was run over in the street. He was brought into the London Hospital immediately after the accident, and as the limb was injured beyond all chance of recovery, the artery and vein being torn, Mr. Ward at once performed amputation at the hip-joint. On dissecting the limb afterwards, it was found that the lower epiphysis of the femur was completely detached and carried forwards. There was extensive laceration and detachment of the periosteum. The exposed surface of the epiphysis was covered with cartilage, but that of the shaft showed no cartilage whatever. At the posterior border of the extremity of the shaft corresponding to the outer condyle some small spicula of bone had been broken off, and carried with the epiphysis; but with this exception, the exposed surface was whole and uninjured.

Digitized by Google

Mr. Hutchinson remarked, that although he had seen three or four cases in which this epiphysis was detached in patients who recovered, he had seen but one other dissected specimen in addition to that now exhibited. Mr. HUTCHINSON, *1st of April*, 1862.

---

14. *Rheumatic joint.*

Mr. Barwell exhibited a diseased knee-joint, which was amputated in November, 1857, the history of which is as follows :—

A lady (in 1857), æt. 19, had fourteen years previously, that is when she was five years old, rheumatic fever affecting a large number of her joints. She recovered from this attack without further lesion than lameness and enlargement of the right knee, which instead of getting better, slowly and by irregular exacerbations got worse, she being always lame, but sometimes nearly free from pain, until during the summer of 1857, the joint became so painful that it was determined to amputate the limb. At this time the knee was much swollen and shapeless, the periarticular tissues thick and quaggy, the skin not abnormally white; there was no evidence of excessive fluid in the cavity of the joint; the knee could be only very slightly bent without causing excruciating pain, and it could be rotated abnormally both inwards and outwards; during both these movements, a peculiarly rough and uneven crepitus was felt.

When the limb was removed, Mr. Barwell took it away with him, and examined it the same evening. There was a good deal of healthy fat beneath the skin. When the fibrous tissues around the joint, the sheaths of tendons and the ligaments were exposed, they were found infiltrated or occupied by a soft cretaceous matter in great abundance; in some places, as about and in the internal lateral ligament, the accumulation of this material was so considerable, that the fibres stretched over it, and covered it in, like a cyst.

On first opening the joint, a quantity of thin milk-like fluid containing gritty matter in suspension flowed away. Every structure of the joint itself, except a sac like a thin fascia, and which was probably thickened synovial membrane, had disappeared; cartilages, crucial ligaments, and joint surfaces of bone were all absent. The new bone surfaces were very irregular, having uneven rounded eminences and depressions fitting rudely into one another. The patella was firmly ankylosed high up on the femur.

The whole cavity enclosed in the thickened membrane was filled, and lined, by a white wet chalky substance, in considerable masses, so as to

Digitized by Google

occupy the irregular intervals of the bones, and to fill out the spaces between them and the sac. In some parts, therefore, this material was thicker and more plentiful, in others less so, but nowhere was there any surface uncovered by it in considerable thickness.

In the matter examined microscopically by Mr. Barwell and Professor Quekett, plentiful crystals of urate of soda mixed with an amorphous powder were found. Mr. Barwell concluded, that so marked a distinction between gout and rheumatism, as drawn by some physicians, could not be maintained, since the occurrence of a single case so decidedly rheumatic and so markedly gouty, as this appeared to him to be, was sufficient to overturn the theoretical barrier.

Mr. BARWELL, 1*st of April*, 1862.

Report on the above specimen.—The white matter had a cretaceous appearance and was very hard. Under the microscope it was found to consist of semi-transparent grains, with little or no power of depolarising light. In dilute hydrochloric acid it dissolved with effervescence, and the solution, on the addition of ammonia, gave rise to a copious gelatinous deposit. The residue left by the hydrochloric acid was small in quantity, and gelatinous in character. In a solution of potash the white matter was found to be insoluble, but the gelatinous matter entirely soluble. Further analysis proved that there was an entire absence of urate of soda or uric acid, but that the matter consisted of phosphate and carbonate of lime, united with a little animal matter. No traces of purpurate of ammonium, and no crystals of uric acid could be obtained from it. True gouty deposit occurs in needle-like crystals, which powerfully depolarise light. It also yields rhombs of uric acid, and gives rise to the purple murexide test.

Dr. A. B. GARROD.

Mr. H. THOMPSON, 20*th of May*, 1862.

---

15. *Enchondroma of metacarpal bone and phalanges of little finger.*

Mr. Barwell exhibited the following, sent him by Mr. Williams, of the Norfolk and Norwich Hospital:—

This specimen was removed from the left hand of a healthy-looking girl, æt. 12, who presented herself at the Norfolk and Norwich Hospital, with three tumours on the metacarpal bone and first and second phalanges of the little finger. That on the metacarpal bone was round, hard and smooth, protruded outwards, and was about the size of a filbert. The first phalanx was represented by, or rather expanded

Digitized by Google

into, a circular and elastic tumour; the second phalanx presented the same appearances, but was smaller in size; the last phalanx was free from disease. The swelling on the first phalanx grew most on the radial aspect, and consequently pushed inwards the little finger, separating it widely from the others, its tip being three inches from that of the next finger. The skin covering these growths was not adherent, but was tense and reddened. The patient suffered no pain in them, but occasionally experienced numbness in the end of the finger. The ring-finger possessed a small pea-like projection on the outer side of the second phalanx; and there was also one, as large as a horsebean, on the upper side of the second phalanx of the next or middle finger.

The only history that could be obtained was, that the patient had noticed those growths on the little finger as long as she could remember, and those on the other fingers for about a year.

Amputation of the finger at the junction of its metacarpal with the unciform bone was effected; and on examination after removal, this joint was seen to be perfectly healthy, and about one-third of the structure of the metacarpal bone likewise healthy; the remaining portion was enlarged, and presented the appearances characteristic of cartilaginous formations, and was of a translucent greyish colour. The first and second phalanges had become expanded into globular growths of the same nature and consistence as that which occupied the metacarpal bone; all were enclosed in a dense firm capsule or periosteum; the joints between the growths were healthy and free in their movements.

Under the microscope, portions of the tumours showed a clear matrix, dimly granular, in some places slightly fibrous; embedded in which were seen the cells and nuclei characteristic of cartilage.

Mr. Barwell for Mr. C. Williams, *1st of April*, 1862.

16. *Specimens illustrating the subject of separation of the epiphyses.*

Mr. Holmes exhibited six specimens of fracture, extending in the first five cases through the epiphysal lines (separation of epiphyses), and in the sixth case running so near that level, that the injury was only distinguishable during life from separation of the epiphysis by the distinctness of the crepitus.

The specimens of separation of the epiphyses were from the Museum of St. George's Hospital. The first (Series I., No. 94) showed separation of the lower epiphysis of the radius. The history of the case and

Digitized by Google

age of the patient are unknown. The second (Series I., No. 110) showed a line of fracture traversing the cartilaginous base of the olecranon process of the ulna, in a child two years of age. There was also compound dislocation of the head of the radius. The injury was caused by the passage of a carriage-wheel over the part. The patient died of pyæmia. The third (Series I., No. 121) showed the epiphysal ends of the pubes and ischium separated in the hip-joint, in a case of fracture of the pelvis from the passage of a wheel over the body. The patient was ten years of age. In the fourth case (Series I., No. 138), the patient, a lad sixteen years of age, had fallen from a height of eighty feet. The lower epiphysis of the femur was completely separated from the shaft, and twisted upon itself. There was also a wound of the knee-joint. The thigh was amputated with success. The remaining preparation of separation of the epiphyses (Series I., No. 137), was remarkable on account of the number of epiphyses which had been detached from the shafts of the bones by the same accident. The patient, a lad of eighteen, was leaping from a pier aboard of a steamboat, when his leg became entangled in a rope. There was a compound fracture of the leg at its lower third, and extensive laceration of the skin in the groin, besides the injuries to the bones shown in the preparation. He died, after amputation, from pyæmia. The condyloid epiphysis of the femur, the lower epiphysis of the tibia, and both epiphyses of the fibula, were found separated from the diaphyses. In the injury of the tibia, however, a large fragment of bone had come away with the epiphysal cartilage from the shaft. The preparation had been macerated, and one of the epiphyses of the fibula had been lost; but the line of separation of the others was quite distinct, and could easily be distinguished from the natural separation of the epiphyses, sometimes caused by maceration, by looking at the injury of the tibia. Here it was seen that the epiphyses were so far united to the shaft as to be inseparable in maceration, so that the epiphysal line was well marked on that part of the separated extremity to which a portion of the shaft was adhering.

The sixth preparation was from the body of a child, who died in the Hospital for Sick Children, of chorea, on the 4th of April, 1862, at the age of nine. She had fallen down on the elbow on the 10th of January. On examining the injured limb, four days after the accident, it was found that the joint could be flexed and extended without much pain, and with no sensation of crepitus; but crepitus of a very loud, rough character was obtained by fixing the extreme end of the humerus firmly with the fingers, and moving it on the shaft. Very little, if any,

Digitized by Google

deformity existed. The arm was put up for about a month on a rectangular splint. She had perfectly recovered the use of it before her death. The fracture ran through the shaft of the humerus, about a quarter of an inch above the epiphysal line. The peculiarity of the injury was, that on looking at the bone from behind no irregularity was seen, and it looked as if no fracture had occurred, while, in front, the upper fragment projected beyond the lower by a large irregular prominence, half as thick as the humerus itself. There was, however, no comminution. On stripping the bone, it was seen that its posterior compact wall had become expanded, and it was this expansion which had filled up and obliterated the chasm which would otherwise have been left by the projection of the upper fragment forwards. This expansion, or thickening, was very great at the seat of injury, and it diminished as it was traced upwards, and had nearly disappeared at the level where the humerus had been cut through above, which was about four inches from the elbow. It looked, at first sight, as if periosteal deposit of bone had been laid down upon the original shaft of the humerus, there being a layer of cancellous bone-tissue, gradually increasing in thickness towards the lower end, between two thin tubes of compact bone. But considering the regularity of the expansion; and considering also, that the periosteum was found perfectly natural in appearance, thickness, and adhesion to the bone, Mr. Holmes was rather inclined to refer this expansion of the cancellous wall of the bone to inflammation of its own substance than to effusion between it and the periosteum.

Mr. T. Holmes, *6th of May*, 1862.

---

17. *Cases of acute necrosis, complicated by pyæmia; with remarks.*

The following cases have all come under my observation in the course of the last four years. Four of them were under my own treatment. Three were nominally or actually under the care of one of my colleagues; but of these, one was watched by myself during life, and all were submitted to my pathological inspection.

The acuteness, the danger, and the obscurity of the disease which they illustrate, have for some time impressed me forcibly; and hence, put on the alert, I have been enabled readily to diagnose all the cases of it that have latterly come under my notice; and I have, moreover, learnt that the affection is not only deadly but common.

That the disease is dangerous is shown by the circumstance, that of my seven cases, five died speedily of pyæmia, one sunk, after a time, from the supervention of phthisis, and one only recovered. That

Digitized by Google

it is acute, and rapid in its course, will sufficiently appear from a consideration of the details of the cases. That it is obscure is proved by the fact, that at least three of the cases were originally mistaken for rheumatism, and that its resemblance to this disease is enhanced by its frequent complication with pericarditis; and by the further fact, that two of the cases, although perhaps strictly surgical, were, by surgeons of experience, transferred to the care of their medical colleagues, as cases of fever. I may add, as bearing on this point, that among my *post-mortem* examinations of earlier years, I find several cases which at the time I regarded, on pathological grounds, as cases of pyæmia, and in which the patients were said to have presented symptoms resembling those of typhus, and in which death resulted within a day or two of admission. The cause of the disease was ascertained neither from the history nor from the autopsy; but I have little doubt now, that in some, if not all of them, a more judicious investigation would have revealed, as their origin, suppuration in connection with some deep-seated bone. That the disease is not a rare one, the number of cases which I have met with in a limited period sufficiently attests.

The symptoms of the disease are really simple, and are so well shown in the reports of the appended cases, that I will only very briefly indicate them here. They are, generally, somewhat as follows:—The patient is attacked, not necessarily as the result of accident, with slight rheumatic pain in the course of one of the bones. The symptoms, at first mild, soon become severe; and, according to the situation of the affected bone, redness, swelling, and tenderness manifest themselves more or less distinctly; but generally the bone lies deep, and though the pain may be excessive, the local evidence of serious mischief is necessarily obscure. The aspect of the patient is that of a person suffering from inflammatory fever. Soon, however, in a large proportion of the cases, symptoms bearing a superficial resemblance to those of typhus, typhoid, or even of delirium tremens set in. Pyæmia has become established, and the patient rapidly sinks. In three of the cases that were under my own care, the diseased bones were cut down upon. In one, pyæmia had already taken place, and the patient died of it. In the other two, though periosteal suppuration and necrosis already existed, pyæmia did not ensue. Whether or not this fortunate issue is to be attributed to the timely evacuation of pus I cannot venture to say; but certainly their result justifies that surgical interference which common sense dictates. When pyæmia has been averted, or has not followed upon the primary disease, the affection becomes a purely surgical one; the necrosed portion of bone gradually separates, the

Digitized by Google

process of removal being attended by liability to all those incidents and dangers with which the surgeon is so well acquainted, but which do not concern me here.

Pathology.—It will be observed that I have given, in more than one of the cases, a very minute pathological description. This I have thought it right to do, even at the risk of prolixity, in a volume of *pathological* "Transactions." Moreover, the descriptions are not only very accurate records of the pathology of the disease in question, but they indicate some important points in the pathology of pyæmia itself.

Special.—In most cases the bones were very extensively affected, often the whole shaft of one of the long bones being necrosed. In consequence of the rapid course of the disease, little beyond complete detachment of periosteum, with suppuration around, and sometimes within, the shaft, had generally occurred. In one instance, however, in which the duration of the disease had been unusually long, a small quantity of new bone had already been deposited. In no case were the joint-ends materially affected.

In those cases in which the examination was most carefully conducted, the veins connected with the bones or surrounding tissues were found obstructed by clots, chiefly fibrinous, and generally softening, or even suppurating.

As regards the effects of purulent infection on distant organs, it will be observed in the following cases, as in most cases of pyæmia, that no organ or part of the body can be considered free from liability to their occurrence; and that, generally, the more careful the inspection, the more numerous and wide-spread will be found the purulent depôts and other secondary manifestations of the disease.

In only one, out of the four cases in which the brain was examined, was this organ found materially affected. It contained many small abscesses; and, in addition to these there was, over a limited area, subarachnoid effusion of blood.

In one of my cases the lungs contained sloughy-looking abscesses only, which were both numerous and large; but in all the others, the lumps of disease were scarcely distinguishable from ordinary apoplectic clots. It is true they were covered, where they reached the surface of the lung, by films of false membrane; but the same thing is common in simple pulmonary apoplexy, when the clots have been in existence for any length of time. It is true that some of them were decolorized at the margins; but the same thing occurs in true apoplectic clots. It is true, also, that in one of the cases, the deposits presented patches of softening, and even of suppuration, in their interior; but this also is an

Digitized by Google

event which occasionally happens in the other form of disease. It is true again, that when the small terminal branches of the pulmonary artery were traced with care into these pyæmic clots, they were found filled with adherent fibrine, which was in part softened, and doubtless purulent; but I may again add, that in pulmonary apoplexy the arteries leading to the effusions are almost invariably distended with coagula, which are usually fibrinous. It follows, therefore, that so far as external peculiarities are concerned, there is little real difference between the condition of lung resulting from mitral-valve disease, and that produced, in the majority of cases under consideration, by pyæmia. In both cases, the arteries leading to the diseased patches are blocked up; in both cases there are apoplectic clots; and in both cases there is a liability to softening or to suppuration of the clot, and to its acting, like any other foreign body, as a source of irritation and inflammation to surrounding tissues. The chief distinctions would seem to reside in the greater rapidity with which the latter effects are produced in pyæmia than in true cardiac apoplexy, and in the greater number and smaller size of the clots in the former than in the latter disease. I may remark, that in one of the cases, subpleural extravasations of blood were observed. Pleurisy was invariably present, but was, manifestly, in every case the result merely of extension of inflammation from the subjacent patches of diseased lung-tissue.

Three cases were attended by pericarditis. The effused lymph was of the normal or plastic kind. And the inflammation was in every case, like the pleuritis, manifestly a simple consequence of subjacent heart disease. In four cases the parietes of the heart contained small suppurating cavities, and occasionally extravasations of blood.

Abscess of the liver is, of course, a common sequel of purulent infection, and has been specially observed in connection with the pyæmia consequent on disease of bones. But in none of the appended cases had hepatic suppuration occurred. In three, however, I observed a peculiarity, which I have on many other occasions noticed in pyæmia, and which I regard as something more than accidental. I allude to the presence of irregular, and often large, patches of circumscribed congestion, often associated with, and often surrounding, other patches which are peculiarly pallid. I believe that this condition is precursory to suppuration, and is due to some such impediment or embarrassment of the circulation, as produces in the lungs pyæmic pulmonary apoplexy.

In one of my cases only was the spleen found to contain abscesses. These were small. But in addition to them was observed, in the upper

Digitized by Google

part of the organ, a large fibrinous block, differing little from the ordinary form of block, excepting in being rather more soft and juicy and pink, and in containing several softening or suppurating points.

In every instance the kidneys presented abscesses, sometimes few in number, but generally numerous, and for the most part small. They invariably tended to assume the radial direction, and were surrounded by a greater or lesser degree of congestion. In one case in which the abscesses were in a very early stage, the microscope distinctly proved that the suppuration occupied, as might be supposed, the spaces between the tubes.

General.—The question as to the essential nature of pyæmia has ever been an interesting one, and the opinions of pathologists have necessarily differed. It has, however, generally been accepted that the disease consists primarily in the direct contamination of the blood by pus, which has either been absorbed by some injured vein, or has been secreted by its lining membrane. This is a view which I have never seen good reason to dispute. My clinical acquaintance with the disease is entirely in accordance with it, and my pathological experience, if not quite so conclusive, is certainly in no degree repugnant to it.

It was at one time supposed that the pus was carried from the seat of primary disease to distant organs, and there, by its accumulation, formed the secondary abscesses. This supposition, however, has long been exploded. It has also been imagined that the pus-cells, received into the circulation and arrested in the capillaries, multiplied by subdivision, as cells are supposed to do, and so gradually led to the formation of the so-called purulent depôts. This view again cannot stand the test of accurate pathological investigation. Nevertheless, that the terminal divisions of the arteries leading to the diseased patches, which constitute the secondary phenomena of the disease, do become blocked up, I have no kind of doubt, for I have observed it over and over again in the case of the lung, and have certainly seen it more than once, most distinctly, in the case of the kidney. And that the blocking up precedes the other local changes with which it is associated, is, I think, more than probable; indeed, I regard it as to a great extent proved, not only by the facts observed in pyæmia itself, but by the analogies afforded by a variety of other affections.

The consequences of obstruction of arteries, whether by accumulation of atheromatous deposit, by local arteritis, by spontaneous coagulation of the blood within them, or by emboli, are well understood, but of course vary with the function and structure of the part to which the occluded vessel leads, with the nature of its vascular supply,

Digitized by Google

and with the condition of the patient's constitution. Thus, if the main artery of one of the extremities become obstructed, gangrene is apt to supervene. This is attended, not by local anæmia, but, on the contrary, the small tributary vessels bring in a supply of blood, which, from the want of sufficient *vis a tergo*, accumulates and becomes stagnant; the tissues swell, disintegration takes place, the over-distended capillaries soften and yield, and extravasation of sanguinolent serum and of blood ensues. Further, an abortive kind of inflammation is associated in a greater or less degree with these changes. In obstruction of the cerebral arteries effects not very dissimilar are known to occur. The portion of brain, which has been cut off from its normal vascular supply, softens, becomes congested, may even present extravasation of blood, and sometimes suppurates. In the kidneys, at one time extravasations of blood, at another minute abscesses, occur (in heart disease especially), from similar causes. In the spleen fibrinous blocks are often met with, which are evidently the remains of clots which have been caused by embolism. And I may add, that my own observations decidedly lead me to the conclusion, that ordinary pulmonary clots are produced in much the same way; that the obstruction of the branches of pulmonary artery leading to them, by clots formed *in situ* and in consequence of impeded circulation, precedes the apoplectic effusion; and causes it, first, by leading indirectly to over-accumulation of blood in the capillaries beyond, and second, by impairing nutrition, and thus causing weakness of the tissues, with tendency to laceration of vessels and to extravasation.

Now an examination of the pathological changes, described in the annexed cases, will show that they may be all, or nearly all, satisfactorily explained on the principle which I have just been illustrating; making of course due allowance for the vitiated and depressed state of system in which they arise, which would naturally impress its own character on any processes, normal or abnormal, which may be going on. In the lung we have, first, apoplectic clots, but they have a remarkable tendency to become gangrenous, or to suppurate; in the spleen we have fibrinous blocks, and these present a similar peculiarity; in the liver there seems to be, only in a less degree, a tendency of the same kind; and in the brain, heart, kidneys, and even in the other organs, the changes seem different only in degree and in rapidity from what are frequently observed in cases of "so-called" embolism of the same parts.

But what is the material which obstructs the vessels? That it is to some extent pus conveyed from a distance, and invested by fibrine, I

Digitized by Google

have no doubt. But I scarcely think that this alone furnishes a sufficient explanation, especially of those obstructions which occur beyond the first capillary network through which the contaminated blood has to filter. It is of course easy to understand how (when, for instance, the source of contamination is in the arm) the terminations of the pulmonary artery may be directly obstructed from that source; but it is almost impossible to explain in the same way those cases in which, when the primary disease is still systemic, the lungs wholly escape, while secondary abscesses are formed, it may be abundantly, in the liver, kidneys, and other organs similarly circumstanced. My belief is, that as one of the results of the poisoning of the blood by pus, there is produced in it a peculiar tendency to become stagnant and to coagulate in the small vessels, and especially in the terminal arterial twigs; and that this more depends upon some peculiar property which the blood generally soon acquires, than in the specific influence of any particular form of corpuscle.

In brief, the view which I take of pyæmia is as follows:—Pus is received into the circulation. This, in an analogous way to the poison of typhus and other fevers, affects the blood, and through it the system generally, and thus produces those rapidly fatal symptoms which collectively are termed pyæmia. Contamination from this source has further a peculiar and specific effect on the blood, which is not proportionate in degree to the severity of the attack, and which, occasionally, in the most rapidly fatal cases, may show itself very slightly, or even not at all; this effect is a tendency to coagulation, especially manifested in the terminal arterial twigs. The "so-called" secondary abscesses are, I believe, the results of these obstructions; but are rather, in the first instance, local gangrenes and extravasations than actual abscesses. The corpuscular element of the pus plays only a subordinate part in producing these obstructions; and this part is chiefly mechanical, and is limited by the first capillary barrier.

Let me add, that the first three of the following cases have already been published, but with less copious pathological details, by my friend, Dr. Stone, two or three years since in the "Medical Times and Gazette."

CASE I.—*Necrosis of tibia. Pyæmia. Death.*

T. B., an apprentice, æt, 15, was admitted on the 13th of January, 1858, into a surgeon's ward, but at once transferred by him to the care of the physician. The friends stated that he had been ill for one month. He had, at that time, fallen down-stairs, and injured the left

Digitized by Google

leg. An abscess formed at that spot, from which the discharge was profuse. Subsequently, without definite commencement, feverish symptoms set in; which had continued until his admission.

On admission, the boy had the aspect of one suffering from continued fever. He was partially sensible, answering questions after some hesitation. The face was flushed, the skin hot and dry, the pulse 124. Tongue thickly furred on the dorsum, clean at the edges. Sordes on the teeth. Respiration normal, physical signs healthy.

The left leg was extremely tender. On the front, about the middle of the tibia, was an opening large enough to admit a quill. From this there was profuse, fœtid, purulent discharge. A probe could be passed into the opening, its whole length, upwards and downwards without meeting any resistance. It touched exposed bone the whole distance.

15th.—Has continued in the same state, and been delirious at night. Has had much pain in the left side, and on moving the left arm.

20th.—Sensible, though often delirious at night. Pulse 118, very feeble. Much sordes on teeth. No eruption. Diarrhœa last day or two. Motions profuse, fœtid, black, and passed under him.

23rd.—Much in same state. Diarrhœa continues.

Very little change in the symptoms occurred until his death; which event took place, apparently from exhaustion, on the 26th.

Post-mortem examination.—Height, four feet eleven inches. Weight, four stone. Emaciated. There were two or three small openings over the left shin, whence pus exuded on pressure.

Head.—Calvaria, dura mater, and arachnoid healthy. There was a small quantity of blood effused in the subarachnoid tissue over the posterior lobe of the left cerebral hemisphere, and over the greater part of the cerebellum. But the subarachnoid fluid elsewhere was healthy. There was an abscess about the size of a horsebean in the substance of the right cerebral hemisphere, but close to the surface, and corresponding nearly to the position of the parietal eminence. Three or four more abscesses about the size of tares were discovered in other parts of the brain. They all contained thick, greenish pus, and their parietes were soft and ill-defined. No suppuration was detected in connection with the subarachnoid effusions of blood. The substance of the brain generally was slightly congested, but healthy-looking. There was no apparent disease of its vessels.

Chest.—Pericardium healthy. Heart of usual size. Muscular tissue pale but firm. The left ventricle contained a fibrinous coagulum, which was studded here and there with small opaque masses. Two of the

Digitized by Google

papillary muscles were covered more or less completely by a pretty-firmly adherent layer of false membrane. On cutting into these muscles, a little softened muscular tissue, infiltrated apparently with pus, was discovered immediately beneath the serous membrane. A considerable portion of the entire thickness of the ventricular walls, immediately below the aortic valves, was similarly disorganized. The coagula in the other cavities were partly fibrinous and partly coloured. All the valves were healthy. There were old adhesions in both pleuræ. Here and there, on the surface of the right lung, was an exceedingly thin film of lymph. The left lung was crepitant for the most part, though œdematous. In the outer part of its upper lobe, however, near the surface, was a patch of pulmonary apoplexy about as large as a filbert, in the centre of which were two or three suppurating points, from the size of a tare to that of a grain of wheat. In the upper part of the right lung was a mass of diseased tissue about two cubic inches in bulk. The lower part of this formed an abruptly marginated cavity, filled with a brick-red pulpy material, which was adherent to the parietes, and consisted evidently of disintegrated lung tissue, infiltrated with pus. The remainder of the diseased mass was constituted, partly of carnified, partly of distinctly apoplectic tissue, studded with yellowish spots, from the size of a pea downwards, in which suppuration was going on. A similar mass, about a cubic inch in bulk, was observed at the lower part of the lower lobe. And close to the surface of the anterior portion of the upper lobe was an abscess as large as a hazel-nut. The remainder of the lung was œdematous, and somewhat congested. Bronchial tubes healthy. Bronchial glands large, and containing much firm, cheesy, tubercular deposit.

Abdomen.—Peritonæum for the most part healthy. The liver was of ordinary size, and perfectly healthy throughout; but a small portion of its surface which was in relation with the right kidney took part in the formation of the walls of an abscess. The upper part of the spleen was attached by soft and recent adhesions to the diaphragm. On removing the organ it was found to be of usual size. The adherent portion formed a patch, about an inch in vertical and two inches in lateral admeasurement. This was of a pale-yellow colour, with a somewhat soft and flocculent surface; and its margins formed an abrupt elevated rim. The actual adhesion appeared to have been limited to the margins, the surface having formed a portion of the parietes of a small abscess. On cutting into the spleen at this part, the superficial patch was found to correspond to a mass of diseased tissue between one and two cubic inches in bulk. This mass was abruptly marginated; was somewhat

Digitized by Google

softer, more elastic, and more juicy than ordinary fibrinous blocks; had generally a buff-colour, slightly tinted with pink, and in several places contained cavities filled by a pulpy puriform material. Several yellow masses from the size of a pea downwards were discovered on different parts of the surface, and on section were found to be small abscesses. The spleen-tissue generally was dark-coloured and soft, but not unhealthy. Pancreas, stomach, and small intestines healthy. In the cæcum were a few small ulcers evidently of recent formation, somewhat irregular in shape, with slightly shreddy surfaces, and unthickened edges. The mucous membrane of the colon appeared thick and rough, but it was not congested, nor was the roughness due to lymph. The left kidney was of usual size. On removing its capsule, the surface was found to be pretty thickly, but irregularly, studded with roundish, yellow projecting points from the size of a tare downwards, surrounded by a more or less broad rim of congestion. From many of these, drops of pus escaped. On making a section of the organ, numerous small abscesses were discovered both in the cortex and in the medulla; many of which, and especially those in the medulla, were elongated in the radial direction. The kidney-substance between the abscesses was pale, and healthy-looking. The capsule of the right kidney was separated, in several situations, to a great extent from the surface of the organ, by accumulations of pus. One of these abscesses contained about an ounce of pus. On incising the kidney, its entire substance was found to be thickly studded with abscesses which were much larger and more numerous than those in the opposite organ—many of them being as large as a marble. Supra-renal capsules, testicles, aorta and other large vessels, healthy.

Leg.—On laying open the left leg, almost the whole of the shaft of the tibia was found denuded and surrounded by an elongated annular cavity, containing a large quantity of greenish or blackish fœtid pus. The shaft, except in two or three situations where it still adhered to surrounding tissues, was perfectly bare of periosteum. It had for the most part a whitish aspect, and presented here and there a slightly worm-eaten appearance. The epiphyses appeared to be healthy, or nearly so, and were surrounded by periosteum. The knee and ankle-joints were healthy. On making a longitudinal section of the shaft, the upper and lower thirds of its cancellous structure appeared to be infiltrated by a yellowish material which looked like softened fibrine. The infiltration was not uniform, but extended in irregular bands, which were surrounded, and separated from one another, by highly congested tissue. The central third of the cancellous structure had a healthy appearance.

Digitized by Google

There was no trace of the deposit of new bone around or in connection with the necrosed shaft. There can be no doubt, that the affection of the shaft had been acute, and the necrosis of it complete. The veins of the leg were not traced, but those of the thigh (and their contents) were healthy.

Microscopic examination.—The fluid infiltrating the softened portions of the heart was found to be true pus. The muscular fibres from the parts were broken into fragments, had lost all traces of transverse marking, and were studded thickly with minute oily molecules. That which looked like false membrane on the surface of the musculi papillares was discovered to be, rather, a thickening and infiltration of the endocardium of the part, since it could not be detached independently of that membrane. Its microscopic characters were somewhat indefinite.

The deposit in the spleen consisted chiefly of cells having much resemblance to pus, but they were somewhat more granular, and less regular as to size, and were not distinctly affected by acetic acid.

The abscesses in the kidneys contained pure pus. In some situations, this could be distinctly seen to occupy the intertubular spaces, which were much dilated; while the tubes, still in a healthy condition, traversed the diseased patches. In some instances it was thought that the tubes themselves contained pus-cells. This was a point, however, difficult of accurate investigation, since in all cases where an actual abscess existed the tissues were too much disorganized to admit of satisfactory results.

The deposit in the interior of the bone was looked at, but owing to the amount of oil present, it was not easy to ascertain its microscopic elements. Here and there, however, enveloped in oil, or otherwise masked by it, indistinct outlines of cells could be seen, which were supposed to be pus or exudation corpuscles.

CASE II.—*Acute necrosis of femur. Pyæmia. Death.*

M. H., a maidservant, æt. 29, was admitted into St. Thomas's Hospital, on the 24th of November, 1858. She was a robust woman, above the middle height, and stated she was suffering from rheumatism. It appeared that she had been out of health for a fortnight, and that before that time she had been suffering from mental anxiety and privation. She had, however, been able to do her duties as household servant until a week before admission. She had at first complained of severe pain in the right thigh, which had soon after become swelled and

Digitized by Google

tender. Two days before admission there had been some aggravation of the symptoms, without any change in character.

When taken in she had the aspect of a person suffering from acute rheumatism with considerable febrile disturbance. She was quite sensible, and complained most of pain in the right thigh. On examination, this was found to be swelled and puffy, of a doughy feel, and very tender. It could not be discovered whether the knee-joint was implicated, from the great œdema and tenderness. There was no circumscribed redness or tenderness at any part.

25th.—Much worse. After a severe rigor she became violently delirious, throwing the bedclothes off her, and making much noise.

26th.—The delirium this morning gave way to signs of collapse; these were accompanied by sudden and violent bronchitic symptoms. Moist crepitation, both large and small, became audible in all parts of the chest, and could be distinctly heard when standing at the bedside. The face became livid and suffused; the respiration very rapid; the pulse insensible at the wrist. She was able to speak sensibly and firmly until a few minutes before her death, which took place at noon on this day.

Post-mortem examination.—In good condition. Over the buttocks, and chiefly on the left side, was a large discoloured patch—in several places black—which, on section, was found to be very superficial, and was evidently the commencement of a large bed-sore.

Head.—Calvaria and dura mater healthy. The brain was a good deal congested, and there was, perhaps, a slight increase of serum on the surface and in the ventricles; but it was otherwise healthy.

Chest.—Pericardium and heart healthy. The latter appeared large, and weighed twelve ounces. Its right side contained large fibrinous coagula. The pleuræ were for the most part healthy, and free from old adhesions; but the surface of both lungs presented two or three largish, exceedingly thin, and scarcely visible patches of recently deposited lymph; each of which was found to radiate from a central spot, in which the subjacent lung-structure was elevated, and of a black colour. On section, these black spots were found to be distinct apoplectic clots, from the size of half a marble downwards. There were half-a-dozen of such clots in the left lung, and three or four in the right. All of them were clearly and wholly apoplectic; none were of the nature of an abscess, although one or two presented an imperfect buff-coloured margin. In addition to these clots, there were observed at the base of the left lung several black elevated patches, of irregular shape, and about a quarter of an inch in diameter, which were due to

Digitized by Google

extravasation of blood into the subpleural tissue. The lungs were generally congested and œdematous, but crepitant. The bronchial tubes contained a good deal of secretion, and were somewhat congested. Larynx and trachea healthy.

Abdomen.—Peritonæum healthy. The liver was of usual size, and for the most part, healthy. The surface presented several irregularly mottled patches of various sizes, which presented a distinct port-wine hue, together with several tolerably well-defined tracts of remarkable pallor. The congested condition was found to be quite superficial; the pallid condition to extend for some little distance into the substance of the organ. Spleen, healthy. Stomach and intestines, pancreas and supra-renal capsules, healthy. The kidneys were for the most part quite healthy; but the right one was very large, and it presented in the cortex a group of indistinct abscesses, altogether about as large as a hazel-nut. This suppurating patch formed an irregular cylinder, consisting of a number of smaller imperfect cylinders of suppuration separated from one another, and surrounded, by congested margins. On separating the capsule from the diseased tract, the small abscesses abutting on the surface were laid open. The uterus was healthy, with the exception that its cavity was filled with grumous fluid. One of the ovaries presented a single serous cyst, as large as a walnut. Aorta healthy.

The right thigh was unusually plump, and on cutting into it down to the bone, a large quantity of thin pus escaped, and the femur to a great extent was found denuded. The parts were removed, and submitted to a careful examination. It was then found that the greater part of the lower two-thirds of the shaft of the bone was bare and bathed in pus, and that the muscular tissue for some little distance around was softened and infiltrated with pus; and further, that many of the veins in the muscles were distended with coagulum, partly recent, partly buff-coloured and adherent, and contained also, in many places, thick, sanious, puriform fluid. Here and there, shreds of tissue still adhered to the surface of the diseased bone; and in one oval patch, about two inches long and an inch broad, was a softish granular deposit of recent bone. This was thin at the margins, increased in thickness towards the centre, and at the latter point presented a circular orifice about a quarter of an inch in diameter, the bottom of which was formed by denuded shaft. The joints and the joint-ends of the bone were healthy. On making a vertical section of the shaft, the greater part of the medullary cavity was found to be occupied by soft lymph, puriform fluid, and coagulum. The large vessels of the thigh, and their contents, appeared healthy.

Digitized by Google

CASE III.—*Acute necrosis of radius. Pyæmia. Death.*

M. A. A., a girl, æt. 15, was admitted into St. Thomas's Hospital, on the 18th of December, 1858. She was a well-developed, tolerably stout girl. She stated that she had enjoyed good health previous to her present illness. She had never had acute rheumatism. She had been a servant in a good situation, and had not suffered privation. The catamenia had recently appeared. Five days before admission (December 13th), she began to suffer from pain in the left forearm, especially at its posterior aspect. Some swelling appeared in the course of the day. But her general health does not appear to have been materially affected until the 14th. She then had a severe rigor, accompanied by vomiting, headach, pain in the chest, and cough. She took to her bed, and became rapidly worse, complaining of the same symptoms, with delirium for the last night or two.

On admission, the general aspect was that of a case of acute rheumatism, with cardiac complication. As such it was taken in. The face was anxious and pale; her manner appeared confused and only partially conscious. Pulse 130, very feeble. Respirations 44 per minute. Skin cool. Some ineffectual cough, and apparent inability to expectorate. On examining the chest loud rhonchus, with large moist crepitation, was audible in every part, and could also be felt as a thrill conveyed to the fingers. In an interval of respiration, the heart could be heard beating feebly, but with normal sound. There was no abnormal dulness, and no great tenderness of surface. The left arm and forearm were swelled and tense, rather red and tender, though not acutely so. All the articular movements were easily performed, and without pain. Neither the wrist nor elbow-joints bore traces of rheumatic inflammation. The swelling was greatest in the middle and upper thirds of the forearm, of a doughy feel, giving no evidence of fluctuation. The hand was not at all implicated.

She sank the same evening, without alteration of symptoms.

Dr. Stone, then Registrar of the Hospital, and whose notes of the case I have quoted, asked me, in the course of the day, to examine the patient with him, and the opinion which we both formed was confirmed by the *post-mortem* inspection.

Post-mortem examination.—In good condition. Height, four feet eight inches. Weight, five stone seven pounds. The left arm, from the insertion of the deltoid to the wrist, was much swollen, somewhat hard, and presented patches of redness. On laying it open, its tissue was found generally healthy; but most of its veins—many of the super-

Digitized by Google

ficial veins, and the majority of the muscular branches—were found filled with imperfectly-formed clots and distinct purulent fluid. The lower third of the left radius, exclusive of the epiphysis, was bare in nearly the whole of its extent, and surrounded by thick pus, which infiltrated the neighbouring muscular and cellular tissues. The wrist-joint and joint-end of the radius were perfectly healthy. On making a section of the bone, its interior was found to be quite healthy-looking. The ulna was healthy.

Head.—Both the surface and the substance of the brain were considerably congested; but there were no other indications of disease in these parts.

Chest.—Both lungs were covered by a layer of recent lymph, by which they were slightly attached to the parietes. The lymph was somewhat unequally deposited, and was considerably more abundant on the left than on the right side. The lungs were of ordinary size, and, for the most part, crepitant. They presented, irregularly scattered from apex to base, numerous patches of apoplexy, from the size of a filbert downwards. Some of these were a little decolorized at the margins; and the small branches of the pulmonary artery connected with most, if not all, of them were filled to distention with adherent decolorized clots, mixed in some cases with a little pus-like fluid. A few distinct abscesses, from the size of a horsebean downwards, were scattered here and there. The bronchial tubes contained a large quantity of frothy fluid. The pericardium was lined by recent lymph. It was more abundant on the surface of the heart than on the parietal layer, and was chiefly aggregated on the left side. The heart was of ordinary size, and firmly contracted. Its surface (beneath the false membrane) presented numerous spotty and mottled patches of intense congestion and extravasation. On making sections of the organ, many abscesses, from the size of a pea downwards, in various stages of formation were found in the substance of the muscular parietes. The valves were healthy. The cavities contained a little partially-decolorized coagulum.

Abdomen.—Peritonæum healthy. Liver of usual size, for the most part healthy. Its surface presented several largish and irregular pallid patches surrounded by a broad irregular congested halo. On section, these patches were found to correspond to blocks of tissue, presenting similar characters all round, and extending some little distance into the organ. Spleen soft. Pancreas, stomach, intestines, and supra-renal capsules healthy. The kidneys presented a considerable number of minute abscesses, surrounded by congestion, but were otherwise healthy.

Digitized by Google

The lining membrane of the uterus was congested, and the cavity contained a little bloody secretion, but the organ was healthy in other respects. Aorta and other large vessels healthy.

Some of the pus-like fluid in the pulmonary vessels was examined microscopically, and found to consist chiefly of distinct pus-cells; but in some instances, of granular matter and débris of coagulated fibrine only.

CASE IV. *Acute necrosis of femur. Pyæmia. Death.*

S. J. H., a boy, æt. 13, employed at a china-warehouse, presented himself among my out-patients at St. Thomas's Hospital, on the 29th of July, 1859. He complained of pain in the right thigh, knee, and hip. He could walk, but seemed a little lame. There was no visible swelling or redness in the thigh or in the joints, and there was no rheumatic affection of any other part of the body. There was little or no constitutional disturbance; but some constipation of the bowels. The pains had come on four days before without obvious cause. He had always enjoyed good health previously, and had never suffered from rheumatism. Under the impression that this affection was a rheumatic one, he was ordered a mixture containing a little hyoscyamus, colchicum, and iodide of potassium, and a purge of rhubarb and calomel.

On the morning of the 2nd of August (or four days after I had first seen him), he was brought again to me at the Hospital, in a moribund condition. He was ordered to be warded, but died before he could be removed from the out-patients' room.

I learnt, that the pain in the thigh had gradually increased in severity, and had become so great, that for the last two days he had had no sleep, and had been constantly moaning; that he had continued to get up however, and even to dress himself, up to the morning previous to his death; that he had been perfectly sensible throughout; that he had not been remarkably feverish, but had entirely lost his appetite; and that on the day before he died, he complained of much pain in the region of the heart. His mother added, that she had observed a great change in him since July 31st.

Post-mortem examination.—Of usual stature, in good condition.

Head.—Brain and its membranes quite healthy.

Chest.—The left side of the heart was covered by a thin granular layer of recent lymph; but the general pericardial surface was healthy; and the cavity contained no appreciable amount of fluid. The heart

Digitized by Google

was for the most part healthy, its muscular tissue firm and contracted, its cavities containing a little fibrinous clot. The muscular parietes of its left side, in a superficial extent of rather more than a square inch, were deeply and irregularly congested, somewhat softened, and contained two or three distinct cavities, from the size of a pea downwards, filled with pulpy purulent contents. The pleuræ were free from old adhesions and from serous effusion, but the surface of both lungs presented here and there thin granular patches of recent lymph. The lungs were studded pretty thickly with black-looking apoplectic patches, from the size of a pea to that of a walnut. Most of these were solid, and had all the usual characters of well-marked sanguineous effusions; others, however, were still more or less crepitant, but none suppurating or even pneumonic. The lung-tissue intervening between them was crepitant and tolerably healthy. There were no abscesses. Larynx, trachea, and bronchial tubes healthy. All the branches of pulmonary artery leading to, or connected with, the larger apoplectic masses were filled with coagulum, which, in many instances, was fibrinous, and in some distinctly contained pus.

Abdomen.—Peritonæum healthy. Liver of usual size, and for the most part healthy. It presented, however, a considerable number of pale-yellowish patches of various sizes and shapes, some of which were limited by an irregular congested margin. Spleen healthy. Stomach and intestines healthy. In the small intestine was a lumbricus. The kidneys were for the most part healthy; but were found to contain, chiefly in the cortex, a considerable number of small abscesses, extending as usual in the radial direction. Pancreas, supra-renal capsules, aorta, vena cava, and other organs healthy.

The right thigh was thicker than the left, and on cutting into it down to the bone, the upper third of the shaft of the femur was found bare and bathed in brick-red pus, which was collected between the bone and the detached periosteum. The diseased portion of bone was perfectly smooth, it was irregularly limited below, and bounded above by the capsule of the hip-joint. The inflammation appeared, however, just to have involved the edges of the cartilage, for they could be most readily detached from the subjacent bone-tissue. The tendons and fasciæ were still adherent to the linea aspera. Some of the adjacent muscles on the outer side of the thigh, to the extent of two or three cubic inches, were infiltrated with pus, and contained suppurating cavities. Many of the veins leading from the diseased tissues contained adherent clots, together with puriform fluid. On vertical section of the denuded bone, its can-

Digitized by Google

cellous structure, though generally healthy, presented here and there distinct accumulations of pus.

CASE V.—*Acute necrosis of femur, and of pterygoid process. Pyæmia. Death.*

T. S., a little boy, æt. 5½, was admitted on the 29th of March, 1862, into a surgeon's ward. He seems to have enjoyed perfectly good health until twelve hours before admission. At that time pain came on in the right thigh. The mother, who was a charwoman, and from home the greater part of the day, fancied the pain had been produced by an accident, but there was no local or other evidence of such being the fact. After admission, the pain in the thigh continued; and the constitutional symptoms became so severe that, under the impression that the child was suffering from typhus, which was at that time prevailing, he was transferred to a medical ward, and placed under my care on the 2nd of April. I saw him first on the 3rd. He was then perfectly sensible, but had passed a very restless, sleepless night. He was fretful, and complained of pain in the right thigh. The face was flushed; the skin hot and dry, and presenting, chiefly on the abdomen, a few sudamina with congested margins, which had been mistaken for the commencement of the typhous rash. No jaundice. The tongue was moist, and slightly furred. He had no appetite, but no nausea, nor did he seem very thirsty. Bowels not loose. Pulse very rapid, but regular. No thoracic symptoms. The right thigh was evidently larger than the left, a little harder, and very tender on deep pressure; there was also a little pain on moving the left wrist, and some pain and swelling in the situation of the left parotid, which had been coming on since the 1st.

During the next day or two there was little change in his symptoms; but certainly no real improvement. The pain disappeared from the wrist; but the thigh, if it did not increase in size, did not, on the other hand, diminish, and continued as painful as ever; the swelling in the parotid region became larger, and harder, and very painful; but it neither affected the breathing nor the power of swallowing. I got Mr. Sydney Jones to see the child with me on the 4th, and again on the morning of the 5th. On the latter occasion it was thought advisable to make an exploratory operation. A bistoury was passed vertically into the thigh, at about the middle of its outer side, and down to the bone. At first, no pus came away; but by alternating the use of the bistoury with that of the finger, inserted into the wound, and the director,

Digitized by Google

soon a large gush of thick pus escaped. The abscess was ascertained to have been situated between the periosteum and the bone, and chiefly along the inner aspect of the femur. Some abatement of pain followed the operation; but his general symptoms continued much as before, and he slept no better that night than he had done previously.

On the 6th he was evidently worse. He was excessively prostrate; the face pale, instead of flushed, as it had been; the skin still dry, without trace of rash or jaundice; the tongue much furred, and now dry. The pulse was regular, but feeble, and 160. The breathing was rapid, and there was frequent hacking cough, but the chest was resonant. The wound in the thigh discharged but little. The parotid region had become more tense and large. It was still extremely tender. There was no fluctuation. The mouth could only be opened to a slight extent. Mr. S. Jones saw the patient with me again to-day; and as we felt confident that there was the same kind of disease, in connection with the bones of this region, as there was of the femur, it was decided to make the attempt to evacuate the pus. Three punctures were made within a short distance of one another, down to the ascending ramus of the lower jaw, but not a trace of matter followed.

From this time he lay in almost a moribund condition; he had no sleep, and was restless and fretful, but sensible to the last. The skin continued dry; the pulse very rapid, and almost imperceptible, but regular. The tongue got dryer. The cough increased, and became incessant and loose; but whatever expectoration there was, was swallowed. The child was so prostrate, and the case so hopeless, and at the same time so clear, that no further careful examination of the chest was made. On the 8th, a considerable quantity of pus suddenly discharged itself into the mouth, manifestly from the region which we had attempted to relieve by operation. About the same time, also, thick pus began to come away from the punctures that had been made. Death took place on the 9th.

Post-mortem examination.—Body of average size; little emaciated. The wounds made in operation patent, and allowing escape of pus. *Head* not examined. *Chest.*—Right pleura attached, in great part of its extent, by old adhesions. The surface of both lungs was studded with patches of recent lymph. Both lungs presented numerous abscesses, and groups of abscesses, from the size of a horse-chestnut downwards. All these had a gangrenous appearance, were surrounded by abrupt margins, and contained a dirty-greenish, purulent pulp. There were no pulmonary clots. The lung-tissue generally was somewhat congested. The bronchial tubes contained a good deal

Digitized by Google

of mucus. The bronchial glands were enlarged, and converted into masses of cheesy tubercle. The whole surface of the pericardium was covered by a layer of reticulated, adherent, recently-deposited lymph. There was only a trace of serum. The heart was of normal size. Its muscular parietes presented a considerable number of abscesses, from the size of a pea downwards. They were of irregular shape, with ill-defined parietes; and their cavities contained, in addition to pus, abundant débris of muscular tissue. Several of them projected externally, forming small prominent tumours. The valves were healthy. The right ventricle contained a fibrinous clot, which was prolonged, in a cylindrical form, into the pulmonary artery. It was neither adherent nor softened.

Abdomen.—Peritonæum healthy. Liver healthy, but presenting numerous tracts, in which the tissue was, by contrast, exceedingly pale. Spleen, pancreas, stomach and intestines, and supra-renal capsules, healthy. The kidneys were of ordinary size, and contained a considerable number of small abscesses, taking, as usual, a direction perpendicular to the surface.

On cutting into the right thigh, almost the whole shaft of the femur was found bare, and bathed in thick fœtid pus, which was accumulated chiefly between the periosteum and the bone. The cancellous texture likewise contained purulent fluid and fibrinous exudation. The joints were healthy. On careful examination of the affected side of the face and neck, it was found that there was a considerable amount of thick ill-smelling pus, around and behind the ascending ramus of the lower jaw. But the lower jaw itself and the joint were quite healthy. The pterygoid process, however, was wholly denuded. There is little doubt that the latter portion of bone had been the centre of mischief; and that this was the reason why the punctures which had been made before death had not been immediately successful. The tongue was found to be remarkably dry; the larynx unaffected.

CASE VI.—*Acute Necrosis of tibia. Death from phthisis at the end of five months.*

R. W., a youth, æt. 15, engaged in an iron-foundry, was admitted into St. Thomas's Hospital on the 4th of August, 1859. He had been attacked five days previously with pain in the left knee, and supposed it to be the effects of a cold caught after exposure to the heat of a furnace. Had never had any similar affection before.

On admission, the left knee was red, tender, and swollen. He was

Digitized by Google

very feverish; the tongue was coated with a thick yellow fur; there was profuse perspiration; the pulse was upwards of 100 in the minute; the bowels were regular. The case was supposed to be one of acute rheumatism, and treated accordingly.

On the 7th he came under my care. His state was then as nearly as possible that which has just been described. He had had, however, since his admission, pain in several of his finger-joints. That night he slept badly, rambled slightly, and had a severe shivering fit. On the next day (the 8th), the symptoms were little changed; his pulse was rapid; his tongue coated; his face pale; his eyes sunken and with a dark rim. On careful examination of the knee, it was observed that although there was considerable swelling and vivid redness over the greater part of it, these conditions were most marked from the patella, four or five inches downwards, in which region also the tenderness was most pronounced. I at once got Mr. Simon to see the patient with me; who, agreeing with me in the opinion which had induced me to call in his assistance, made an incision three or four inches long over the upper part of the tibia and down to the bone. A large quantity of pus escaped from beneath the periosteum, and the upper part of the shaft of the tibia was found completely denuded. The joint was sound. He was much relieved by the operation.

On the 9th he seemed better, he was more free from pain, his pulse was less rapid, his tongue cleaner; but he had slept badly, and rambled a little, his eyes seemed more sunken, and the wound looked sloughy. I looked narrowly to-day (as I had done previously, and continued to do for some days to come), for any symptoms that might indicate pyæmia, but failed to detect any. About the 11th, he complained of some pain in breathing, upon the right side of the chest; but no friction or crepitation could be detected, and it went off in a day or two. He improved rapidly in health, the only drawback being an occasional attack of diarrhœa, and the condition of his leg. As regards the latter, it soon became evident that much more of the shaft of the bone was diseased than had been supposed; several openings had to be made in various parts of the leg, and large quantities of pus continued to escape. In about a month the right leg became œdematous, without pain, and probably in consequence of phlebitis; yet the patient's strength, kept up by generous diet, stimulants and tonics, did not appear to deteriorate.

At the end of two months, the patient's health being then pretty fair, and suffering only from the local affection, he was transferred to a surgical ward. While there the local mischief still, though slowly,

Digitized by Google

progressed; the whole shaft of the tibia became necrosed, and the knee-joint involved. Symptoms of phthisis made their appearance. And of this combination of maladies he died on the 12th of January, 1860, just five months after his admission into the Hospital, and three after his removal to the care of the surgeon. No *post-mortem* examination was allowed.

CASE VII.—*Acute necrosis of humerus. Recovery after removal of a sequestrum.*

M. G., a little girl, æt. 11, was admitted into St. Thomas's Hospital under my care on the 1st of December, 1860. Three years since, she was in the Hospital under my treatment for traumatic tetanus, which had been induced by a scarcely perceptible superficial wound on one of the knees, and of which she recovered perfectly. She has had good health since. Seven or eight days ago, she struck her back in the lumbar region against a heavy bar of wood, and at the same time sprained her right shoulder. The shoulder has been painful ever since; latterly, indeed, excessively tender, hot, and swelled. She has been extremely feverish, and her nights have been much disturbed.

On admission, she was perfectly sensible; had a bright circumscribed flush on her cheeks; hot, dry skin, without rash; and dry lips, with an herpetic eruption on the upper one; the tongue was dry and glazed, and somewhat fissured; she was thirsty; had no appetite, but did not suffer from nausea. Bowels rather confined; respirations quick; no cough; breath-sounds healthy; pulse 108; urine thick, not albuminous.

The right shoulder, from the acromial process to the insertion of the deltoid, was hot, swollen, and extremely tender to the touch, or on the slightest motion; and the arm was kept fixed at an acute angle with the side. A few leeches were applied, and subsequently a poultice; and a little febrifuge medicine was ordered.

During the next few days her general symptoms underwent little or no change; but the pain in the shoulder was diminished somewhat by the application of the leeches. I saw her more than once in consultation with Mr. Sydney Jones; and we both came gradually to the conclusion that the disease was not really in the joint, but in connection with the bone immediately below it. On the 10th, although there was no fluctuation to be felt, it was thought desirable to make an incision. A bistoury was passed vertically through the deltoid down to the bone; the first attempt was unsuccessful; a second, made within an inch of

Digitized by Google

the first, brought away a large quantity of pus. The matter evidently came from beneath the periosteum; and a considerable portion of the shaft of the bone, just below the anatomical neck, was found perfectly denuded. Considerable relief, both local and general, followed the operation. The febrile symptoms gradually diminished; and, though matter continued to escape through the incision, the arm got less and less painful, and it became quite clear that the joint itself had escaped.

On the 19th of December she was removed to a surgical ward. The case had then become one of simple necrosis; and her health was so far restored, that her appearance was that of a tolerably healthy child, her tongue was clean, her appetite good, and her rest at night undisturbed. Tonics and good diet was prescribed. She continued for some months in the Hospital, during which time a sequestrum formed. On the 27th of July, 1861, this was removed by operation from the outer side of the shaft of the humerus, immediately below its head. The sequestrum was of irregular shape, about two inches long and one inch broad. The wound closed favourably, and on the 25th of August (nine months from the commencement of her illness) she was discharged from the Hospital perfectly well. Dr. BRISTOWE, *6th of May*, 1862.

18. *Constituents of bone, in a case of mollities ossium.*

The patient was a female, æt. 40, whose history is detailed in the *Lancet* of 5th October, 1861. She was the mother of ten children, all healthy, the youngest twenty-one months old. She had all the symptoms well-marked of the complaint known as mollities ossium; the ribs were bent, and rested upon the crests of the ilia on each side; the parietes of the belly lay in transverse folds; at one period the urine contained large quantities of phosphates. She had involuntary starting of the lower extremities, in one of which the left thigh broke just below the trochanter; this subsequently united. After much suffering and pain she died, worn out, February 1st, 1861. The *post-mortem* examination was made by Mr. T. C. Kirby, who furnished me with a portion of the femur, five inches long, which weighed fourteen drachms; it included the fracture.

The ribs, cranium, and lower jaw were remarkably soft, and could be readily cut with a knife; the bones in various places could be indented with the finger, and resembled thickened skin. The thigh-bones were the most softened, covered with fat, and filled with the semifluid brownish material, commonly noticed in such cases.

Digitized by Google

The texture of the bone above and below the fracture presented considerable differences; that above was more compact and firm, although capable of being cut with the knife. On submitting it to analysis, I found that one hundred parts dried yielded

Earthy matters	52·00
Animal matters	48·00
	100·00

The lower portion of the bone was much softer and could be readily squeezed between the fingers, and seemed to be composed almost wholly of animal matter, covered with a fibrous envelope. On analysis I found one hundred parts dried, to yield

Earthy matters	4·00
Animal matters	96·00
	100·00

This appeared to be a very large proportion of the animal constituents, but not more than might be anticipated in some bones, no doubt, in most cases of mollities ossium; for sometimes the entire earthy matter seems to have been replaced by animal matter.

In my analysis I deemed it sufficient to give the relative proportions of the animal and earthy constituents alone; but the chief ingredient in the latter was the phosphate of lime, with a proportion of carbonate, together with a little phosphate of magnesia.

Dr. Garrod found in an analysis he made of a similar instance (recorded in the 1st Vol. of the "Transactions" of the Society, p. 149), 21·28 per cent. of earthy, and 78·72 per-cent. of animal matters. The healthy standard, according to Berzelius, is 66⅔ of earthy, and 33⅓ of animal-matters. Dr. Gibb, *20th of May*, 1862.

VII.—DISEASES, ETC., OF THE ORGANS OF SPECIAL SENSE.

1. *Encephaloid tumour of the eyeball.*

The patient from whom the eye was removed was a man, æt. 58, and the disease was of five years' standing. It began on the external surface of the sclerotic near the lachrymal gland, and gradually increased until it encircled the entire eyeball, destroying sight and producing

Digitized by Google

extreme pain. At the time the eye was removed, it protruded beyond the orbit; and the lids were so distended that their tarsal border could with difficulty be distinguished during the operation. Much bleeding followed the extirpation of the eye.

A section of the diseased mass showed encephaloid growth, having its origin from the sclerotic, externally; near the entrance of the optic nerve it had began to advance internally, disorganizing the internal structures, so that it could with difficulty be recognised. The minute structure of the growth was composed of—

1. Caudate cells with distinct nuclei.
2. Caudate cells with double nuclei.
3. Free nuclei unsurrounded by cell-wall.
4. Fine filament-cells containing fat globules.

Mr. Henry Obré, *4th of March*, 1862.

---

2. *Bone from the human eye.*

This microscopic section of bone was made from one of several pieces developed in an eyeball which I recently extirpated. The sight had long been destroyed, and the eye was removed, because, being atrophied and useless, it had lately also been the seat of inflammation, and the remaining eye was suffering sympathetically. The bone was found in several irregular small masses; these were lying upon the inner surface of the choroid. This section, which was kindly made for me by Mr Tomes, shows that the bone was thoroughly organized, and not a mere osteoid, half-developed structure. Bone-cells may be seen, and the section of an Haversian canal. It is not often that this thorough development of bone is found to exist in the eye. Specimens of more or less perfectly developed bony-tissue found in this situation have, however, already been shown at the meetings of the Pathological Society, and are recorded in past Volumes of the "Transactions." The bony-matter was always to be found in contact with the choroid. This vascular tissue may probably solely possess the power of forming it. I am not aware that bone has ever been found in any eye which had not previously undergone destructive changes. It would appear to be developed only after the visual use of the organ has been long in abeyance and its normal functions lost. Systematic writers speak of ossification of various tissues of the eye, ossification of the lens, cornea, and retina. I believe that these terms require revision. Preparations which I have seen described as "ossified" lens, would more properly have been called "calcified" lens. I am not aware of any authentic description of bone

Digitized by Google

in the lens, although there are many of calcification. A capsule of true bone has been more than once found within the choroid, and described as ossification of the retina. I would suggest, that what has occurred has been the development of bone in the choroid and atrophy of the retina. Mr. Ernest Hart, 18*th of March*, 1862.

VIII.—TUMOURS, CYSTS, ETC.

1. *Myeloid disease of the elbow-joint.*

C. W., æt. 28, a native of Suffolk, born of healthy parents, and has generally enjoyed good health. Did not notice any difference in the appearance of the affected limb, or experience any pain in it until about six years ago, when he first observed a slight contraction of the elbow-joint, and on attempting to straighten it, a sense of tension of the tendons was felt; this contraction gradually increased up to within the last two years. No pain is complained of, unless the joint is suddenly extended. Since the latter period some pain has set in; and with increasing flexure of the joint, a slight swelling could be perceived, involving the anterior and lateral aspects of the elbow. The pain now became more constant and severe, and has latterly interfered with his sleep.

About two months ago, the swelling almost suddenly increased, accompanied by a proportionate augmentation of the pain; and in the same ratio also was the progress of the contraction.

At the present time the elbow is flexed to a right angle, and is capable only of movement to ten degrees either way. The joint is much increased in size on its anterior and lateral aspects; the posterior portion is natural. The arm and forearm are much emaciated.

The following are the measurements of the sound and affected limbs: —

Around the joint, measuring over the olecranon and humeral condyles, thirteen inches; the sound limb over the same part measuring but nine inches.

Around the arm above the swelling, seven inches; circumference of sound limb at same part, eight inches.

Below the swelling, seven inches; sound limb, seven inches and a-half.

He now suffers considerable pain by night and day of a starting or shooting character, not fixed to any especial locality, but ranging from the shoulder to the wrist. The inner and outer condyles are perfectly

Digitized by Google

distinct; so likewise is the olecranon process—indeed, the whole of the posterior part of the articulation, and the textures above and below it, appear to be quite normal. The veins on the surface of the swelling, forearm and hand are dilated; those of the arm are perfectly natural. There is increasing numbness of the thumb and index-finger, and likewise a thrill in the left radial pulse not perceptible in the right one.

Amputation of the arm was performed by Mr. Canton; and the specimen before the Members of the Society (Plate XII., Fig. 2) shows a well-marked example of myeloid disease involving the bones which form the elbow-joint.

The case, in many particulars, is illustrative of facts, which from numerous instances of this affection have been ascertained, and which are thus clearly and concisely set forth by Mr. Paget*:—"Myeloid tumours usually occur singly. They are most frequent in youth, and are very rare after middle age. They generally grow slowly and without pain. They generally commence without any known cause, such as injury or hereditary disposition. They rarely—except in portions—become osseous. They have no proneness to ulcerate or protrude. They seem to bear even considerable injury without becoming exuberant. They may (but, I suppose very rarely) shrink or cease to grow. They are not apt to recur after complete removal. They have not in general any features of malignant disease."

Mr. CANTON, 19*th of November*, 1861.

2. *Large epithelial cancer of upwards of twelve years' standing, successfully removed.*

This specimen shows for how long a time epithelial cancer may exist, without the constitution becoming involved, and how large a portion may be removed with the best results. It was taken from the back of a lady, æt. 62. It apparently had originated in a mole, which, increasing in size and becoming painful upwards of twelve years ago, was incised for the purpose of letting the matter out, under the supposition of its having suppurated. No pus escaped, but instead, a fungus sprouted out of the wound, which never closed. This fungus gradually increased, until the time I saw it, when it occupied a nearly circular space in the middle of the back, between the scapulæ.

The constant discharge and irritation had reduced the patient's flesh and strength to a very low condition; but finding no evidence of any other organic disease, I removed the part, making a wound seven inches

* Lectures on Surgical Pathology, Vol. II. Lond., 1853.

Digitized by Google

Digitized by Google

DESCRIPTION OF PLATE XII.

Figure 1 is an illustration of Dr. Bristowe's Microscopic Description of Mr. Canton's case of Fibroid Degeneration of the Capsule of the Spleen (p. 214).

a. Represents a vertical section through the thickened capsule, and the fibroid character which such a section shows.

b. An oblique section, showing the essentially laminated structures of the same.

c. A similar section, to that represented in *a*, acted on by acetic acid, demonstrating the absence of cells or nuclei, and the presence of a few granules only between the lamellæ.

All the above drawings are magnified 220 diameters.

Figure 2. Represents Mr. Canton's case of well-marked Myeloid Disease, involving the Bones which form the Elbow-joint.

Digitized by Google

Fig. 1.

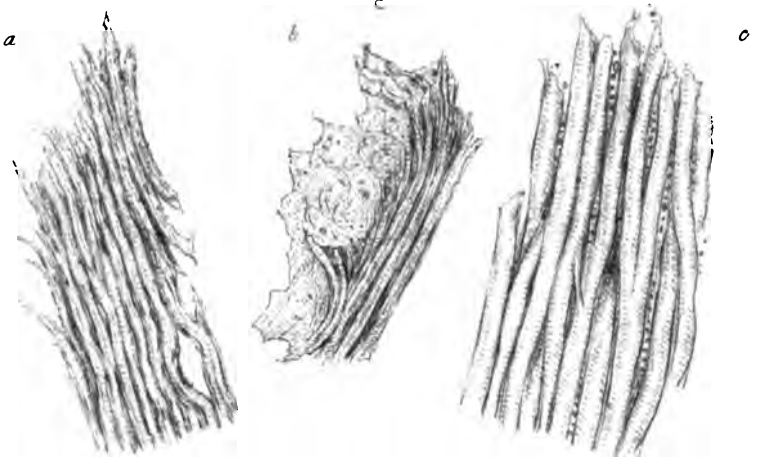

Fig. 2.

Digitized by Google

Printed by Harrison & Sons, St Martins Lane.

Digitized by Google

by six inches, which, of course, had to be left to cicatrize. This it did rapidly and well, without any trouble whatever; the patient, in a few weeks, returning home considerably fatter, stronger, and altogether in better health than she had been for several years.

Mr. NUNNELEY, *19th of November*, 1861.

3. *Encephaloid cancer of the lower jaw, most rapidly developed, with acute suppuration and pyelitis, and commencement of disease in the liver.*

The history of the case furnishing this specimen is in strong contrast with the slow progress of the last case, and exhibits a not very common combination of rapid malignant disease with acute suppurative fever.

The subject was upwards of sixty years of age, and had been, and apparently was at the time he first complained, a strong healthy man, and of a healthy family, in whom no trace of malignant disease had ever shown itself. He had never had any acute illness, except two or three rather obstinate attacks of gout which was not inherited, and only developed within the last three years.

About four months before his death he mentioned to me that there was a partial loss of sensation on the left side of the lower lip, over a space the size of a shilling; his health being otherwise good. Soon there was a varying tenderness of the canine and two adjoining teeth, which was followed by an uneasiness, during mastication, of the last molar of the same side. Though there was neither swelling nor tenderness behind the jaw nor any difficulty in its motions, the symptoms could only be accounted for, on the supposition of some pressure being made on the branch of the fifth pair of nerves, and to this attention was directed. As no alteration in the symptoms took place, without my knowledge the last molar tooth was extracted, and found to be perfectly sound. No improvement in the lip followed, but instead of the gum closing over the socket from whence the tooth had been drawn, it remained open, and when I examined it ten days afterwards, I found a small fungus sprouting from the socket. This was removed twice, and astringents applied several times, by which it was kept in check; when, one night, after exposure to a cold damp wind during the afternoon, my patient was seized with intense fever, with some pain and swelling in the left side of the pharynx. After a day or two, the fever passed off and he went about again as usual, but the swelling in the pharynx did not entirely subside, nor did he fully recover a healthy appearance.

Suspecting malignant disease of the jaw, I was arranging to take the

Digitized by Google

opinion of one or more of my metropolitan friends, when, on the evening of the day the subject was broached, after another exposure to cold and damp, my patient was seized with the most intense fever I ever witnessed in anyone; within twelve hours, he was reduced from a strong man to helplessness, and the side of the face swelled to double its natural size. All the constitutional symptoms of acute pyelitis were manifest. On the third day there was typhoid delirium, and death appeared to be only a question of a few hours. A blush of redness had, a few hours before this, been observed near the left heel. In the hope of inducing suppuration here, strong irritants were applied, and afterwards, a poultice. After lying comatose for six or eight hours, sensibility gradually returned, intense erysipelatoid inflammation set in about the ankle, and spread over the thigh, where it was arrested. In the meantime, the swelling of the face considerably subsided. After two or three weeks, deep suppuration had spread over the whole temporal muscle, and under the jaw as far as the chin. Much matter and several sloughs came away from the openings which had been made externally, and from those which had formed within the mouth; while pus was freely discharged, and subsequently sloughs separated, from openings made in the leg. As the softer swelling from suppuration in the face subsided, a more solid swelling was rapidly increasing on the outer and under sides of the jaw, into the fauces, so as to render deglutition very difficult, and filling up a large part of the mouth. Not a particle of food, of any kind, was taken for several days at the outset of the symptoms; and for the space of upwards of seven weeks, during which he lived after rallying from the comatose condition, with the exception of perhaps three pints of milk and gruel, nothing but wine could be taken. The patient, at last, sank from exhaustion, caused by the loss of not more than a few drachms of blood from the leg.

On *post-mortem* examination, the entire temporal muscle was found to be separated from the parts covering it. The left ascending and horizontal ramus of the lower jaw were so necrosed that the bone broke on the slightest touch. The masses on the outside of the jaw, in the fauces and mouth, were all connected (of which these portions are part), and consisted of soft malignant tissue, which had evidently sprung out of the aperture from whence the tooth had been extracted, having there originated in the cancellous tissue of the bone.

The thoracic and abdominal viscera were healthy, except the liver which was large, hard and nutmeggy, with a patch of suspicious-looking deposit near the lower edge of the right lobe.

Though, for upwards of two months, not an ounce of sold food had

Digitized by Google

been taken, and very little liquid except wine, which had been taken freely, the abdominal parietes and viscera were loaded with fat.

Mr. NUNNELEY, *19th of November*, 1861.

---

4. *Very rapidly and extensively developed malignant disease.*

This third case of malignant disease is one of the most curious which has ever fallen under my notice, and, so far as my reading goes, one of the most rapidly and extensively developed on record.

Mrs. ——, a married woman without children, æt. 52, was first seen by me in June, 1861. She had enjoyed general good health. Not more than six months before this date, she perceived an enlargement in the right breast, which was not attended with much pain. On applying to a surgeon, under the supposition of an abscess forming, leeches and cold lotions were prescribed; subsequently, poultices "to bring it forwards." The swelling rapidly increased, but no matter appeared; she was then told it was cancer which must be removed. An operation was accordingly performed. The wound partially, but never entirely, healed. I found that the greater part of the right breast had been removed. There was a long line of contracted, puckered cicatrix adhering to the ribs; and extending in every direction from it, a wide surface of bright-red granulations from the cutis, with shallow, irregular ulcerations, from which there was a large discharge of offensive watery fluid, having the ordinary cancerous odour.

This appearance extended over the whole surface of the breast, passed under the armpit, and up towards the shoulder, the skin of which was thickened and hard. The arm was fixed to the side, and the entire limb swelled to double its natural size, and quite helpless. The whole skin of it was thick, hard, and coriaceous, studded all over with small papillæ, as though the cutaneous textures were hypertrophied. Some of these spots were larger and red, as though about to ulcerate. The skin, at the bend of the elbow, was excoriated, and gave out a sanious discharge. Cancerous ulceration extended under the axilla to the back; and passing backwards from this, over the whole scapula, was a large irregular patch of a claret colour, in which the skin was thickened, and which was the precursor of ulceration. Similar patches on the anterior surface passed down the side, over the sternum, up nearly to the clavicles, and over the whole of the left breast. This was enlarged to more than double its natural size, and hard, dense, and unyielding to the touch. All these coloured patches were slightly elevated above the surrounding skin. There was a good deal of dull aching,

Digitized by Google

with sharp, shooting pain in the ulcerated surface, but not elsewhere. She said the right breast, when removed, presented exactly the same appearance (except not being so much discoloured), as the left one now does. There was loss of appetite, flesh, sleep, and strength. The breathing was hurried. The rapidity of the disease, it was thought, was decidedly arrested by the treatment, and the swelling of the arm was to some extent lessened by the application of tepid sedative lotions. She did not appear worse than for a month past, when, on waking after a quiet night, she suddenly died on August 22nd, two months after my first seeing her.

On *post-mortem* examination, I found a considerable effusion of serum into the right pleura, and a smaller into the pericardium, which doubtless had caused the sudden death; there was also some thickening of the costal pleura corresponding with the cicatrix. All the thoracic, abdominal and pelvic viscera were healthy.

The drawing, exhibited to the Society, represents the appearance of the parts, three weeks before death. The three portions of tissue are taken from the affected parts; one, from the ulcerated cicatrix passing up towards the axilla; one, from the situation of one of the discoloured patches at the margin of the left breast; and one from the substance of this, it consists of a good deal of fibrous matter with fat, and some epithelial cells. The discharge, during life, consisted of granular matter with epithelial cells, and very little true pus, the odour of it being that so commonly perceived in cancerous sores.

Mr. NUNNELEY, *19th of November*, 1861.

---

5. *Nipple-like tumour removed from the thigh of a female.*

The patient was a young lady, æt. 22, residing at Farnham, in Surrey, who had been the subject of a small tumour nearly all her life, at the upper and back part of the thigh, at a spot where it always came into contact with the chair when sitting, being a little below the tuberosity of the ischium of the right side. Mr. McWhinnie removed it on account of its extreme inconvenience; and it would no doubt have been awkward had she married. It resembled the nipple of a married woman, or the blind teat of a cow, and, on section, was found to consist of a firm and dense white fibrous tissue, apparently originating from the inner surface of the true skin.

Dr. GIBB, for Mr. MCWHINNIE, *3rd of December*, 1861.

Digitized by Google

6. *Anæmia lymphatica.*

R. R., æt. 23, a short woman, with rufous hair, stated that she was delivered of a male child twelve months previously, and, shortly after that event, noticed a tumour in the left side of her neck. Soon after, a similar one appeared in the left axilla; and, a few weeks later, other tumours were discovered in different parts of the body. On admission into the Norfolk and Norwich Hospital, her condition was that of extreme emaciation, accompanied with intense pallor. Each side of her neck presented a large mass of absorbent glands, each mass being so large as almost to meet the other on the opposite side, in front as well as behind, and pressed so much upon the trachea as to seriously interfere with respiration, and oblige her to assume the sitting posture, even during the night. The axillæ contained a collection of the same, as did the spaces above and below the clavicles. Here the tumours were the size of a flattened orange. Each mamma possessed a distinct hard tumour, the size of an egg, and running down the inner side of the biceps of each arm, was a chain of tumours. The skin covering these enlargements was not ulcerated, though her body generally presented a pruriginous eruption. Her eyes were very prominent. The catamenia had been absent since her confinement.

There was resonance and puerile respiration on the left side of the chest, and evidence of hydrothorax on the right. She had no cough; considerable difficulty of swallowing; no phthisical gum-line; nails not filbert-shaped; a soft systolic sound (anæmic bruit) at the apex of the heart. The blood was examined microscopically, and found not to contain any marked excess of white corpuscles; the red were contracted and irregular in shape. There was dulness over a considerable portion of the right side of the abdomen, and this extended to the left hypochondrium. Her motions were clay-coloured for several weeks before death, which took place thirty-two days after admission.

Post-mortem examination.—At the *post-mortem* examination, her body was seen to be greatly wasted, and the skin almost white.

The neck was enormously thickened, and presented a perfect collar of enlarged glands. Each mass consisted of a cluster of smaller ones, packed as closely as possible; they varied in size from a horsebean to a walnut; were distinct tumours, easily separable from one another; were of a uniform milk-white colour, firm consistence, non-succulent, the centre of every one being of the same denseness as the periphery. A portion of the mass is sent for exhibition. The anterior mediastinum contained a chain of the same. In the right pleural cavity were two

Digitized by Google

and a-half pints of serum; the lung was collapsed, and covered with recently-formed lymph. The left lung was congested in many places, and presented an infinite number of round, white bodies, about the size of a split-pea. At the root of the lung, and surrounding the base of the heart, was a huge collection of lymphatic glands, one-half of which is now presented to this Society. It will be seen that they entirely surround, and exert considerable pressure on, the great vessels and bronchi. The heart is very small; the pericardium contained an abnormal amount of serum. The lumbar glands were enlarged, and, with those in the posterior mediastinum, formed a chain of tumours along the whole length of the spine, on each side of the aorta. These tumours were of precisely the same character as those found in the neck and axillæ.

The spleen was small, very pale, and extremely friable, almost "rotten."

The liver extended to below the umbilicus, and over to the left side of the abdomen. Its upper surface was smooth; the right lobe enormously enlarged; its under surface presented several large smooth lobules. On making a section, it cut like bacon, left no grease on the knife, did not feel greasy, would not receive the impress of one's finger. A portion burnt, gave no indication of any fat being present. The Malpighian lobules were well marked; the walls of each were three or four times larger than natural, and pale. The organ was dry throughout, and very firm.

The mesentery, intestines, and stomach were healthy, and the inguinal glands unaffected.

The microscope showed the deposit in the lungs to be of the same character as that in the lymphatic glands, being composed chiefly of nucleated fibres. The liver presented large cells, with granular matter in large quantity scattered through a delicate fibrous stroma.

Mr. BARWELL, for Mr. WILLIAMS, *21st of January*, 1862.

---

7. *Cystic tumour of the breast.*

This tumour was recently removed from the breast of a lady, æt. 52. It had been under observation for nearly two years. When first seen, the breast seemed only to be indurated at its lower part; and here, beneath the moveable skin, could be felt cord-like indurations, giving the sensation of hardened mammary tubes. There had not been much pain complained of. The patient was the mother of a large family, her youngest child being sixteen. Pressure on the indurated

Digitized by Google

tubes produced a flow of clear serum from the nipple, to the extent of about half-a-drachm; if the pressure were too long continued, blood began to flow from the nipple. The breast was tender, and very slight pressure gave pain. The microscopic examination of the fluid showed it to be sero-albuminous, with single and compound corpuscles of epithelium and altered blood-globules. During the progress of the case, fluctuating points occurred at parts of the breast, the skin being here simultaneously thinned, but not discoloured. Pressure on either of these produced readily the serous discharge from the nipple above-mentioned. Its growth lately had been rapid, and, at the patient's desire, the tumour was removed.

The section of the tumour (Woodcut 15) showed innumerable sessile

WOODCUT 15.

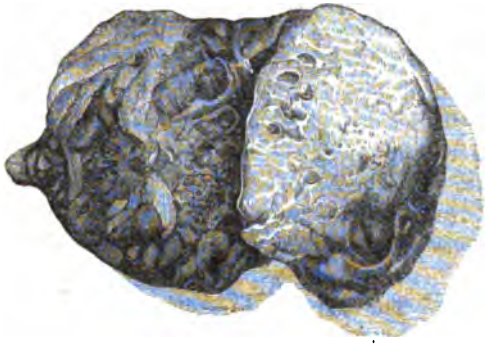

Represents the tumour. On the right side a slice has been removed, to show the numerous small cysts entering into its formation.

cysts throughout its substance, varying in size from a pin's-head to a filbert, some containing sero-sanguineous fluid, others a fatty matter, and a few a highly-organized and partly villous growth. Altogether, the tumour was of unusual appearance for this situation.

I believe it to be a tumour of innocent character, and an example of cystic disease of the breast of an unusual character. Sessile and multiple cysts rarely originate in ducts; but here the clinical history suggests such an origin. I would direct attention to the symptom of continued and free flow of serum from the nipple, throughout the progress of the growth, as one which deserves to be considered in relation to the diagnosis of innocent from malignant growths. This may occur in the first stage of scirrhus, as the result of irritation, or with colloid; but existing throughout the course of the case, it must be considered, I think, to tell in favour of the innocency of the growth.

Digitized by Google

Scirrhus is described as more frequent in married, and cystic disease in unmarried, females. It will be observed that this person was married.

Mr. ERNEST HART, *4th of February*, 1862.

Report on the above specimen.—Section through the centre, as also through several other parts of the tumour, showed that the entire mass was composed of cysts, separated by a firm fleshy structure. These cysts varied in size from that of a pin to that of a small filbert; the majority being, however, of small size, only two or three having attained the larger dimensions above spoken of. Of the cysts, which were all full, a few contained only a turbid fluid, but the greater number contained either a reddish-brown fluid of the consistence of thick cream, or material of a much more solid character, from which a grumous fluid could be squeezed. In some of the cysts (those having the most solid kind of contents, and for the most part the largest in size), the contained material, after pressure and washing with water, could be reduced to a mass of a stringy, fibrous-looking character, which in many cases was firmly connected with the inner surface of the cysts. Here and there the cyst-contents were very dark, and evidently contained a quantity of blood. In all cases the contents could be easily removed from the cysts, where the inner surface was in almost all instances smooth, and of an opaque-white colour.

As regards the *inter-cystic* tissue before alluded to, this was found to have a decidedly fibrous character, to be of a reddish-white colour (after maceration for some days in spirit and water), and here and there to contain masses of solid yellow fatty matter. It varied greatly in thickness, being, in some parts, a twelfth of an inch thick, and unoccupied by cystic formations; but this was only so in very rare places.

Microscopical examination.—The firm tissue existing between the cysts was found to consist of dense fibrous tissue, having, with reagents, the ordinary behaviour of such structure and presenting no peculiarities. The contents of the cysts were, however, found to be very various on microscopical examination.

The fluid obtained from the smaller cysts, which was of a grumous or pultaceous character, contained large quantities of amorphous and molecular material, and also of granules of fat, and great numbers of large and small, round and oval, granular corpuscles, of the same nature as those found in the colostrum of milk, and in many parts of the body which have been the seat of exudations (as in softened parts of the brain, &c.). Moreover, a number of irregular corpuscular elements, like very small free nuclei, were found in this fluid, and here and there

Digitized by Google

bodies of the size of pus-globules, not showing any nuclei on the addition of acetic acid, as also delicate nucleated cells of various sizes and shapes. The nuclei, in most of these nucleated cells, were rendered very apparent on the addition of acetic acid. Many of the cells were broad and abruptly terminated at one end, but tapering to a point at the opposite one; others again were tapering at both extremities, whilst some were much elongated, like fibre-cells. In many cases the cells were adherent to each other, so that masses existed entirely composed of these cells. A few large, darkish, round, and oval cells containing three or four nuclei were met with. The more solid parts of the cystic contents presented the same constituents as those above described, but, in addition, a quantity of partly delicate and pale, and partly firm and fibrous tissue was met with, and also a greater number of the fibre-bipolar-cells than existed in the mere fluid parts. Many of these were curved and crescentic, and otherwise irregular in shape. Moreover, on examining the stringy fibrous parts of the larger cysts above referred to, it was found to present, besides the ordinary delicate fibrous element, a number of branching dendritic growths and finger-like projections of connective tissue, evidently developments of the general mass of fibrous tissue; many of these contained large numbers of simple nuclei.

The very dark-coloured contents of some of the cysts was found to contain abundance of blood-globules mixed up with the other elements.

In some of the cysts, plates of cholestearine were met with.

Dr. JOHN OGLE, *18th of March*, 1862.

---

8. *Atrophic scirrhus of breast.*

This drawing (Woodcut 16) was taken from the breast of an old lady, who recently died at the age of seventy-five. Some twenty-four years since, after having borne a numerous and healthy family, she became aware of the presence of a hard and painful tumour in her breast. The nipple was retracted then, and she consulted two surgeons, who both pronounced it to be a stony cancer: one of them was Mr. Key, who expressed a willingness to remove it, but placed before her clearly the possibility of the comparatively speedy return of the disease, and left the decision in the hands of her friends and herself. It was resolved to temporize and wait. During some years she suffered occasional pains in the tumour; but the breast became gradually harder and smaller, the skin more puckered, until the breast appeared to have almost wasted, and the cutaneous surface, as far as the line of the armpit, to

Digitized by Google

have become furrowed and somewhat indurated. She had become habituated to the presence of this tumour, and disregarded it. She

WOODCUT 16.

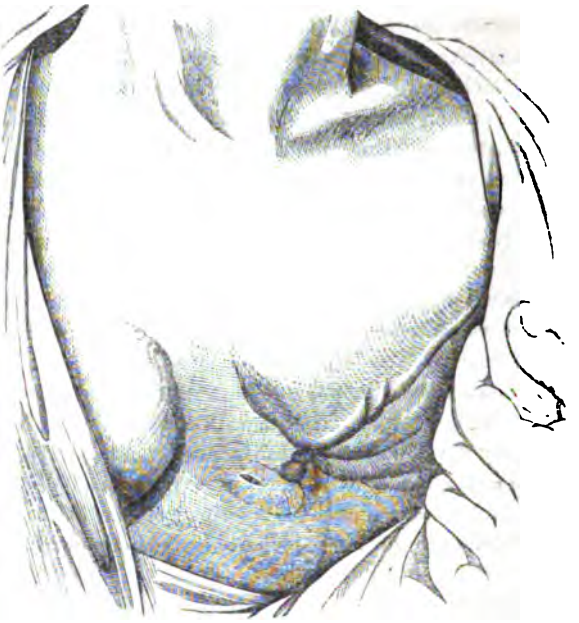

Represents the atrophied and puckered condition of the left breast.

thought that for the last eight or nine years it had remained stationary; and except from occasional pains felt there during cold weather, it caused her no inconvenience or uneasiness.

When I saw the breast in 1860, the whole gland appeared to have been shrivelled up and wasted. It was quite flat and in a plane with the surface of the chest. The nipple was entirely retracted and sunk in a fossa, while from it radiated grooves passing chiefly inwards, and fissures in the skin. Here the subcutaneous tissue was condensed and infiltrated with hard matter, and here and there small hard tubercles were disseminated; the edges of these fissures were hard and rounded, sometimes forming, as it were, a hard fold of skin. This mamma was entirely atrophied; that on the opposite side was natural. This was the state of things which had existed for many years. The patient was totally blind from the formation of hard cataract in each eye, and I was called in with a view to remedy the blindness.

Digitized by Google

Looking to the actual condition and history of the disease of the mamma, I considered that this was a case in which atrophy of a scirrhous breast had occurred, as the general health had been quite unaffected, and no activity had been manifested in the tumour for several years. I concluded to remove one of the cataracts, with a view to the restoration of sight. Mr. Flower, then Assistant-Surgeon of the Middlesex Hospital, and now Hunterian Curator of the College of Surgeons, examined the breast, and kindly assisted me at the operation. I believe that his opinion as to the nature of the disease coincided with that which I have expressed. The operation was by the lower section, and when the eye was opened on the fifth day the flap had firmly united. The recovery was excellent. I mention this circumstance incidentally, because it indicates the constitutional condition. After this time, the patient continued under my observation, she had occasionally little ailments of cough and debility incidental to her advanced age. She suffered severely from the effects of the great alternations of weather this winter, from severe cold to comparative mildness and humidity, and she sank peaceably in December. I regret very greatly that no *post-mortem* investigation was permitted, for the examination of the internal organs would have been hardly less interesting than that of the surface of the breast.

I thought that the description of the external characters and history of the disease would still have great interest. Cases in which reputed scirrhous breasts have been seen to atrophy, and the disease to be not cured, perhaps, but arrested, have been shown and described. So far as external characters go, nothing could seem more characteristic of scirrhus than the condition of this breast. It would be very desirable to have the record of the microscopical characters of such a case. It would seem, probably, that the septa and fibro-cellular network are first the seat of the disease, that as these become altered, hardened, and degenerated, the true gland-tissue is strangled and wasted by their pressure, while the septa thus degenerated become themselves atrophied. The indurated subcutaneous tissue, the retracted nipple, and the sparse disseminated tubercles, beneath the skin, remain to bear witness to the original character of the disease. The fact of the long-continued inactivity and harmlessness of this tumour, and the readiness with which the cornea healed at an advanced age, after the operation for extraction of the lens, are points of great interest, showing how little the constitution was tainted, or suffered from that taint.

Mr. Ernest Hart, *18th of February*, 1862.

Digitized by Google

9. *Cancer of the three lower lumbar vertebræ.*

At the last meeting of the Society, it may be remembered, I presented a specimen of cancer of the ovaries, in illustration of the difficulty of diagnosis in cases of cancer affecting the abdominal or pelvic organs. In further illustration of this subject, I beg now to relate the salient points in a case of cancer of the bodies of the three lower lumbar vertebræ.

The patient, a lady, æt. 55, first complained of a pain in her left lumbar region, thirteen months previous to her decease; this pain soon became fixed in a spot corresponding with the left sacro-iliac synchondrosis, shooting from thence down the course of the crural nerve to the knee. The pain in the knee was excruciating, and there was considerable loss of power in the limb. She could not be moved in bed without crying out with the agony in the knee, and the spot above indicated. During the first two months of her illness, she suffered greatly from pruritus pudendi, and an irritable state of the bladder. The rectum gradually became paralyzed, allowing the fæces to collect, and rendering it very difficult to remove them by means of injections. The fæces were peculiarly clayey and tenacious, so that it was impossible to break up the mass to render it more easily removable. The sphincters retained their power to the last. The bladder lost its power about a month before death.

She had a cancer of the left breast, which had existed some years. The nipple was retracted. It diminished considerably in bulk before her death, and on examination afterwards, was found to have very little cancer-structure in it.

During the course of this lady's illness, she was seen and examined by at least ten physicians and surgeons, and it was not until about five months before her death that the suspicion of cancer arose. At a consultation that was held then, at a time when she had become much emaciated, the liver was found enlarged, and its surface uneven, this gave us the impression that it was due to a secondary deposit of cancer. But where were we to look for the primary seat of the disease; there was no tumour to be felt in the abdomen or pelvis, and the bones at the seat of pain were not enlarged. From the intense pain over the left sacro-iliac synchondrosis, it was believed that cancer existed near that spot, involving or pressing upon the lumbar nerves.

The *post-mortem* examination confirmed our diagnosis, and enlightened us as to the true seat of the disease. A mass of cancerous lumbar glands lay on the bodies of the vertebræ, with the nerves emerging from beneath them. On removing these, the point of the scalpel soon dis-

Digitized by Google

covered the primary disease. The bone-structure of the bodies of the last three lumbar vertebræ was almost entirely removed and replaced by cancer, the scalpel passing readily through them. The intervertebral substances were untouched by the disease. The liver had several nodules of cancer in its substance.

In both this case, and the one related at the last meeting of the Society, there was a marked similarity in the agonizing character of the pain, and in the characteristic pain in the knee from pressure on the crural nerve, in one near its origin, in the other in its course through the pelvis. In neither was there any pain at the seat of the disease. In the case above related, there was no pain in the lumbar vertebræ, not even on percussing over the spinous processes; in the case of cancer of the ovaries, there was pain only in the right lumbar region immediately above the crest of the ilium, extending from thence down the course of the crural nerve to the knee. In both, was cancer first suspected from secondary formations; in one, in the liver, in the other, by the discovery of cancerous nodules in the walls of the abdomen. In the latter case, the patient menstruated for the last time just two months before her death; the discharge lasted the usual time (a week), was of the ordinary quantity, and accompanied by the same amount of pain in the back and lower part of the abdomen, as she had suffered from for many years past. Mr. CURGENVEN, *18th of February*, 1862.

---

10. *Enlargement of lymphatic glands with deposits in the viscera.—Anæmia lymphatica.*

This form of disease, which was first described by Dr. Hodgkin under the name of enlargement of the lymphatic glands with a peculiar deposit in the spleen, would be better designated by the term anæmia lymphatica. It has been found that the deposit of which he speaks is by no means confined to the spleen, but may affect the liver and other organs,* as occurred in the present case, and thus in all probability the disease is one affecting the lymphatic system generally. This has been suggested by the deposit in the spleen occupying the Malpighian corpuscles, and in other organs taking the course of the lymphatics; although it must be stated, that the fact of these vessels being affected has not been actually proved. The material which is deposited is of a low organizable kind, consisting of some translucent albuminous matter with ill-formed cells and fibre-tissue. It will be seen in the following case, that this material in the liver was tough and fibrous, whereas, in

* Guy's Hospital Reports, Series III., Vol. II., p. 115.

Digitized by Google

the kidney, it was cellular and thus resembled tubercle; as, at the same time also, a deposit occurred in the lung, which appeared like ordinary tubercle, it was difficult to speak with certainty of the nature of the deposit in this last-mentioned organ. In other instances also, this deposit has been found associated with tubercle, and thus a connection appears to exist between the two, either illustrating how the former is a modification of tubercle, or that that which appears to be tubercle in these cases is in some way altered, and thus that the adventitious material throughout the whole body is altogether peculiar. This disease is fatal in course of time by anæmia, and finally, perhaps by dropsy. It has been styled *leucocythemia*, but I have never yet discovered in these cases that large excess of white corpuscles which has rendered it deserving of the name, as in the instances when the spleen is hypertrophied; I think, therefore, a preferable name is *anæmia lymphatica*.

H. G., æt. 29, employed at a warehouse in the city, had long been under the care of Mr. Roper of Shoreditch. About three years before his death his health began to fail, and even for two years before that he had been much depressed in spirits owing to a disappointment in marriage. Previous to this his health was very good, and he was regular and temperate in his habits. For three years his symptoms had been those of excessive anæmia, with all the ordinary accompanying phenomena, and for this he was constantly under medical treatment. He had got somewhat thinner, but not much so; he was very pale and chlorotic-looking, suffered much from breathlessness and palpitation. Mr. Roper had constantly examined him and could discover no disease; the chest was normal, the spleen could not be felt, the urine was natural, there was no increase in the white corpuscles of the blood. There was some enlargement of the lymphatic glands on the left side of the neck; he had occasional epistaxis. Mr. Roper, knowing the interest which I took in these cases, sent the patient to me on one or two occasions, when I could not, any more than Mr. R., discover any disease, and I, therefore, regarded the case as one of simple anæmia, or probably anæmia connected with disease of the lymphatic system, and, therefore, anæmia lymphatica. He continued sometimes better and sometimes worse, regained some strength by visits to the seaside and ferruginous medicines, until a few weeks before his death, when his breathing became worse, and anasarca of the legs came on. These symptoms increased until death.

Post-mortem examination.—The body wasted but not excessively so. Legs anasarcous. Serum in chest and abdomen. Lungs filled with miliary tubercles, probably rapidly developed, and to these were due the

Digitized by Google

later symptoms. Heart healthy. The glands on the left side of neck were slightly enlarged, and these communicated with similarly enlarged glands in the mediastium, but not of very great size. The glands principally affected were the lumbar, which formed a large mass on the spine. When cut they were found to be firm, of a yellowish colour, translucent, and apparently only hypertrophied, as no adventitious matter was evident to the naked eye. The thoracic duct was traced throughout its course, and did not appear to be anywhere compressed. The liver was of usual size, and apparently quite healthy as seen externally, but when cut into, a number of white or yellowish-white deposits were seen scattered through the organ. A further examination showed that these occupied Glisson's capsule and permeated the liver along with the portal vein and duct (Plate IV., Fig. 2); on transverse section some of these were seen to be as large as a fourpenny-piece, and in their midst were running the usual vessels. This material resembled fat to the naked eye, but when felt, was found to be tough. The kidneys contained also a quantity of white matter running principally in lines through the cortical substance. This was softer than that in the liver, and had more of the ordinary tubercular appearance. The spleen was apparently healthy; large and firm, but containing no evident deposit.

The microscope showed, that the enlargement of the glands was due to the deposition of a low organizable albuminous material of a glistening and translucent appearance, and also of some ill-formed cells, and some nucleated fibre. The substance in the liver was composed mainly of fibre-tissue, amongst which were nucleated cells. That in the kidneys was composed mainly of ill-formed cells.

Dr. S. WILKS, 18*th of March*, 1862.

11.—*Cancer of the axillary glands, involving the axillary artery, and resulting in the formation of a false aneurism and fatal hæmorrhage.*

T. M., æt. 30, was admitted into the London Hospital, with some swelling of the left axilla, and an ulcer of the size of half-a-crown, in the floor of the space near the anterior fold. The man looked pale, and said that he had lost blood from the sore.

On December 3rd, Mr. Maunder saw the case, having been summoned on account of recurrence of hæmorrhage, and found the patient exceedingly prostrate and exsanguine. The history was obscure, the patient being almost too exhausted to reply to questions put to him. From what could be gathered, the disease had existed some twelve months; a lump in the armpit, having been discovered accidentally one morning,

Digitized by Google

(which the patient said was not there on the previous evening); this lump had increased in size, becoming harder, until about a month ago, when the skin broke. On the 29th of November, bleeding to a great extent occurred for the first time, at his lodgings, but ceased spontaneously; it returned twice during the night of December 2nd, but was controlled by plugging with cotton-wool, and a solution of perchloride of iron. As to the precise nature of the malady, the man was too weak, (and no time could be allowed for a close examination) to determine. It might be either malignant disease involving a large artery, or, a ruptured aneurismal sac. Under any circumstances, it was deemed right to endeavour to secure the bleeding vessel, though the man should die on the operating table, rather than, unattempted, to allow the patient to succumb, from hæmorrhage, in his bed. The anterior wall of the axilla was accordingly laid open up to the clavicle, disclosing a mass of malignant disease, softening and involving, and concealing the contents of the cavity. The bleeding vessel could not be detected, but a ligature applied to the axillary artery at the highest point practicable controlled the hæmorrhage.

The man died two hours after the operation.

Post-mortem examination.—Besides involving the upper part of the pectoralis major and minor muscles, the disease had destroyed the posterior half of the circumference of the axillary artery in the middle of its course, to the extent of half-an-inch in a longitudinal direction. Opposite to this, a cavity, large enough to contain a walnut, stained with blood and partly filled with coagula, but with a hole in its wall, existed, and was, doubtless, the source of fatal hæmorrhage.

The axillary vein was compressed and obstructed.

The ligature may be seen to constrict the vessel about three-quarters of an inch above the wound in it.

Mr. MAUNDER, *15th of April*, 1862.

---

12. *Enlargement of lymphatic glands and spleen. Extreme fatty degeneration of heart and liver.*

W. B., a boy, æt. 5 years, admitted to the Hospital for Sick Children on the 21st of March, 1862, under the care of Dr. West.

The youngest of six children, four having died young; the other living child not very healthy. No evidence of syphilis. About two years ago, he had hooping-cough; previously to this, he had been a fine healthy boy. At that time, glandular enlargement was noticed at the left angle of the jaw. As the hooping-cough got well, the glandular en-

Digitized by Google

largement did not subside, but went on increasing, and the child lost flesh, and became pale. He was sent to Brighton in August, 1861; the swelling became soft, and was opened. A little curdy-looking matter is said to have come out *on squeezing*. The wound only remained open a few days. The swelling appeared to decrease after this. In three weeks he returned to town, and then the swelling increased, and has continued steadily to do so ever since. His appetite was capricious, sometimes ravenous. His stomach had been noticed to swell, and be tender, especially in the left hypochondrium, for about three weeks. When admitted, he was found to be a small, poorly-nourished child; very anæmic, almost chlorotic, in aspect; abdomen full and tense, painful on pressure; spleen felt to be enlarged, extending nearly down to the crest of the ilium, and forward to the umbilicus; liver not to be felt.

At the left angle of the lower jaw was a very large swelling, extending from the lobule of the ear down to one inch and a-half below the ramus of the jaw, forwards to within three-quarters of an inch of the mesial line, and backwards, to within half-an-inch of the external margin of the trapezius. It was irregularly lobulated; it felt like moderately firm, elastic, enlargement of glands, with softer tissue between them; the lobules were very moveable on each other, and surrounding tissues. There was a white scar on the centre of the swelling. There were large tortuous veins spreading from the inner end of the second intercostal space close to the sternum, extending to the left acromion over the general surface of the swelling. At the right angle of the jaw, two or three glands were enlarged. They were not so hard as tuberculous glands. Glands of the groin not swollen. Pulse 140, feeble, with slight jerking.

He was treated with quinine and steel. The blood examined microscopically showed no excess of white corpuscles. Urine free from albumen.

From this time he became gradually worse; there was a slight general hyperæsthesia of the surface; his complexion became more chloro-anæmic; and he was frequently sick. On the 8th of April he died, being previously slightly convulsed for a few hours.

On *post-mortem* examination, the body was found to be much emaciated. The glands of the neck were much enlarged, more especially on the left side; on this side they were united to form a large lobulated mass, which measured six inches by four, by one inch and a-half. The separated glands were united by firm connecting tissue into one mass. On section, the mass was seen to be made up of enlarged and altered lymphatic glands, having a yellowish-white semi-translucent aspect. It was tough, and gave out no juice such as can be squeezed from can-

Digitized by Google

cerous growths, but a very little thin fluid. The section presented nearly a uniform texture throughout; and manifested no unusual appearance on the addition of iodine and sulphuric acid. Under the microscope, there appeared to be a large number of mono-nucleated, round and fusiform cells, such as are seen in fibro-plastic growths; and many small free nuclei.

The spleen was found to be enlarged, weighing nine ounces. It presented, on section, a number of white masses scattered through it, of varying sizes, from pins'-heads to large split-peas; some were opaque-white, just like lumps of suet; some points looked like cold, and others like hot, suet, as observed by a gentleman present at the *post-mortem* examination. The liver was pale and mottled, owing to fatty infiltration of the *centres* of the lobules, not of their peripheral portions, as is more commonly the case. There was one mass in it about the size of a large filbert, surrounded by a narrow ring of injection; this seemed to be one of those fibrinous infarctions frequently seen in the spleen, kidneys, and other viscera. There were, besides this, two or three very small white deposits in the liver not surrounded by injection, which were, probably, of the same nature as those in the spleen, but, unfortunately, they were not minutely examined.

The heart was very pale, and presented a peculiar mottled condition, resembling in appearance, what is called by cabinet-makers, bird's-eye maple. On microscopic examination, the muscular fibres exhibited a very advanced degree of fatty degeneration. Near the apex of the left ventricle was an opaque-white mass of fibrin interlaced in the columnæ carneæ, and so closely united to them that, at first sight, it looked as if the heart-fibres had been partially changed into an opaque-white substance. From this mass had probably originated the deposit mentioned in the liver. The bronchial and mesenteric glands were enlarged, and presented changes similar to those described in the glands of the neck. The axillary and inguinal glands were not enlarged. The microscopical elements of the lumps in the spleen were, in addition to the ordinary splenic elements, a quantity of fibro-plastic cells and nuclei,—just as in the lymphatic glands. The lungs, stomach, intestines, kidneys and brain appeared healthy, but were all extremely anæmic.

This case appears closely to resemble cases described by Dr. Wilks, in Volumes X. and XI. of our "Transactions." As in his cases, the lymphatics of the neck would seem to have been involved for some time before any other grave symptoms; in this case about two years; and the enlargement of the spleen, probably came on much later. It seems to be disease of nutrition, having some analogies to cancer, albuminoid

Digitized by Google

Digitized by Google

DESCRIPTION OF PLATE XIII.

The Plate illustrates Mr. Holthouse's case of large Cystic Tumour of the Perinæum (p. 233).

Digitized by Google

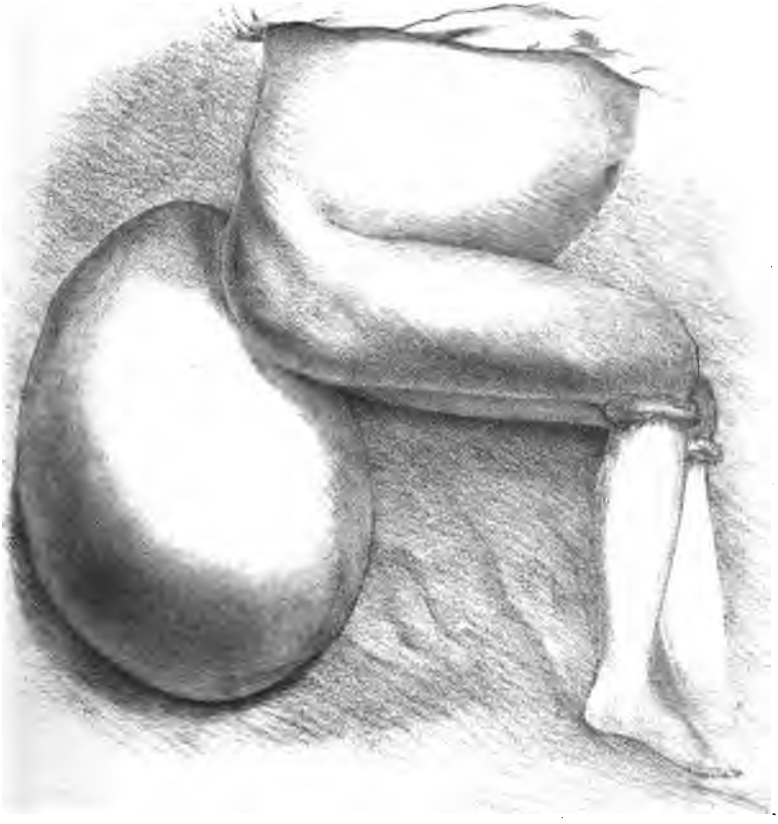

Dr Westmacott del. Tuffen West lith.

W. West imp.

Digitized by Google

Digitized by Google

disease, leucocythemia, and tubercle; being probably more closely allied to tubercle than to the other diseases. The cases reported by Dr. Ogle, in Volume XI. of the "Transactions," do not seem to me to be exactly of the same nature, although he regards them as agreeing with the cases reported by Dr. Wilks. In Dr. Ogle's cases, the enlarged glands were of a bright-red colour, and easily broke down into a pulpy state, instead of being yellowish-white and firm. The microscopical characters were also quite different in his cases, from what are described by Dr. Wilks, and from what I found in this instance.

The other members of the family in the case which I have reported, appear to have been, all of them, unhealthy. Of the five brothers and sisters, only one was surviving, and he was said to be delicate. One died at the age of fourteen months, of hooping-cough; one died at the age of twenty-seven months, on the fifth day of an attack of scarlatina; one died in convulsions, with glandular swellings, twelve months after an attack of scarlatina; and the other died at the age of three months, never having thrived. Dr. HILLIER, *15th of April*, 1862.

---

13. *Large cystic tumour of the perinæum.*

The subject of this tumour was a female, æt. 48, married, and the mother of four children, the youngest of whom was ten years of age at the time of her death. The tumour was first observed about nine years previous to this event, and steadily increased in size till it attained the dimensions seen in the cast (Plate XIII.). Four or five years before the woman died, she consulted Mr. Tebay, of Great Smith Street, Westminster (to whom I am indebted for these particulars, as well as for the opportunity of making the *post-mortem* examination), who considered the tumour to be a pudendal hernia; and such was the opinion of some eminent surgeons to whom Mr. Tebay showed the case. At this time it was about the size of a child's head at the period of birth, having an elongated pedicle, by the side of which, and forming indeed a part of it, was the rectum running straight down and terminating in the anus—just where the pedicle expanded into the tumour; it looked very much, Mr. Tebay says, like a child partly born, only the neck was longer and more slender than a child's neck. Beyond the inconvenience occasioned by the bulk and weight of the tumour, it did not for some years interfere materially with the patient's well-being; the functions of micturition and defecation were performed normally, and she menstruated regularly. Two or three days before her death, Mr. Tebay kindly invited me to see her; she was then emaciated and greatly exhausted,

Digitized by Google

her abdomen was distended with fluid, and she was altogether too ill, considering I did not visit her in a professional capacity, to permit of my making an examination of the tumour. After death I obtained permission to take a cast of the tumour, and also to make a *post-mortem* examination of the body.

Post-mortem examination.—The vagina was situated in front of the pedicle of the tumour, and the anus on the left side of the pedicle. On opening the abdomen a large tumour presented itself, concealing the viscera, which were pushed upwards towards the diaphragm. An incision being made into the tumour, several gallons of fluid were evacuated; and it was then discovered to be the upper or abdominal portion of a large cyst, the lower part of which, covered by skin, formed the pendulous tumour in the perinæum; the neck or constricted part corresponded with the outlet of the pelvis; thus it had somewhat an hour-glass shape, and the intra- and extra-abdominal portions freely communicated with each other through the central tubular pedicle, which admitted the passage of the hand and arm from the abdomen to the bottom of the perinæal portion of the cyst. The origin and nature of the cyst could not be satisfactorily made out at the *post-mortem* examination. Its walls appeared to be continuous with the peritoneum; it looked like an enormous diverticulum from this membrane, originating in some part of the pelvis, extending upwards towards the diaphragm and forming the abdominal portion of the cyst, whilst the recto-vaginal pouch was prolonged downwards to the bottom of the perinæal tumour, constituting, in fact, the lining membrane of that tumour, in the lower half of the cyst. The entire tumour was removed in two parts by cutting through its pedicle; with the extra-pelvic portion was included about the lower third of the rectum; with the intra-pelvic portion were the urinary bladder and ureters, the uterus and its appendages, and a small portion of the vagina.

Further examination of the *parts removed.*—Connected with the fundus of the uterus was a pedunculated cystic tumour about the size of a goose's-egg; the lower half of this was partly solid and partly cellular; the upper half entirely cystic, and filled with fluid. The uterus itself was healthy, as were likewise the Fallopian tubes, and the ovaries and their ligaments. The right round ligament was much elongated, and the right broad ligament, thin and sharp above, and including between its layers the above-named structures, appeared to expand below into the cyst. The walls of the abdominal portion of this cyst varied much in thickness, being in parts very thin and translucent, and in others having masses of solid substance included between them; its

Digitized by Google

interior was in parts slightly sacculated. The perinæal portion of the cyst, though smooth and covered by skin externally, was slightly sacculated within, there being one accessory pouch of some size, communicating with the general cavity by a wide mouth. No solid masses were met with here, as in the abdominal portion of the tumour.

Mr. Spencer Wells and Mr. Hulke were associated with me for a further examination of, and report on, the tumour. Mr. Wells thinks it probable that it was originally a cyst in the broad ligament, and Mr. Hulke and myself incline to the same view. Mr. Hulke having examined, microscopically, portions taken from three different parts of the cyst, did not find any structures which do not occur in peritoneum. He was not able, however, to make out the epithelial lining, which might have afforded some distinctive characters. "Thus, whilst I cannot affirm," observes Mr. Hulke, "that the cyst is peritoneal,

WOODCUT 17.

Represents, in the form of a diagram, the supposed intra- and extra-pelvic relations of the tumour.

Digitized by Google

neither can I say it is not." The tumour having been several years in spirits, will probably account for the absence of the epithelium. Mr. Hulke furnished a diagram (Woodcut 17), illustrating the connection between the intra- and extra-pelvic portions of the tumour, and the relations of its neck to the pelvic viscera. This represents probably the exact relation of these parts at an early period, but we have seen that later the rectum was dragged downwards, so that its lower part was without the pelvis, and pushed somewhat forwards and laterally.

Mr. C. HOLTHOUSE, *6th of May*, 1862.

---

14. *Cancer of lower jaw.*

W. M., æt. 50, a native of Dorsetshire, a man of large frame and intemperate habits, who, twenty years ago, had his right leg amputated for diseased ankle-joint. He, for the first time, noticed a swelling in the left submaxillary gland, seven or eight years ago; this has become painful, and rapidly increased in size during the last two or three months. There is now a globular mass below the middle of the left horizontal ramus of the jaw adherent to the bone, but moveable, giving an obscure feeling of fluctuation. The angle of the jaw is expanded on the outer side. Acute plunging pains pass backwards from the tumour to the ear and side of the head.

At a consultation it was decided to remove the tumour, and as much of the jaw-bone as might be found to be necessary.

Operation, Nov. 11th, 1861.—The patient being under the influence of chloroform, an incision was made downwards from the lobe of the ear, to three or four inches down the neck, and another transversely, to near the symphysis, and one short of the red line of the lip falling into it. The flaps were then dissected upwards and downwards. After the removal of the canine tooth, the bone was divided, with a clean section, by means of a common amputating saw, and finally, the temporo-maxillary joint was disarticulated. The flaps were brought together by ten harelip-pins and twisted-silk. The wound was frequently brushed with sweet-oil. Beef-tea and brandy enemata were administered.

November 12th.—He has had a good night, and swallowed a little milk. The enemata were ordered to be continued, and the alternate pins were removed. The wound was poulticed on account of some redness.

13th.—The remaining pins were removed. Beef-tea and milk were swallowed well, and enemata left off.

14th.—Sutures were removed and the wound found healed, except where the ligatures came out. Speech returned.

Digitized by Google

16th.—Asked for minced-meat; was placed on full diet and stimulants.

17th.—Sat up; two ligatures came away.

He got on very well till the third week, when an abscess formed under the chin, which discharged into the mouth, and subsided in a week.

During the fourth week, he had constantly recurring rigors with all the symptoms of pyæmia, and sank exhausted on December 11th, 1861.

The *post-mortem* presented the appearances usually found after death from pyæmia. The heart was large and flabby; the cortical structure of both kidneys was pale and adherent to the capsule; no cancer existed anywhere. Ligamentous structure was found in the site of the removed bone; the wound was perfectly healed.

Examination of tumour.—It is enclosed in a thick fibrous capsule, connected with the periosteum. On section, it has the appearance of ordinary scirrhus, permeated by fibres, and resembling a raw potato. A milky juice can be scraped from it with a scalpel. At its junction with the jaw, the bone is carious.

Microscopical examination by Mr. Tippets.—It is composed of nucleated cells chiefly, with a few fibres. The cells vary much in size and shape; many being roundish, oval, oblong, caudate or fusiform. The nuclei are large; in some cases, well-defined, and generally, single. They contain, for the most part, one or two nucleoli. There is a large quantity of granular matter, both within and without the cells; and also some oil-globules, either free or contained in the cells.

Remarks.—The chief points of interest in this case, are:—

1. The absence of any deposits of cancer in other parts, fully justifying the performance of the operation.
2. The valuable aid afforded by the nasal inhaler, in sustaining the insensibility from chloroform, until the conclusion of the operation.
3. The advantage of the common amputating, over the chain, saw.
4. The rapid healing of the wound.
5. The omission of stuffing the wound with lint, in the after-treatment.
6. And the rapidly fatal attack of pyæmia.

Dr. QUAIN, for Mr. W. D. WILKES, *6th of May*, 1862.

---

15. *Anomalous tumours of the leg consisting chiefly of extravasted blood.*

E. N., æt. 56, unmarried. Has always been of a delicate constitution, and when a child, suffered from enlargement and suppuration of the axillary glands. Her mother died of phthisis when thirty years of age, and her father was cut off suddenly by apoplexy. Has had four

Digitized by Google

brothers and one sister. The brothers are dead:—one died in infancy, a second at the age of ten years, of hip-joint disease; the others, of phthisis at the ages, respectively, of twenty-three and thirty-two. The sister is living, a healthy woman, and the mother of nine children.

In the spring of 1849, the patient first noticed a small dark-coloured tumour in the calf of the left leg, and which she could not trace to the receipt of any injury. It was quite free from pain and immoveable. No varicosity of veins existed. The tumour gradually increased in size, and towards the latter end of the above-mentioned year and the beginning of the next, it became painful, the pain being of a shooting and lancinating character, and though inconvenience is always felt, the pain is remittent in its severity. No advice was sought for six years, as she was still able to follow her employment of a domestic servant.

In the summer of 1855, she noticed a small tumour towards the posterior part of the left external malleolus. This was moveable, and from the first, painful. It attained the size of a hen's-egg. She was now under the treatment of Mr. Gilbertson of Preston, and in January, 1856, the swelling was removed, and the wound healed completely. No further inconvenience was experienced for nearly twelve months, when something like a wart was found to have sprung from the cicatrix, which was of a dark, purplish colour, accompanied by continual pain. A year and a-half since, the surface of this excrescence ulcerated, and a species of fungoid growth appeared which often bled freely, and has continued in its hæmorrhagic tendency until the present time. At one time, however, it showed a great tendency to improvement, but when cicatrization was nearly complete, it nevertheless, "broke out" again. The tumour in the calf of the leg had been leeched, blistered, bandaged, &c., without any resulting improvement. It now increased rapidly in size and became more painful. About the beginning of last March the skin covering it ulcerated, and a mass, similar to that which sprang from behind the malleolus, burst forth and occasionally bled freely; the pain, however, became considerably lessened. There was no enlargement of the inguinal glands.

When admitted into the Charing Cross Hospital, under the care of Mr. Canton, the patient was found to be thin, pale, and exhausted. The countenance was expressive of long-suffering, and there was a most remarkable blueness of the scleroticæ of the eyes. The appetite was gone; her nights were almost sleepless. Says that she has latterly become much emaciated. Menstruation regular. Pulse 100. Respiration hurried and feeble.

At the back of the leg, and at a short distance below the knee, is a

Digitized by Google

large fungus-looking mass, projecting considerably, and frequently hæmorrhagic. It is surrounded by a broad dusky surface. There is no perceptible enlargement of veins in the neighbourhood, nor are these vessels of the limb varicose. Immediately adjoining this swelling, are two or three others about the size of a plover's-egg; the skin over them is intact, and their colour is very dark, giving the impression of their being melanotic tumours, except that in their consistence they are softer than such disease is ordinarily found to be. From these, and extending down towards the outer malleolus, the skin is of a dusky-pink hue, and just above the ankle are several more swellings exactly like those just described, and varying in size from that of a small pea to a marble. Over, behind, and extending from, the malleolus towards the dorsum of the foot is a large breach of surface filled with florid, flabby granulations and fungoid-looking material, from the whole of which bleeding frequently takes place. Closely adjoining this surface are several small tumours like those above-mentioned; and appearing, too, melanotic deposits, with unbroken skin over them.

After the employment, for some time, of various forms of local application, and the adoption of different constitutional remedies, without the slightest benefit, it was deemed expedient to remove the limb; and Mr. Canton having amputated it above the knee, the leg was now placed before the Society for their opinion regarding the pathological inter-

WOODCUT 18.

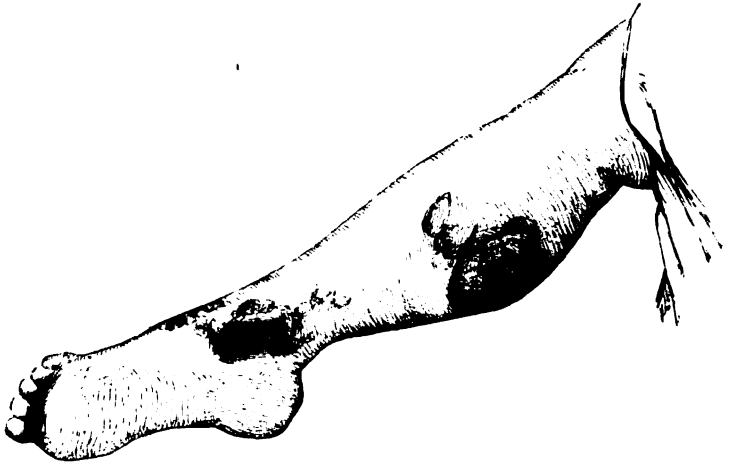

Represents the appearance of the leg before amputation was performed.

Digitized by Google

pretation of the case. The entire thickness of the gastrocnemius muscle was involved in the affection, and beneath the skin above and around the malleolus were small tumours similar to those which have been described as near the surface in this situation. On section of these, it was found that they consisted of coagulated blood, of the venous colour, and nowhere was there a trace of melanotic deposit. The veins were not varicose or otherwise diseased.

The microscope does not appear to throw any particular light on the determination of the exact pathology of the disease, which, in all probability, was one in which a peculiar blood-crasis existed. Some months have elapsed since amputation was performed; the stump healed most favourably, and the patient's health became materially improved, without there being a return of the malady in any other part of the body.

Mr. Mason kindly undertook to examine the tumours, and thus reports upon them:—

"A careful microscopic examination shows (Woodcut 19 A) a large

WOODCUT 19.

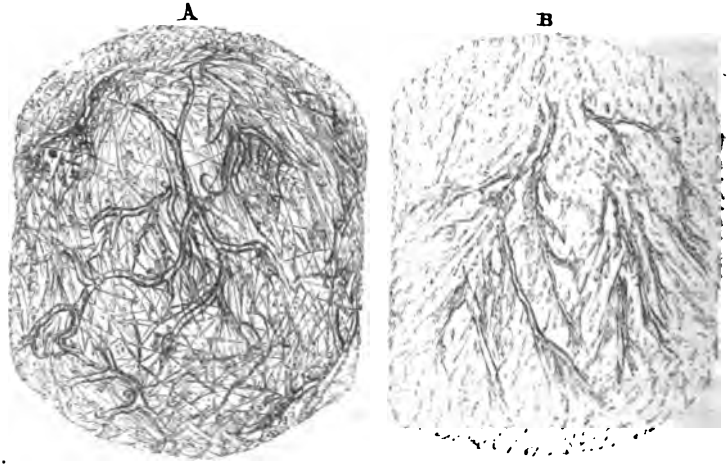

quantity of white and yellow fibrous tissue; the interspaces being filled with minute granules. No cells indicating that the disease is of a malignant nature can be detected. The addition of acetic acid (B) brings into view a large amount of granular débris, leaving the elastic tissue unaffected." Mr. CANTON, *20th of May*, 1862.

Digitized by Google

SECTION IX.—DISEASES OF THE DUCTLESS GLANDS.

I. SPLEEN, ETC.

1. *Fibroid degeneration of the capsule of the spleen.*

This specimen was removed from a female received into the dissecting-room, attached to the Charing Cross Hospital. She was 86 years of age, and her death was the result (as stated in the certificate), of senile decay. The body was greatly emaciated. The lungs were healthy. The visceral and parietal layers of the pericardium were, in some parts, intimately adherent to one another. The heart was small and flabby; the muscular structure pale and degenerate; the mitral and aortic valves thickened and stiff—particularly the former; those of the right side, normal; the coronary arteries, in many parts, calcified; the arch of the aorta considerably affected by calcareous and fatty degeneration. It may be stated, that there was a well-marked circulus senilis of the cornea.

The *spleen* was much atrophied, of flaccid consistence, and pale colour. (Woodcut 20.) On its convex surface, chiefly, are seen large patches, of a light, yellowish-white hue, raised above the general level, and each presenting minor elevations, as seen in the figure. Very numerous, also, are similar small patches, around and between the larger ones; they assume, for the most part, the circular form. All have the consistence and elasticity of cartilage. On cutting them, likewise, the impression is given of making a section of that substance. Dr. Baillie,* indeed, describes the above condition as "coats of the spleen *cartilaginous*," and observes that "this disease may be considered, in a great measure, as peculiar to the spleen. It is, at least, much more common in this viscus than in any other."

I have myself frequently seen this peculiarity of the splenic capsule, and have, almost invariably, noticed it in aged subjects, where the spleen is small, and with similar or other forms of degeneration existing in various textures of the body, but more especially in the skeleton of the larynx, the heart-fibre, and the arterial tunics. Even the calcareous variety of degeneration may invade the capsule of the spleen, as we learn from Morgagni (Epist. x., Art. 19, and Epist. xiv., Art. 23). This latter state is, certainly, to be considered as exceedingly rare. An example of it, however, is preserved in the Museum of the Charing Cross Hospital. Dr. Crisp† speaks of *bony* and *cartilaginous* deposits

* Morbid Anatomy, p. 172, Lond, 1793.

† On the Structure and Use of the Spleen, p. 166. Lond.

Digitized by Google

being not uncommon on the capsule of the spleen in old persons; and adds, "I have never seen this in the lower animals, but, in a leucoryx

Woodcut 20.

Represents the atrophied condition of the spleen, with the light-coloured, nodulous patches upon its capsule.

I found bony tumours in the organ, and a large amount of bony and cretaceous deposit in the lungs." Drs. Jones and Sieveking* are inclined to believe that fibroid thickening of the capsule takes place, generally, on the inner surface of the latter, at the expense of the parenchyma of the organ.

Although many specimens of various forms of disease of the spleen, and deposits in its substance are recorded in the "Transactions" of the Pathological Society of London, I believe that the present variety of affection of its capsule is the first specimen of the kind which has been

* Manual of Pathological Anatomy, p. 583. Lond., 1854.

Digitized by Google

brought under the notice of the Members; and with a view to render the consideration of it more complete, Dr. Bristowe has kindly favoured me with the following report of its microscopic characters:—

"The thick old false membrane, so often found in patches on the surface of the spleen, is extremely simple in structure.

"To the naked eye, it has a close uniform texture, at first sight greatly resembling that of hard-boiled white of egg; but it is infinitely tougher, and cuts not unlike cartilage. It is, however, stratified, and this in a direction parallel with the surface of the spleen; and it admits, without difficulty, of being peeled off in successive layers.

"Microscopical examination confirms, but adds little to, the above account. The inspection of a thin vertical section conveys the idea that the structure is a fibroid one. (Plate XII., Fig. 1 *a*). Thus viewed, the false membrane seems to be made of bundles of fibres of nearly uniform dimensions, with a slightly and irregularly wavy, but essentially straight and parallel, course. These fibres are almost perfectly distinct from one another; but not quite so, for, although the continuity of individual fibres may be, for the most part, readily traced, adjoining ones appear occasionally to be connected by oblique cross-bands of somewhat smaller diameter than themselves. Further, when fibres became mechanically separated, their edges present a ragged appearance, which seems due to the tearing of numberless delicate fibrilliform adhesions existing between them. But on making other than vertical sections, the fibroid character disappears. The examination of oblique sections, (Fig. 1 *b*), and still better that of small fragments which have been peeled off, show conclusively, that the fibroid appearance is an accidental one; and that, as in the case of the hydatid membrane or of the leaves of a book, the "fibres" are merely the cut edges of a series of parallel membranes. The membranes themselves, are almost entirely structureless; or at most present a very indistinctly fibrillated and granular character. Here and there, indeed, more distinct fibre-like markings may be seen, but these are obviously due either to creasing, or to the accidental exposure of the torn or cut edge of a lamina, or of an anastomosis between contiguous laminæ. No nuclei or cells of any kind are visible. Acetic acid readily causes the layers of membrane to swell up, and renders them perfectly transparent, uniform, and structureless. (Fig. 1 *c*.) It shows, too (what may be seen, but less satisfactorily, under other circumstances), that the intervals between them are studded irregularly with clusters of minute non-polarizing oil-globules.

"The false membrane above described, is, I believe, structurally identical with the almost similar membrane occasionally found on the surface

Digitized by Google

of the lungs, liver, and other viscera. In its pseudo-fibrous, but essentially laminated, character, it has also a very close resemblance to certain fibrinous casts of the bronchial tubes (See report by myself, Path. "Transactions," Vol. V., p. 43). Further, some natural structures, such as the cornea, are not at all unlike it, in their ultimate microscopical elements, and in their arrangement.

"Whether, in the case of the false membrane, the stratified character is due to its deposition in successive layers, or to some other cause, such as the reaction between the contractile force of the membrane, and the opposing tendency in the subjacent viscus, I do not venture to decide."

Mr. CANTON, *1st of April*, 1862.

---

2. *Hypertrophy of the spleen, with thick fibrous deposits on its entire convex surface.*

J. H. B., æt. 55, had been under treatment with diarrhœa for five months, and became convalescent. A week later, the diarrhœa returned, through his intemperance, and it was associated with hæmatemesis. He complained of pain in the right side of his chest, which was due to an attack of pneumonia, and his complexion was yellow. Two days afterwards, in the evening, he vomited a great deal of blood, became very low, and died about ten o'clock.

Post-mortem examination.—Besides hepatisation of the right lung, it was firmly adherent to the pleura throughout, and small tubercles were beginning to form in both lungs; the liver was cirrhosed, contracted, and here and there its surface was covered with small fibrous tubercles; the gall-bladder was colourless and empty. The spleen was more than double the natural size, its entire convex surface being covered with a dense and firm fibrous material, in some places half-an-inch thick; its proper structure was altered in colour, and had a few whitish deposits of fibrine; its capsule was partly adherent to the diaphragm. The stomach contained a gallon of blood, chiefly in coagula, which explained the emptiness of the vessels everywhere observed; it seemed perfectly sound, and no trace of a bleeding vessel could be discovered; a small polypus about an inch long grew from the mucous membrane, near the cardiac orifice. In the small intestines, Peyer's patches were in a state of ulceration, varying in size from pins'-heads to peas, occurring singly and in clusters. The left kidney was atrophied with a melanotic protuberance on its convex border. Dr. GIBB, *20th of May*, 1862.

Digitized by Google

3. *Atrophy of the spleen.*

H. P., æt. 67, after a persistent attack of uncontrollable diarrhœa, died from extreme emaciation and exhaustion. The stomach, small intestines, and mesentery were found in a state of inflammation, with intense congestion of the vessels and general redness. The duodenum was more involved than any other part of the alimentary canal. Both kidneys contained small cysts. The spleen, normal in colour, was the size of a small hen's-egg, and weighed half-an-ounce. The left testicle was atrophied, and hydrocele was present in the right.

When the spleen deviates from its natural size, it is usually in the form of hypertrophy; the opposite condition of atrophy is comparatively uncommon. The weight of the specimen was, as stated, four drachms; Professor Gross refers to a case he had seen, where it was not larger than a billiard-ball, but it must have weighed more than my specimen; Professor Dunglison met with a case in which the spleen was reduced to the size of a small almond; Portal refers to another not larger than a nutmeg; whilst Cruveilhier has seen it weigh scarcely a single drachm. Dr. GIBB, *20th of May*, 1862.

II. SUPRA-RENAL CAPSULES.

4. *Morbus Addisonii.*

These very marked specimens of diseased supra-renal capsules, and bronzed skin, were taken from a patient of Dr. Barker's, who died at St. Thomas's Hospital on the 19th of October, 1861. He was a boy æt. 14, who had enjoyed perfectly good health up to five months previous to his death. He then began to lose flesh, and soon after, it was discovered that his skin was getting dark. Extreme weakness and frequent vomiting were the only symptoms the patient complained of. He entered the Hospital on the 14th of October, 1861. His body was then very thin and emaciated. His voice was remarkably feeble; and he was, on the whole, so weak, that he could scarcely move. His skin, all over the body, presented a most distinct bronze colour, which was darkest on the belly and on the back. A little less dark were the thighs, the neck and the shoulders; still a shade paler, the forehead, the forearms, and the legs; and least dark, the palms of the hands and the soles of the feet. The skin of the belly and of the thighs was also desquamating. The patient felt giddy and sick to the last day; had no pain anywhere, nor any other symptom of local disease. He himself stated that, five months ago, he was a strong, rosy boy.

Digitized by Google

On the 22nd, the *post-mortem* examination was made. All the organs were found remarkably healthy, with the exception of the supra-renal capsules, which were strikingly diseased. Their substance was entirely destroyed, and they contained a quantity of granular and calcareous matter. A very few calcareous tubercles were found in the apices of the lungs.

The specimens brought before the Society, are the kidneys, with the diseased supra-renal capsules, and a piece of the skin taken from the belly. Dr. E. MONTGOMERY, *5th of November*, 1861.

---

5. *Disease of supra-renal capsules; tumour in spinal cord; chorea and incipient bronzing of the skin.*

H. M., a young woman, æt. 23, was admitted into St. Mary's Hospital, November 1st, 1861. For two years her friends had noticed a change in her disposition and impairment of health (attributed to a severe mental shock), and recently had observed that she was becoming browner. A month previous to admission, she was suddenly seized with headach and giddiness, fell down, and was unable to rise. She was confined to her bed for a fortnight, with what was called low fever, and as she recovered, found that she could not perfectly command the left arm. She gradually gained strength, but the movements of the left arm and leg continued, and after a short journey they became general, her strength also failing. In this state, she was admitted into the Hospital, extremely weak, with general choreic movements most marked on the left side. The face and arms were noted to be brown, as if tanned by exposure to the sun. There was no history of rheumatism, and the heart-sounds were normal. The chorea continued, she became weaker from day to day, vomiting after almost every meal, always peevish and sometimes violent, and she died ten days after admission.

Post-mortem examination.—With the exception of a few tubercles of yellow colour and firm consistence scattered beneath the pleura of the apices of both lungs, and slight adhesions at this part, and the condition of the supra-renal bodies, the thoracic and abdominal viscera were healthy. The mesenteric glands were, however, large.

The supra-renal capsules were large, irregular and nodulated, embedded in adherent cellular tissue. The normal structure of these bodies was replaced by an aggregation of small bodies connected by cellular tissue, varying in size from a large pea to a hemp-seed, yellow in colour, and, for the most part, firm and elastic, with a smooth and bright section. Those near the surface were the largest, and one or two had softened down into diffluent creamy matter.

Digitized by Google

The microscopic characters were small imperfect cells with granular matter, and in the softened portion, pus corpuscles.

The brain was perfectly healthy in appearance and consistence. The spinal cord was firm and healthy along its entire extent, except that on the posterior surface of the lumbar enlargement, there was a small tumour of about the form and size of a small haricot-bean. It was firm and white; the pia mater was stretched tightly over it, but a vein in this membrane appeared to pass between it and the cord. There was no undue vascularity at this part. The cord was slightly widened, but of natural colour and firmness.

On section, the tumour, which appeared at first sight to be altogether external to the cord, was found to spring from its centre. It had apparently grown backwards in the posterior fissure, and expanded on the posterior surface beneath the pia mater. By the microscope, it was found to consist chiefly of granular matter, with a few nerve-fibres and cells; much chloresterine was also seen.

Dr. W. H. Broadbent, *3rd of December*, 1861.

---

6. *Case of morbus Addisonii.*

E. A., æt. 18, was admitted into the London Hospital under Dr. Fraser's care on the 18th of February, 1862, suffering from morbus Addisonii. She belonged to a healthy family, her parents were both of dark complexion, and she and her sisters were decided brunettes; but two years ago she had suffered from a severe shock to the nervous system (in the form of a sudden fright), and since that time she had gradually become of a deep olive colour, and had been overcome by weakness of body and languor of mind.

On admission, the patient had the complexion of a mulatto, and several people, who saw her, asked, if she were not a gipsy. It appeared, however, on inquiry, that her father was a carpenter, and that her family had been settled for many generations at Cheshunt. Though the pigmentary discoloration was universal, there were, here and there, in different parts of the body, patches which were almost black. The intensity of the colour was greatest at the flexures of the joints, and over the lower half of the trunk. The conjunctivæ were of pearly lustre, but there was a distinct spot of pigment in the right eye, situated a line or two above the cornea. The labial and buccal mucous membrane had a brown tint strongly resembling the tanned appearance of a terrier's mouth, and there were some well-marked patches of darker pigment. The most careful examination failed to detect the existence of any disease of the heart or lungs, and there was no appreciable alter-

Digitized by Google

ation in the bulk of either the liver or spleen. The fæces and urine were healthy, though the former were inclined to be dry, and the latter scanty. The menses were irregular, and deficient in quantity. The blood did not contain any free pigment, nor was there any excess of white cells. The patient frequently fainted, and was much troubled with distressing vomiting. The lips became of a deep purple colour, and sordes-like matter was deposited at the angles of the mouth. The tongue, however, was quite moist, and very pale. At a very early period of her disease, her sleep was much disturbed by nightmare, but she now did not dream at all. The weakness increased daily, and the debility became so profound, that she could not even sit up in bed. Her friends removed her from the Hospital on the 4th of April, and she died on the 5th at Cheshunt Common. She was quite sensible till within a few minutes of her death. The *post-mortem* examination was objected to, but finally, a partial examination was permitted. The right supra-renal capsule was found to be a mere diffluent mass, surrounded by strong adhesions, which firmly connected together the liver, diaphragm, kidney, and supra-renal capsule. The left-supra-renal capsule, which was exhibited before the Pathological Society, was also connected by dense adhesions to the diaphragm and spleen, and the close union which existed between it and the kidney (which had not been disturbed) could be well seen. Microscopic examination failed to discover a vestige of the true glandular structure, and there remained nothing but a strong fibrous envelope, containing pus, and a small amount of cretaceous matter. The kidneys, spleen, and uterus were quite healthy. The colon, throughout the greater part of its extent, was loaded with scybala. The other organs could not be examined.

Dr. LITTLE, for Dr. MACKENZIE, *15th of April*, 1862.

---

7. *Alteration of size and structure in the renal capsules.*

This case occurred in the practice of Mr. Barnes of Chelsea. The patient, a man about sixty years of age, had been under his care eighteen months; he complained of weariness, lassitude, general debility and frequent sickness; the bowels were often constipated, but sometimes relaxed; he did not appear to benefit by medical treatment; there was no organ that appeared to be specially affected, death taking place from gradual sinking, without any visible cause. The skin, when the patient was first seen, appeared to be of a peculiar colour, not positively bronzed, but the colour was one that Mr. Barnes had not observed before, and his son, Mr. Herbert Barnes, who often saw the patient,

Digitized by Google

and who had seen cases of disease of the renal capsules, with discoloration of the skin, in Guy's Hospital, believed that these organs were affected. The kidneys were sent to me on the day of the *post-mortem* examination; Mr. Barnes and his son not having found disease of the viscera, all of which, with the exception of the brain and kidneys they had examined.

Both kidneys were enveloped in fat; the right weighed four ounces one hundred and twenty grains; the left two ounces one hundred grains. A part of the left capsule had been torn off; but, judging from the portion remaining, which weighed twenty grains, it must have been very small, not exceeding forty grains in weight; it was very thin, with very little medullary substance; this, and the cortical portion, contained abundance of fatty matter. The left kidney was entirely covered with fat; this substance, at the upper part, being one inch and a-half in thickness. In the usual situation of the capsule, was a small body, of a like shape to the capsule, weighing only thirteen grains; on a careful microscopic examination of this body, I found it to be composed almost entirely of flakes of fat covered with cellular tissue.

Remarks.—It is not intended to adduce this case as one of discoloration of the skin from capsular disease, or from partial impairment of the function of these organs, but I have thought it worthy, though incomplete, to be placed before the Society, as it is only by the accumulation of such cases, and deductions from them, that useful conclusions can be arrived at. The only body in the place of the left capsule, or near to it, was the one I have named, but its structure differs entirely from that of the capsule in a normal state; indeed, it is doubtful, whether the capsule (if one existed?) was removed from the body. In the Prize Essay on the Structure and Use of the Renal Capsules, by Dr. Harley, now at the College of Surgeons, a table is given of fifty-seven cases. Of these, in fifteen, there was bronzed skin, with disease of the renal capsules; in thirty, the capsules were diseased without bronzing of the skin; and in twelve cases, bronzing of the skin occurred without disease of the organs. But I may remark, that Dr. Addison's cases (eleven), are omitted, and that in Guy's Hospital, out of thirty specimens of capsular disease, twenty of the patients had bronzing or discoloration of the skin; so that, I think, the matter yet requires very careful investigation. Dr. Crisp, *20th of May*, 1862.

Digitized by Google

X.—MISCELLANEOUS SPECIMENS.

1. *Specimens of syphilitic disease of the dura mater, liver, and diaphragm.*

Case I.—*History.*—A. F., æt. 27, was admitted into the Middlesex Hospital, under Dr. Stewart, on the 22nd of October, 1861. She had always enjoyed good health, up to the time of her marriage, at the age of twenty. Soon after her marriage, she contracted syphilis from her husband, which was followed by ulceration of the throat, copper-coloured eruptions, pains and tenderness of the scalp, and loss of hair. She had an ulcerated sore-throat, three months after marriage, while pregnant. Seven months after marriage, she was delivered of a dead putrid fœtus. Twenty-two months after marriage, she was delivered of another premature child, which survived. Six months after this, she had a second miscarriage, and two more within the subsequent year. During the greater part of this time, her skin was marked by copper-coloured eruptions. Soon after the last of the above-mentioned miscarriages, the patient had three epileptic fits in one night. She never had fits of any kind before; but for some time previous to their first appearance, she had complained of vertigo, dimness of sight, and headach. The fits recurred, at intervals of from a week to a month. The patient suffered from intense headach, chiefly on the right side, and at the occiput, and from loss of memory. She had frequent fits after admission into the Hospital, some of which, but not all, were characterized by general convulsions and foaming at the mouth. After many of the fits, the patient continued for several hours in a semi-conscious state; but, when sensible, she always complained of intense pain in the head. The face was observed to be puffy, there was slight œdema of the legs, and a considerable quantity of albumen in the urine. The patient gradually became weaker. On November 10th, she was attacked by intense pain and tenderness all over the abdomen, vomiting and diarrhœa; the pulse was 160, the respirations 64. The prostration rapidly increased, and on November 12th, death occurred, the consciousness remaining clear almost to the last.

Post-mortem appearances.—Body moderately-well nourished. Half-an-inch of subcutaneous fat over the abdomen. Slight œdema of legs. Several circular, superficial cicatrices, up to the size of a shilling, over legs and thighs. No obvious cicatrices on vulva, or in vagina, or in groin.

On the right side of the frontal bone was a patch, about the size of

Digitized by Google

a florin, where the osseous tissue was much lighter in colour, and of a more spongy character, than the rest. This patch appeared to bulge very slightly inwards, and was partly surrounded by an injected rim. The pericranium over it was rather firmly adherent; the corresponding dura mater was slightly increased in opacity, but not at all adherent or rough; the subjacent brain was normal. On the left side of the frontal bone, commencing in the orbital plate and extending upwards, was another patch, the surface of which was much roughened and irregular. The skull-cap, for two or three inches further back, on the left side, was light and spongy, and at some places so soft, as to retain impressions made with the finger-nail. The dura mater at this part, especially anteriorly, where the bone was rough, was firmly adherent to the skull-cap. This portion of the dura mater, covering the anterior half or more of the left hemisphere, and measuring four inches from before backwards, and three inches outwards from the longitudinal sinus, was fully one-third of an inch thick, from the deposit of a morbid material on its under surface gluing this to the brain. This deposit was pale-yellow, opaque, and tolerably firm; it yielded no juice, and under the microscope, presented a fibrillated tissue, with a few nuclei, and numerous minute oil-globules. This morbid material could not be detached from the dura mater. The grey matter was mostly absent over the subjacent brain. Pia mater moderately injected, and sinuses full of dark, soft coagulum. Puncta vasculosa numerous.

There was nothing very abnormal in the appearances, presented by the heart and lungs.

Intense bright-red injection of peritoneum; and intestines glued together by soft yellow lymph, with nearly two ounces of fluid pus in cavity of pelvis.

Liver considerably enlarged, not pale, but very flabby. Under the microscope, the quantity of oily matter in the secreting-cells was found to be much increased. The upper and under surfaces of the right lobe were marked by several superficial, radiated, cicatrix-like depressions. Four of these were situated on the upper surface, near the anterior margin; and three, on the lower surface. About the middle of the posterior margin of the right lobe, was a knotty tumour, about the size of a large walnut, apparently growing from the capsule and encroaching into the substance of the parenchyma. This tumour was firm and pale-yellow, with numerous white septa running through it. It yielded no juice, and was made up of a fibrillated tissue, oil-globules, and granular matter; the septa consisted of white fibrous tissue.

Another similar deposit, the size of half a large orange, was embedded

Digitized by Google

in the substance of the diaphragm, and projecting downwards, established an inseparable connection between the left lobe of the liver and the spleen.

The spleen was fully four times its normal size and very soft.

Right kidney, six ounces and a-half; left, six ounces; surfaces slightly granular; cortices hypertrophied, measuring four or five lines in thickness, pale-yellow, and opaque; renal epithelium very granular, and at many places loaded with oily matter.

The other organs were normal.

Case II.—*History.*—H. T., æt. 36, was admitted into the Middlesex Hospital, on November 20th, 1860, under the care of Dr. Stewart and Mr. Shaw, and died on December 25th. She had been always well until her marriage, fourteen years before. She contracted syphilis from her husband directly after her marriage, and after this, she had repeated attacks of copper-coloured eruptions, and for some months before admission she had suffered from periostitic nodes, and from gnawing pains in the left side of the head. After admission, a node was observed on the left side of the frontal bone, and another, on the posterior part of the left parietal bone, extending to behind the left ear. Intense pain in the forehead and occiput, aggravated at night, was complained of. The pulse was 120; and the patient suffered from sickness and loss of appetite. During the last fortnight of her life, she had frequent "fits" of loss of consciousness, commencing with a scream, and characterized by loss of consciousness, but not by foaming at the mouth or by convulsive movements. These "fits" increased in frequency and severity until the patient's death, while in the intervals she suffered from intense pain in the forehead and occiput.

Post-mortem appearances.—Body emaciated. The pericranium above the left temple, and also posterior and superior to the left mastoid process, was thickened over a space, about equal to the size of a florin, in each locality. The subjacent bone, in both of these places, was much more vascular than that forming the rest of the calvarium. On the inner surface of the bone, corresponding to the vascular space behind the mastoid process, was a patch, about the size of a crown-piece, where the bone was likewise much increased in vascularity, and at the same time roughened. The dura mater was here rather firmly adherent. On attempting to remove the brain, the left hemisphere of the cerebellum was found to be so firmly adherent to the dura mater, that a portion of the organ was torn off and left behind. The dura mater, behind the petrous portion of the left temporal bone, extending over

Digitized by Google

the occipital bone, as far as the mesial line, was greatly thickened from the deposit, on its cerebellar surface, of flattened masses of a firm yellowish-white substance, exhibiting a smooth surface on section, and yielding no juice. This deposit extended, at some places, fully half-an-inch along the under surface of the tentorium, at its attached margin. The left lateral sinus passed through the diseased mass, and its canal was quite obliterated. There was no thickening or opacity of the membranes covering the hemispheres, and no increased vascularity of the pia mater. The internal surface of the bone, corresponding to the diseased dura mater, was everywhere rough and very vascular. The cranium generally was thicker and denser than natural, the thickness of the occipital protuberance amounting to five-twelfths of an inch.

On microscopic examination of the morbid deposit in the dura mater, it was found to consist of an obscurely fibrillated tissue, interspersed with minute granules and oil-globules.

The lungs and heart were normal.

The liver weighed sixty ounces. It was firmly adherent to the diaphragm and to the surrounding organs. Its whole surface, but more particularly the under surface of the right lobe, in the neighbourhood of the gall-bladder, was marked by deep cicatrix-like depressions, some of them extending fully half-an-inch into the substance of the liver, and dividing it into numerous small lobes. Many of these depressions were more or less radiated, and on making a section through them, they were seen to consist of firm, white fibrous tissue, extending from the capsule into the parenchyma.

The kidneys were both hypertrophied, the left weighing eight ounces and three-quarters, and the right eight ounces. Their capsules were non-adherent and their surfaces quite smooth. Their structure was extremely dense, of a brownish-pink colour and semi-translucent (amyloid or waxy).

The spleen weighed four ounces and a-quarter, and presented nothing abnormal.

Case III.—R. B., æt. 42, died in the Middlesex Hospital, on 27th of September, 1861, from an aneurism of the superior mesenteric artery bursting into the duodenum. Shortly before his death, this man had suffered from syphilitic periostitis of the tibiæ and other bones.

The liver was firmly adherent to the diaphragm and to the surrounding parts. The capsule was much thickened. The outer surface was marked by numerous, deep, cicatrix-like depressions, and embedded in some of

Digitized by Google

these cicatrices was a "fibroid nodule," about the size of a pea, presenting the same appearances, to the naked eye and under the microscope, as the bodies found in the liver of Case I.

Remarks.—The subject of syphilitic fibroid deposits in the internal organs, has been repeatedly brought before the notice of the Pathological Society, by Drs. Wilks and Bristowe and by other Members. (See "Transactions," VIII., 240; IX., 270; X., 22; XI., 2; XII., 216.) The above cases confirm, in a remarkable manner, the observations which have already been made, although it may still be a subject for investigation, whether other morbid states of the constitution, besides syphilis, may not give rise to similar lesions. In Case II., there was an evident connection by continuity, between the disease of the dura mater and the periostitic nodes external to the bone. In Case I., the lesion of the dura mater was diagnosed during life. Dittrich and Wedl (*Wedl's Pathological Histology*, Syd. Soc., Transl., 1855, p. 432) were among the first to point out the dependence of the fibroid nodules and cicatrix-like depressions of the liver upon constitutional syphilis, and more recently the existence of syphilitic diseases of the liver has been dwelt on at considerable length by Professor Frerichs of Berlin (*Klinik der Leber-krankheiten*, Syd. Soc., Transl., Vol. II., p. 154, *Atlas*, Pl. IV.). According to Frerichs, syphilis may induce three different morbid conditions of the liver:—1. Interstitial hepatitis and peri-hepatitis, ending in the formation of the cicatrix-like depressions. 2. *Hepatitis gummosa*, or the formation of fibroid nodules; and 3, he believes constitutional syphilis, to be one of the causes of the amyloid or waxy degeneration. It is worth mentioning, that out of two hundred and sixty *post-mortem* examinations, performed by myself at the Middlesex Hospital, the cicatrices and fibroid nodules were only found in four cases, and that all four patients had suffered from syphilis.

In connection with the cases above detailed, it is worth observing, that I have on several occasions met with patients, who were seized with epileptic fits *for the first time*, while suffering from symptoms of syphilitic periostitis of the scalp and other symptoms of constitutional syphilis, and in whom iodide of potassium effected a cure, both of the periostitis and of the epilepsy. The following are brief notices of two such cases:—

Case IV.—J. G., æt. 47, a bargeman, came under my care, as an out-patient at King's College Hospital, on November 23rd, 1856. He was a robust, well-built man. Three years before, he had contracted a chancre, which was followed by bubo and cutaneous eruptions. Three months

Digitized by Google

before, he began to suffer from painful nodes on the scalp; and about the same time, he was attacked with epileptic fits (with unconsciousness, convulsions, biting of tongue, and foaming at mouth), for the first time in his life. The fits recurred about twice every week. When he came under my observation, the only indication of disease that could be discovered, was the existence of several large, very painful nodes, on the calvarium and tibiæ. The pain was often intense, especially at night. Iodide of potassium was prescribed, in doses of five grains, three times in the day, and this treatment was persisted in for upwards of two months. Under this treatment, the pains, nodes, and epilepsy, all disappeared. The last fit took place on January 7th, 1857; and there was no recurrence, although the patient was kept under observation for six months.

Case V.—M. R., æt. 43, a stout, robust man, came to consult me on September 8th, 1856. Twenty years before, he had contracted a chancre, which was followed by bubo, sore-throat, cutaneous eruptions, and painful swellings in the scalp and shins. Nine years before, he began to suffer from well-marked epileptic fits, which sometimes recurred, as often as five or six times in the week. He had scarcely ever been a week without a fit. Occasionally, the fits were followed by temporary hemiplegia, on the left side. When the man came under my notice, he complained of a fixed pain in the right side of the head. Iodide of potassium was prescribed, in doses of three grains three times in the day. This treatment was continued for nearly four months. The pain in the head ceased, and the fits diminished greatly in frequency. The last fit occurred on April 12th, 1857; and there was no repetition, during the following two months that the patient remained under observation. Dr. Murchison, 19*th of November*, 1861.

---

2. *Casts of diseased teeth.*

Mr. Barwell exhibited casts of diseased teeth from the mouth of a boy æt. 18. The boy was stunted in growth and old-looking. The teeth (except the molars) were mere pegs rising at wide intervals from the gums; the upper jaw contained only nine teeth. On the right were one incisor (central), one canine, one bicuspid, and one molar; on the left were two bicuspids, otherwise the same deficiency as on the right side. The upper incisors were plainly, though not deeply, notched at the edge, and grooved longitudinally; they were large in proportion to the other teeth, inclined forward and divergent.

Digitized by Google

The canines and bicuspids were cragged and stunted. In the lower jaw were only eight teeth; one incisor, one canine, and two molars on each side; the first two named being cragged and misshapen. The boy's mother was questioned, and denied all knowledge of any communicable disease, either on her own side or on that of her husband; but the father confessed that a little less than a year before the boy's birth he had an eruption of syphilitic origin.

Thus, here was the case of a lad presenting an unhealthy, stunted, and prematurely-old appearance, in whose history hereditary syphilis was distinctly traceable, and whose teeth were remarkably undeveloped, stunted, and malformed; but which, according to Mr. J. Hutchinson, the originator of the syphilitic teeth theory, did not bear that peculiar mark and mien which distinguish the so-affected teeth. Mr. Barwell stated that he had given some little attention to this subject, and deformed teeth had been much thrust upon his notice. He knew one or two cases, in good families, of persons whose upper central incisors were notched and marked in the manner supposed to be diagnostic of syphilis, yet in whose parents that disease had never existed. And in the instance now brought before the Society, is a case of malformation of teeth combined with syphilitic history and appearance, and yet the particular shape of the deformity is pointed out as non-syphilitic.

The exhibitor desired to call the attention of the Society to the method of diagnosis employed in this matter of syphilitic teeth as contrasted with that used in other diseases. In determining the nature of any malady, a vast number of circumstances are taken into consideration, all notions inconsistent with those circumstances are eliminated, while all consistent ones are retained; the number of probable events is thus gradually reduced, until we fix upon the one disease which alone agrees with the conditions of the case. But, in diagnosing a syphilitic diathesis from the shape of the teeth, we are told that two teeth only are of any value for the purpose, and that when these have a certain, not very distinctive, peculiarity of form, judgment may be given upon that evidence alone. The method is, at the same time, too gross and too minute—too gross, because only one circumstance, affecting but a very small portion of the body, is taken into consideration; too minute, because two or three peculiarities of shape have to be distinguished from a number of very similar forms, and this without any other guide. Mr. Barwell submitted, that medical science should be even more cautious than usual, in forming conclusions that would affect the moral status and condition of very many individuals; that before fixing upon any set of persons the stigma of hereditary syphilis,

Digitized by Google

or of begetting syphilitic offspring, there should be found some more comprehensive and wider indication of such taint, than a peculiarity of deformity in two of their teeth.

Mr. BARWELL, *3rd of December*, 1861.

---

3. *Case illustrating contagion between tinea tonsurans in a child and pityriasis versicolor in a young adult.*

A little boy, of two years old, was under my care on account of rickets, and suffering also from ringworm on the scalp. The patches on his head were exceedingly well-marked, so much so that I had a sketch taken of them, and several times brought the case forward as a clinical illustration of the disease to my class. The scales on them abounded in fungus-spores, and the hairs were infiltrated and broken. The disease had previously affected his brother and sister.

This boy had been under my care for several months, when one day his nurse, a fair-skinned, very healthy young woman of about nineteen, told me that she had some patches on her chest. She showed me a group of small patches of pityriasis versicolor between her breasts. The colour and general appearance of these patches were quite characteristic, and not in the least like ringworm. The cases were seen by many, and sketches of both were exhibited to the Society.

I learnt from the nurse that the boy had always slept with her, and that he very frequently rested his head in her bosom.

This case is the seventh, or eighth, in which I have observed the coincidence of ringworm of a young child's scalp, and pityriasis versicolor on the chest of the nurse, and in which the relative duration of the two diseases favoured the belief that the latter had originated by contagion from the former. I have also in one instance succeeded, by artificial means, in thus producing pityriasis in the chest of an adult.

Mr. HUTCHINSON, *17th of December*, 1861.

---

4. *Artificial jaundice.*

The experiments, related to the Society, were made with the view of ascertaining the source of the tyrosine and leucine, met with in the urine of the case of complete obstruction of the bile and pancreatic ducts, given at p. 118.

Artificial jaundice has frequently been induced in animals, either by ligaturing the gall-ducts, or by injecting bile into the circulation. But

Digitized by Google

on the present occasion both of these methods were objectionable; the first, on account of the constitutional disturbance induced by the severity of the operation; the second, from the bile being all at once thrown into the circulation, and producing toxic effects, besides its being too rapidly eliminated by the urine. Another plan was, therefore, devised, which approached much nearer, than either of the above, to the state induced by disease in man. The author took the bile of three healthy dogs, and injected it under the skin of the back of a fourth dog. In this case the effects of the operation were almost *nil*, and the bile was at the same time placed in a position favourable for its slow absorption, just as occurs in the human subject, when from any cause its flow into the intestines becomes interrupted.

During the first two days, the animal remained comparatively well, the urine was normal, and contained neither bile-pigment nor biliary acids. On the third day, however, the animal became ill; and on the fourth jaundice set in. He died on the fifth day. On analysis, the urine, found in the bladder after death, was ascertained to contain not only the pigment and biliary acids, but also the abnormal products, leucine and tyrosine; and, what was more remarkable and interesting still, the urine was at the same time loaded with sugar, just as is occasionally met with in the human subject. The urine, containing the crystals described, was exhibited under the microscope to the Society.

From this and other experiments of a somewhat similar nature, the author is led to believe that tyrosine and leucine are derived from the metamorphosis of the two bile acids.

Dr. George Harley, *4th of February*, 1862.

---

5. *Casts of teeth illustrative of the influence of hereditary syphilis.*

Mr. Nunn exhibited four casts, with special reference to the upper central incisors—the teeth said by Mr. Hutchinson to be "the test teeth as regards hereditary syphilis."

In the two first examples, from females, respectively æt. 8 and 14, and undoubtedly the inheritors of syphilis, one presented the *typical* appearances, the other did not do so.

In the other two examples, both presented the typical peculiarities. One was from a female æt. 9, the inheritor of syphilis (the peculiarities being very marked); the other from a young man æt. 19, who had never suffered from infantile syphilis in any shape (the peculiarities being less marked, but distinctly present), and whose mother, as far as

Digitized by Google

could be ascertained (even by a personal interview), had never been affected with syphilis. The subject of the cast, it may be well to state, when between three and four years old, had had a severe attack of inflammation of the chest.

The conclusions, Mr. Nunn believed might be drawn, were, that a child the subject of hereditary syphilis might not betray that disease in its teeth; and secondly, that faults of conformation in the upper central incisors, similar to those induced by constitutional syphilis, might exist without the subject of them ever having suffered from hereditary syphilis. Mr. NUNN, 18*th of February*, 1862.

---

6. *Extensive false membrane in a case of diphtheria.*

This specimen was exhibited as showing, in a typical manner, the characteristics of the false membrane in a severe case of diphtheria, and as illustrating the great extent of surface covered by the exudation.

It was taken from a child six years old, who died on the sixth day of the disease. Tracheotomy had been performed with very great temporary relief, but the patient died twenty-four hours after the operation.

The false membrane extended down the trachea, and to the bronchi of the second and third diameters; it also lined the pharynx and the nares. In the trachea it formed a perfect cylinder, and was tough, while it became less cohesive, and more pultaceous-like, as it was examined lower down the bronchial tubes. The mucous membrane of the trachea and of the bronchi was, at least in some parts, redder than in the normal condition; but over the greater part of the pharynx, the mucous membrane appeared fully as pale as natural, when the false membrane was raised from off it. Dr. HARE, 18*th of February*, 1862.

---

7. *Syphilitic psoriasis of the nails.*

Occasionally, but I think very rarely, in the course of secondary syphilis, we see the nails involved in the cutaneous disease. In Fig. 4 of Plate XIV. is shown a good example of this. The patient was an old woman who had married for a second time at the age of sixty-four, and had received primary syphilis from her husband. At the time her nails suffered, she was under my care at the Ophthalmic Hospital for double iritis, and had also a copious rash of psoriasis. It was about two months subsequent to the primary sore. It was a singular fact that the nails of the right hand and right foot were all affected, those

Digitized by Google

of the left extremities being quite free. The nails of the toes showed precisely similar conditions to those of the fingers.

The disease consisted in a splitting up of the superficial lamellæ of the nails, leaving them in a ragged, broken condition, and much discoloured. There was no evident inflammation, and the matrix did not appear to be specially affected. There was no tendency to exfoliation of the nails. Mr. HUTCHINSON, *4th of March*, 1862.

8. *Diseased conditions of the nails consequent on inherited syphilis.*

The subjects of inherited syphilis are, according to my observation, liable to several distinct forms of disease of the nails, occurring for the most part at very different ages.

In early infancy (from one month to a year old), during the period at which cutaneous rashes, snuffles, iritis, condylomata, &c., are most commonly met with, there not unfrequently occurs a form of subacute onychia, attended by a certain amount of inflammation, attacking many fingers at the same time, and ending in the exfoliation of the affected nails. This affection is almost always accompanied by psoriasis, or papular rash, in a severe form. It is probably analogous with psoriasis of the nails in the adult, and is a symptom belonging to the secondary class.

At a much later period of life, about or after the age of puberty—at the age at which keratitis, deafness, nodes, &c., are usual—these patients become liable to another form of disease of the nails. In it there is little or no evidence of inflammation, no pain, no tendency to exfoliation. The superficial layers of the nail only are affected. The disease begins at the root of the nail, and a semilunar furrow is seen extending across it. The outermost layer is destroyed over the entire lunula, and a ragged border overhanging that part is presented by the distal portion. By degrees, as the nail grows, the diseased margin is pushed further and further on. The nails appear to be dry and brittle in texture, as is shown by the fissured and broken condition of their free edges. Several nails are attacked at the same time, and the processes are always very slow; they are usually symmetrical.

The form of disease to which infants are liable is well illustrated in Figs. 1 and 2 of Plate XIV. In the first of these, the nails of the fore- and middle-fingers are in process of exfoliation, and exhibit a peculiar shape which I have often seen in this affection, as if they had been pinched laterally by forceps. The nails of the thumb and ring-finger are also compressed somewhat in the same manner, though with little or no evidence of inflammation. It is evident that the disease which

Digitized by Google

Digitized by Google

DESCRIPTION OF PLATE XIV.

Illustrating Mr. Hutchinson's Observations on Syphilitic Affections of the Nails. **(See p. 260.)**

Fig. 1. Represents onychia of several fingers, occurring in a child, aged ten months, who was the subject of inherited syphilis. (See p. 261.)

Fig. 2. The nails of an infant, aged six weeks, who died of marasmus, the result of inherited syphilis. (See p. 261.)

Fig. 3. Shows a rare form of disease of the nails, which sometimes occurs in the subjects of inherited syphilis, about or after the age of puberty. (See p. 261.)

Fig. 4. Illustrates psoriasis of the finger nails consequent on acquired syphilis in an adult, and occurring in conjunction with general psoriasis and with iritis. (See p. 259.)

Digitized by Google

Digitized by Google

Digitized by Google

produces this change of shape must affect the matrix. This form of infantile syphilitic onychia usually occurs in the toes as well as the fingers; and, when well-marked, may become of diagnostic value. It is rare, however, that its aid in diagnosis is required, since it seldom occurs, except in infants who are suffering very severely from the virus, and display other and more reliable symptoms at the same time.

The nails shown in Fig. 1 are from a child of ten months, who had suffered from skin-eruption from the age of six weeks. Those sketched in Fig. 2, are from the hand of an infant of two months which died of syphilitic marasmus, with, also, extensive waxy disease of the liver.

In Fig. 3 is delineated a good example of the second form of disease of the nails which I have described. The patient was a woman of twenty, under my care at the Ophthalmic Hospital, on account of interstitial keratitis. Her incisor teeth were typically malformed, and her physiognomy was most characteristic. There was also a clear history. Her nails had been affected for about a year; the conditions were exactly similar on the fingers of the two hands. I have met with this state of the nails so rarely, that I cannot attach any value to it as a diagnostic symptom. As a rule, the subjects of inherited syphilis, after infantile periods, do not present any special liability to disease of the nails. I have very often looked for it, and very rarely with success.

Mr. HUTCHINSON, *4th of March*, 1862.

---

9. *Diphtheria associated with parotitis; recovery.*

Mrs. W., æt. 27, pregnant six months with her third child, consulted me in January for sore-throat. When first seen she had been ill two days, with the general symptoms of cynanche tonsillaris, associated with cynanche parotidea. The throat itself could not be seen, from the great swelling of the back of the tongue and the resistance offered by the patient. Two days after this she was extremely low, and sent for me in a great hurry. The throat could now be seen, and a diphtheritic membrane covered the pharynx, soft palate, and tonsils; and the symptoms generally of diphtheria appeared to be well marked. The swelling of the parotid gland was still persistent, and added very much to the general discomfort. Under treatment, in the course of five days, she was comparatively well. Under the microscope, the exudation consisted of masses of epithelial cells, varying in form, mixed with granules; and it could be split up into several layers.

This was the first case I had noticed of the simple form of diphtheria being complicated with inflammation and enlargement of the parotid

Digitized by Google

glands. This condition is seen occasionally in the croupal form of the disease. The urine at one time was albuminous, but the recovery has been permanent thus far. Dr. GIBB, *4th of March*, 1862.

---

10. *Impregnated ovum discharged three or four weeks after conception.*

C. D., married twenty-four years, æt. 46. Prior to the birth of her first live-born child, in her twenty-third year, she had three premature births. The last, and ninth live-born child, was born 28th March, 1860, and died April, 1861, having been suckled the whole time. After its death her catamenia returned with their wonted regularity, up to the 25th of January, 1862, when, what she considered to be the courses, appeared one week beyond the usual time. She noticed on that occasion the absence of a continued flow; and, instead of it, occasional gushes of blood with coagula, accompanied with great pain, which lasted till the 28th of January, in the morning, when she felt something pass from her with great forcing pain. Upon examination it was found to be an ovum of three to four weeks' gestation, with a portion of the decidua.

The interest of the case consists in the completeness of the specimen at that period of life, and in the circumstance, that on the earliest three occasions, and on the last, the uterine powers had proved insufficient, in consequence of impregnation having occurred at a too early, and again at a very late, period of her life. Dr. SCHULHOF, *4th of March*, 1862.

---

11. *Intense bronzing of the skin. Healthy supra-renal capsules.*

The patient, from whom the specimens came, was a woman, æt. 64. She was first brought under my notice by Mr. Henry Thompson in April, 1858,—exactly four years ago—at which time her face, arms, and trunk, down as far as the thighs, were of a dark bronze-colour, with the single exception of a spot on the breast, about three inches square, which presented a marked contrast to the surrounding skin. This was the cicatrix to a burn, caused in early life by boiling water, and, while all around was bronzed, it alone retained the natural white-colour. The feet, ankles, and legs, up as far as the thighs, were also fair-complexioned. The woman was under medical observation during the last four years. She had occasionally suffered from hepatic symptoms, associated with gastric derangement, and during the latter weeks of her life, from vomiting, diarrhœa, and great debility, which ended in convulsions; during one of which, she expired on

Digitized by Google

March the 5th, 1862. The portrait exhibited to the Society was taken in April, 1858; and it would seem that at least some of the medical gentlemen, who had seen the case, had no doubt of its being one of Addison's disease; for in the surgeon's note to Mr. H. Thompson, informing him of the patient's death, he says, "the woman Lewis, suffering from disease of the supra renal capsules, died," &c.

Mr. Fuller made the *post-mortem* examination of this interesting case (at which I was also present) on the following day. The bronzing of the skin was as deep, if not deeper, than when the portrait was taken. On removal, the supra-renal capsules were found perfectly healthy as regards size, weight, colour, and microscopic appearances. The skin, when examined microscopically, was ascertained to have the usual dark pigment-deposit in the rete mucosum, and had the supra-renal capsules but been diseased, the case would, no doubt, have been considered a typical one of Addison's disease. As it is, however, it goes far to negative the opinion regarding the necessary connection between bronzing of the skin and disease of the supra-renal capsules.

There being an irresistible tendency in the human mind to allow positive, to take a much stronger hold upon the memory than negative, facts, it is not surprising that the seeing a combination of circumstances, such as bronzing of the skin and supra-renal capsular disease frequently occurring together, should make us entirely overlook and forget the numbers of times these conditions occur independently of each other. Hence arises the necessity of recording negative facts like the above, if we desire that erroneous conclusions should not be drawn from imperfectly remembered data. Dr. GEORGE HARLEY, *18th of March*, 1862.

---

12. *Cast of a supposed rupture of the upper and anterior part of the sheath of the rectus abdominis muscle.*

I was summoned, at nine o'clock in the evening of the 24th of last April, to see a man, who had been brought to the Westminster Hospital, half-an-hour previously, with an anomalous swelling at the upper part of the abdomen, which the House-Surgeon and the resident Apothecary could make nothing of.

I found the tumour represented by the cast, corresponding in situation with the upper division of the right rectus abdominis muscle, and extending somewhat beyond it externally. The patient was a thin, spare, but muscular man, and all the other divisions of the rectus were well defined through the skin. The tumour was tender on pressure, and coughing or straining caused great pain in it; it was solid and

Digitized by Google

elastic to the touch, and felt more like muscle than anything else; it was evidently a part of the abdominal wall, and not a protrusion from the abdominal cavity, for it could not be altered by pressure or position; neither were the symptoms such as would be likely to arise from the sudden occurrence of a large hernia in this situation. I, therefore, came to the conclusion that it was a muscular swelling, and the history bore out this supposition.

The man was engaged in tying up a scaffold pole, both his hands being raised for that purpose, when he suddenly slipped off the plank he was standing on, and saved himself from falling by hanging on with his hands, his body being suspended in the air. At the same instant he felt a sudden tear, "like a piece of cloth," across the upper and front part of his abdomen, accompanied with great pain; and, on being rescued from his position, he immediately divested himself of his garments to examine the part where he felt the pain, having an impression that the abdominal wall had given way; he found, however, only a swelling where he expected to see a rent.

Mr. C. Holthouse, *18th of March*, 1862.

---

13. *Arrest of growth of the radius, probably consequent on separation of its epiphysis.*

This specimen was one, which had been obtained in the dissecting-room of St. Mary's Hospital, and which had been kindly lent to me from the Museum of that Hospital, by Mr. James R. Lane. The patient was an adult man, of whom no history could be obtained. The specimen showed the radius about an inch shorter than the ulna, and articulating with a facet, on the side of the shaft of the latter bone, considerably below its head. The relative position &c., of the bones, and the shape of the extremity of the radius, are well-shown in Plate XI., Fig. 2. On the outer aspect of the extremity of the ulna, is seen a new facet, smooth and polished, but not covered with cartilage. With this facet, the cuneiform bone was in apposition during life.

The supposition as to the cause of this arrest of growth on the part of the radius is, that the epiphysis of the latter was detached at an early period of life, and that the reunion was interfered with, either by inflammation or otherwise. The occurrence of suppurative inflammation, at the seat of a separation of an epiphysis from its shaft, is not at all infrequent, nor is the sequence of arrested growth of the bone so injured. Both these consequences are exemplified in the following interesting case. Mr. Hutchinson, *1st of April*, 1862.

Digitized by Google

14. *Detachment of the radial and ulnar (?) epiphyses, at the age of eight. Suppuration at the seat of injury: ankylosis of wrist: arrested growth of the bones.*

J. P., æt. 23, came under my care on account of a skin eruption, on November 19th, 1860. I noticed that one of his wrists was deformed. The right hand was bent over to the radial border, and firmly fixed by bony ankylosis at the wrist. There was not the slightest motion of the carpus on the radius. The wrist was thin and small, looking too small in proportion to the hand. It was considerably less in width than that of the other hand, but fully as thick, if not a little thicker. On his directing my attention to it, I noticed a small scar in the front of the joint. Being struck by the smallness of his wrist, I compared his arms, and found that both bones of the right forearm were an inch and a third shorter than those of the other side. The upper arms, and the hands of the two, were of similar size. The diminution was in the lower parts of the bones of the forearm.

The history of the case was, that at the age of nine, in playing at leapfrog, and "taking a seven-foot fly," he fell, and came with his hand violently on the ground. The wrist was supposed to be dislocated. It inflamed, and an abscess formed, which a surgeon opened, and a piece of bone came out "about as large as his finger-nail." In two or three months it had soundly healed, and has remained quite well ever since. The hand is so useful to him, that he is scarcely aware of any defect. It is his right hand, but he employs it as usual, and can write easily.

Putting together, the history of the accident, the supposed dislocation, the suppuration afterwards, the age of the boy at the time, and the subsequent arrest of growth of the bones, there can, I think, be little doubt, but that the injury was a separation of epiphyses. Very probably, the radial epiphysis was fissured longitudinally, and the joint became thus involved in the inflammation which followed. In consequence of the abscess, the nutrition of the epiphysis was, no doubt, greatly interfered with, and hence the arrest of growth of the bones.

Mr. HUTCHINSON, *1st of April*, 1862.

---

15. *Cases of Alopecia circumscripta, in which contagion occurred, and the presence of a cryptogam was demonstrated.*

Although the existence of a parasitic fungus on the skin, in cases of Alopecia areata (Porrigo decalvans), has been asserted by Bazin, Hardy,

Digitized by Google

and other continental writers; yet, I believe, no English observation confirmatory of their descriptions has been published.* On the other hand, statements to the effect, that after careful and repeated search, no fungus could be discovered in this disease, have been made by Dr. Jenner and several other British observers, including myself. With regard to the contagious properties of the disease, much incredulity has also existed. In the case now about to be related, there can, I think, be no reasonable doubt, that the disease spread by contagion. It is, also, the first in which I have been able to demonstrate the existence of a cryptogam.

In the father's case, and in the daughter's, the characters of the disease were exceedingly well-marked, the patches being simply bald and glossy, not in the least scurfy. In the boy's, however, although there were no broken hairs visible, the patch was not so smooth as is usual, there being a little desquamation.

Sporules of fungus were found in the epidermic scales, scraped from the patches of all three patients. Specimens were exhibited to the Society, which had been obtained from the father and the girl. The fungus was especially abundant on the girl's scalp. A month later, I again verified the observation, and also noted another interesting fact. On the father's arms, which were naturally rather hairy, were large patches completely destitute of hair, and perfectly smooth. On these, there was not the slightest scurfiness. By scraping, I detached some epidermic scales from these patches, and found in them fine specimens of fungus.

In each instance, the epidermic scales were placed in a very weak solution of potash before examination. With regard to the state of the hairs, I should state, that in most that were pulled out, I found the bulbs, as usual, wasted and tapering; but I could not discover any evidence of the presence of fungi, either in their shafts or bulbs. On the shafts, and at their terminal extremities, however, not infrequently a few sporules were seen adherent. The free extremities were, in a few instances, opaque, and broken up into fibres (brush-like), as is seen in the hairs of true ringworm, but this condition, in no instance, involved more than an exceedingly short portion at the end. The sporules were chiefly found either in or upon the epidermic scales, or floating free. But few thalli were seen.

The following are the particulars of the cases:—

Clinical history of the cases.—Mr. B., a robust man, æt. 48, with his

* The belief in the parasitic nature of this disease is fully adopted by Dr. McAll Anderson, in his interesting work "On the Parasitic Affections of the Skin;" but the illustration given is copied from Bazin, and is not original.

Digitized by Google

two children, Maria, æt. 10, and Frederick, æt. 7, was sent to me by Mr. Ballard in April, 1862. About four years ago, Mr. B. noticed his whiskers begin to fall out. The hairs fell gradually, but in abruptly defined patches. In about three months, the hair had fallen, almost over the whole chin and cheeks, but it was already beginning to grow again at the parts from which it had fallen. The patches were quite bare, "the skin as smooth as glass." He was not ill in the least. It next spread over the occiput, and then up to the vertex, and passed, in irregular patches, over the entire scalp. He was, for a time, almost totally bald, but always had some patches of hair. His eyebrows were not affected. On two patches on his right arm the hair fell.

His present condition is as follows:—His whiskers, beard, &c., are bushy, and as strong as ever, black, with a few scattered white hairs; eyebrows and eyelashes perfect. Entire scalp bald, except a thin scattering of white hairs over the vertex, and a tuft of black hairs on the right side near the ear. The occiput is totally bald and glossy. The white hairs on the vertex, although long, are very slender and ill-grown. He wears a wig. There is not the least scurfiness on any part.

The growth of *white* hairs on the scalp has, no doubt, been in part due to the patient's age; but that the baldness is caused by the disease, and is not senile, is proved by the fact of the occiput being totally denuded, whilst a tuft or two of black hair still exist on one part of the vertex.

About the same time that the father began to be affected, the girl also showed patches on the scalp. It spread rapidly, still keeping, most accurately the characters of alopecia. In three or four months she had become totally bald, and had lost her eyebrows also. She was in perfect health. After a while, the hair grew again in patches, and again fell off. At present, she is quite bald, excepting a little thin down over the whole, and two small tufts of strong black hair on the vertex. Her scalp is much thinned. By continued scraping, a little scurf may be obtained, but the scalp is, for the most part, smooth. Her father had, before the attack, a profuse growth of hair, beard, whiskers and scalp; and the child also had a luxuriant crop of black hair. Both eyebrows have fallen, and the skin is as smooth as possible on these parts. The eyelashes are perfect.

The boy has had only a single patch. It began three or four months ago. It is on the vertex, about the size of a halfpenny. The hair is already growing again, and the characters are not well-marked. There are no broken hairs as in ringworm.

Digitized by Google

The father was engaged as a silver-plater. He was quite unable to assign any cause for the disease, and stated that both himself and children had enjoyed excellent health throughout. They did not keep any tame animals, and he was not aware of any exposure to contagion.

Mr. HUTCHINSON, *15th of April*, 1862.

---

16. *Case of supposed hereditary syphilitic eruption appearing for the first time at the age of ten years.*

A girl came under my care, in the beginning of the year, with several circumscribed spots on the chest, of a light copper-colour, and affording delicate, very thin exfoliations of the cuticle. The appearance of the eruption being peculiar, I was led to inquire into the history of the case.

The mother, who before her marriage was perfectly healthy, had had nine children and one miscarriage. She had been twice married. Her first husband had died, as reported, of consumption. By him she had had one child only, which had the thrush when young, and died at the age of four years and a-half. The thrush went through the child, and at the of fifteen months, she had a rash in the groin. After the birth of this child, the mother experienced irritation in the vagina.

Five of the children by the second husband died, as they attained the age of fifteen or sixteen months. Soon after the confinement with her sixth child, the mother had a rash round the breast, and at the back of the knees.

One of the children of the second marriage is married, and appears to have been healthy. Another has attained the age of twenty, and has suffered from loss of hair, and eruptions on the head, face, and arms. The girl, whose case first attracted my attention, was ten years of age, and had had the eruption, represented in the drawing exhibited to the Society, for ten days only. Upon examining the mother, an eruption, similar in character, was seen at the bend of the left elbow-joint. The eruption on the two sisters yielded rapidly to the use of calomel baths. The condition of the incisor teeth was particularly noticed in the girl ten years of age. They do not present the condition which has been described as diagnostic of hereditary syphilis. But upon this point it may be observed, that even supposing, when the gums are affected with syphilis, during the development of the second set of incisors, the peg-shaped and notched condition of these teeth is produced; it by no means follows that the gums should always be the seat of this disease in syphilitic children.

Digitized by Google

Syphilis probably affects every organ in the body occasionally, but it does not always affect any one part. The growth and development of the teeth may, doubtless, be influenced by the disease, as may the nutrition of the skin, the mucous membranes, the bones, or the internal viscera; but it would be contrary to what we know of the laws of this disease, to assume that it always produces its specific influence upon any one organ.

Mr. H. Lee, *20th of May*, 1862.

XI. SPECIMENS FROM THE LOWER ANIMALS.

1. *Tubercle of the spleen, liver, and lungs of an Entellus monkey (Semnopithecus Entellus).*

This animal had been sometime in confinement; at the time of its death it was rather thin, but the loss of flesh did not correspond with the great amount of visceral lesion that existed.

The spleen weighed three ounces and two hundred and three grains, the average weight being from one-half to three-quarters of an ounce; it presented somewhat the appearance of the kidney of a bear or an otter. It was made up of about eighty cysts, most of them of an hexagonal form, and filled with a curd-like matter; a few of them contained sero-purulent fluid; the *trabeculæ* between these cysts were considerably thickened. The lungs and liver were also studded with the ordinary form of tubercle so common in this class of animals. The mesenteric glands were enlarged, and there were several tuberculous nodules on the intestines. The matter in the spleen-cysts contained a large amount of cholesterine plates, with the usual amorphous cells and granules of tuberculous deposit. The lung- and the liver-tubercles were composed of the same material. The blood also contained cholesterine, and the corpuscles were of a very irregular form and size. The pancreas, renal bodies, and other organs normal.

Remarks.—I have seen many cases of this description, in animals in confinement; and they tend, I think, to show that the blood-corpuscles are not formed in any particular organ. In the human subject we find sometimes, that life is supported under an enormous amount of disease, but this occurs to a much greater extent in the lower animals.

Dr. Crisp, *5th of November*, 1861.

Digitized by Google

2. *Chronic rheumatic arthritis of the shoulder-joint of a horse.*

No history is attached to this specimen. The bones were presented to Mr. Canton already macerated, and hence the state of the soft joint-textures is unknown; but the condition of the bones themselves is such as to offer no difficulty in believing that it has had its origin in those peculiarities of the system, to which the name of chronic rheumatic arthritis is given. The expansion and flattening of the articular surfaces of the humerus and scapula are well-marked (Plate XV.). The osteophytic growths around are the counterpart of those seen so frequently in the human subject. The incrusting cartilages are gone to a great extent, and the subjacent bone does not present the appearance which is natural to that part, but it is more worn, or smother, as though it had been rendered more even, and polished, by attrition during life.

To those, who have paid particular attention to the morbid anatomy of this strange affection, it is known that the malady may, and does, occur occasionally in some of the lower animals, although with these creatures there are many circumstances in connection with their habits, mode of life, nature and uniformity of their diet, &c., which would forbid the idea that they were prone to this disease. In writing to me on this subject, Dr. Robert Smith, of Dublin, states that he possesses specimens of the affection in the Irish elk (*Cervus Megaceros*), and which belonged to two different animals. In one, the disease is situated in one of the metacarpo-phalangeal joints, and shows beautifully the removal of the cartilage of incrustation, and the formation of the smooth, polished, ivory deposit on both the bones, and also, fine parallel grooves in the line of the flexion of the joint. In the other, one of the phalangeal joints is the seat of the affection. Here also the ivory deposit exists, and the grooves are very numerous and distinct. All the affected joints have numerous exostotic growths around them. In the Pathological Museum of Trinity College, there are the two elbow-joints of the great Sloth Bear, symmetrically affected with this disease.

Though the kindness of Messrs. Mavor, of Park Street, Grosvenor Square, I have had the opportunity of seeing, in their museum, a few specimens of this affection of the shoulder-joint in the horse. I find them, in all essential particulars, to correspond with that now brought before the Society. One example, however, deserves especial notice, and shows a condition sometimes to be seen in the human subject, viz., an ankylosis by invagination, as Cruveilhier has termed it. There is no union, or incorporation, as it were, of the two bones; but, they are held fixedly in contact by numerous large surrounding osseous growths,

Digitized by Google

Digitized by Google

DESCRIPTION OF PLATE XV.

The Figures illustrate Mr. Canton's case of Chronic Rheumatic Arthritis of the Shoulder-joint of a Horse (p. 270).

Fig. 1. The articulating surface of the head of the humerus.
Fig. 2. The corresponding articulating surface of the scapula.

Digitized by Google

Fig. 1

Fig. 2.

Digitized by Google

Lens Aldous delt.et lith.

Printed by Harrison & Sons, St Martins Lane.

Digitized by Google

which spring from around the margin of the articular surfaces, and dovetail with, or are fused into, one another. This state is also frequently seen in the vertebral column of the human subject.

Mr. CANTON, 21*st of January*, 1862.

---

3. *Enlarged renal bodies in a flamingo.*

The kidneys and renal bodies of a flamingo (*Phœnicopterus*), which died in March last, during the period of moulting. The capsules were of a bright-yellow colour, and weighed about thirty grains, their usual weight (judging from four examined) being from one to two grains. When the capsules were first seen, it was thought that the enlargement might be connected with seasonal change of plumage; but, on microscopical examination, it was found that, in addition to the refractive molecules so characteristic of the capsules of the lower animals, a large amount of fatty-matter was present, the increase of size arising partly from that cause. The colour of the bird could not be ascertained, as it died in the Docks, and the body only, without the skin, was purchased.

I may remark, that I have reason to believe that in birds and reptiles, during the period of seasonal change in the integuments of the body, certain alterations take place in the capsules, and their colour is more vivid—an opinion different from that which I formerly entertained.

Dr. CRISP, 20*th of May*, 1862.

---

4. *Description of a new parasite found in the heart of the edible turtle.*

While dissecting the heart of the common turtle, in August, 1860, I observed certain elongated, flattened, whitish bodies, upon the interior of the cavities, and on the valves; the number of the bodies was considerable, and they existed in all the chambers of the organ, but I had no opportunity of examining the blood-vessels. Their average length was a line and a-half, and the breadth about one-third. On examination with the microscope, I found them to be fluke-worms, which presented some novel features.

As may be seen in the engraving (Woodcut 21 A.), the body is indented at each side near its centre, so that the posterior segment was slightly longer than the anterior. It was furnished with an oral sucker, and a peculiar shaped ventral sucker was also determined. The oral sucker presented a somewhat radiated appearance, at first giving the idea of an armature of hooklets; but I have satisfied myself that no such armature

Digitized by Google

existed. The œsophagus was remarkably long and tortuous, leading to a double intestine, which at the outset formed two remarkable curves. The separate portions of intestine then passed down each side of the posterior segment of the body, and, as happens in other species of fluke-worms, ended in cæcal extremities. The intestine was of a deep-brown colour, from containing blood of the turtle, and I was able by pressure to expel some blood-discs. The space enclosed by the intestine was

Woodcut 21.

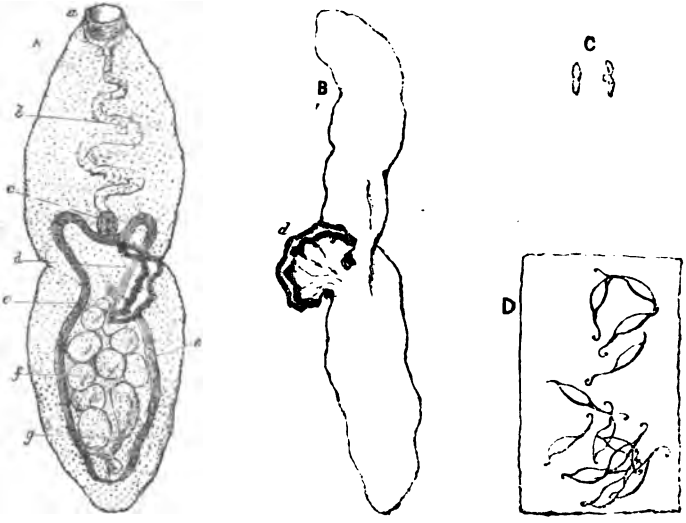

Represents parasites obtained from the edible turtle.

A. B. C. *Distoma constrictum*:—A, as seen on the ventral surface; B, in side view—in these figures magnified twenty diameters; C, of the natural size.

a, Oval sucker; *b*, œsophagus; *c*, œsophageal bulb; *d*, ventral sucker, folded; *e*, intestine; *f*, large cells; *g*, rudimentary organ (?).

D. Group of ova obtained from the blood, magnified twenty diameters.

occupied by large cells; no ova could be seen, but certain, apparently rudimentary, organs were detected. Under a high power of the microscope, the edges of the body appeared crenated. Dr. Cobbold, who has kindly examined the worms, informs me that they have not been described in any writings with which he is acquainted.

The circumstance of these immature worms being found in the heart,

Digitized by Google

would imply that they were in the act of migrating, as that can hardly be supposed to have been their resting-place.

As the identity of the worm is not certain, I would propose, as a provisional name for it, Distoma constrictum, taking the name constrictum from the central indentations.

It is an interesting circumstance, that I found, in blood from the heart which contained the worms, and also in that from another turtle's heart, certain minute fusiform ova (Woodcut 21 D.). The same kind of ova were found adhering to the eyes of several turtle, by Mr. E. Canton, and have been fully described by him in the *Dublin Journal for Medical Science*, for November, 1860.

Dr. Leared, *20th of May*, 1862.

---

5. *Disease in doves, simulating diphtheria.*

The specimens, on which the following communication is based, were sent to me, for exhibition to the Pathological Society, by my friend Mr. J. L. Jardine, of Capel. I can confirm, from my own examination, his account of the microscopical appearances of the morbid deposits. He writes as follows:—

"I enclose you a Pathological specimen, which I imagine may have some analogy to diphtheria. It is not from a human subject, but from a bird. About thirty doves, so tame as not to require caging, but accustomed to live in the open-air close to the house, were attacked one after the other; and all died, with the same symptoms, within three weeks or a month. They most of them fed moderately well, but many had evidently difficulty of swallowing, and most had difficult breathing. They usually then sat back, resting with their tails on the ground, and head and beak straight up in the air, the latter wide open.

"I had three of them to examine; and in the first, found a cheesy-mass (similar in nature to the enclosed) at the back of the hard palate, stopping up the posterior nares; and another mass at the exit from the crop of the 'proventriculus,' or continuation of œsophagus towards the gizzard.

"In the second, was the larger of the two bits I enclose to you; this was situated at the commencement of the œsophagus, and anteriorly, and had pushed the trachea on one side. I have cut into this piece to examine it. It has the muscular wall of the œsophagus anteriorly, and protrudes into its cavity.

"In the third dove, was only a small patch, three-quarters of an inch long and half-an-inch wide, in the œsophagus at its termination in the

Digitized by Google

gizzard, *beneath* the mucous membrane, and not protruding so as to offer any, or much, obstruction to the food passing by it. Yet the dove had become thin, though there was food in the gizzard here, as in the other two. There was no other disease anywhere in any of them. Microscopically, I find quantities of scaly epithelium, granular cells, oil, granular matter, and, I think, structureless fibrinous exudation. So that the likeness to diphtheria consists in the fatality, contagiousness (?) or epidemic character, and the exudation growth."

In answer to subsequent inquiries, the following additional information was obtained :—

"I do not know that there are any other particulars to be told, except that there is no human diphtheria about at all; that the doves lived in some trees near the house, which is on the summit of a small hill, and healthily situated; that the disease was confined to the alimentary tract, none being found in connection with the air-passages, unless that at back of the palate might be said to be so; and that each of the doves examined had *some food* in the stomach undergoing digestion, showing they were not starved. The lungs were crepitant and of a bright-vermilion colour. Most probably the scaly epithelium I saw was from the lining membrane of the œsophagus. The deposit (apparently to me) commenced *under* the mucous membrane."

Dr. Bristowe for Mr. J. L. Jardine, *20th of May*, 1862.

Digitized by Google

INDEX.

Abdomen, enormous distention of, from a severe burn - - 98
Abscess of the liver, consequent upon dysentery - - - 120
„ in neck, with epithelial cancer of larynx - - - 23
„ opening into œsophagus and bronchial tube - - - 74
Addison's disease - - 245, 247
Adipose transformation of kidney following calculus and abscess - 131
Alopecia circumscripta, contagion, and presence of a cryptogam 265
Amputation, hypertrophy and eburnation of the femur after - 175
Amyloid disease of liver and spleen 114
Anæmia lymphatica - - 219
„ ditto - - - - 227
Aneurism, cerebral apoplexy from rupture of - - - 2
„ of arch of aorta, fatal by ulceration of trachea - - - 35
„ and laceration of the ascending arch of the aorta - - 36
„ of descending thoracic aorta, etc., fatal by rupturing into left pleural sac - - - - 39
„ ditto, rupture into pleural cavity 44
„ of common iliac artery, showing fissures of internal coat - 33
„ of ham mistaken for abscess - 63
„ dissecting, of the aorta - 48
„ incipient, in case of atheromatous aorta - - - 55
„ tubular, of aorta, etc. - - 50
„ false, in cancer of axillary glands, etc. - - - - 229
Animals, specimens from the lower 269-273
Ankle, parts removed in excision of 181
Ankylosis of wrist and arrested growth in case of detachment of epiphyses 265
Anus, artificial, after operation for strangulated femoral hernia - 95
Aorta, communicating with both ventricles, open foramen ovale, etc. 42
„ atheromatous, aneurism, etc. - 55
„ dissecting aneurism of - 48
„ tubular aneurism of - - 50
„ arch of, aneurism of, fatal by ulceration of trachea - - 35
„ ditto, aneurism and laceration of 36
„ descending thoracic, aneurism of, fatal by rupture into left pleural sac - - - - 39
„ do., aneurism of, rupture into pleural cavity - - - 44
Aortic valves, malformation of - 63
Aortitis, supposed case of - 54
Apoplexy, cerebral, from rupture of aneurism - - - 2
„ meningeal - - - 1
„ ditto - - - - 8
Appendix vermiformis, disease of—peritonitis - - - 72
Arsenic, poisoning by,—ecchymosis of the heart - - - 54
Arteries, innominate and subclavian, tubular aneurism of - - 50
Artery, axillary, cancer of glands involving - - - 229
„ brachial, rupture of - - 56
„ right middle cerebral, apoplexy from rupture of aneurism of - 2
„ common iliac, aneurism of, showing fissures of internal coat - 33
„ pulmonary, contraction of the orifice of - - - 57
„ ditto, fibroid deposition in - 60
Arthritis, chronic rheumatic, of shoulder-joint of a horse - 270
Atrophy, acute, of the liver, three cases 107
„ of the spleen - - - 245
Axillary glands, cancer of, etc. - 229
Bag, membranous, said to have been passed from female bladder - 150
Barlow (Dr.), chronic ulcer of the pylorus, with induration of the pancreas - - - 85

Digitized by Google

Barwell (Mr.), parts removed in excision of the ankle - 181
„ rheumatic joint - - 184
„ — *report* on ditto, by Dr. Garrod and Mr. H. Thompson - 185
„ casts of diseased teeth - 255
„ see *C. Williams*.
Bennett (Dr. J. R.), cysts of echinococcus in the brain - - 5
„ cardiac disease—obstructed circulation fatal — insufficient post-mortem evidence of disease - 41
Bile-ducts, complete obstruction to 118
„ obliteration of, in an infant - 119
Bladder, membranous bag, said to have been passed from female - 150
„ medullary cancer of - - 157
Blood, extravasation of, into brain, with remains of an old coagulum - 7
„ extravasated, anomalous tumours of leg, consisting of - - 237
Bone, constituents of, in a case of mollities ossium - - 210
„ arrested growth of, in case of detachment of radial and ulnar epiphyses - - - 265
„ faulty union of, in fraction of os hyoides - - - 173
„ from the human eye - - 212
„ vomica of lung partially lined with 25
„ portion of, inhaled into trachea, and expectorated four months after 26
Bones, diseases, etc., of - 173-211
Brain, extravasation of blood into 7
„ cavity in, with remains of old coagulum - - - 7
„ cysts of echinococcus scoliciparens in - - - - - 5
„ softening of, in chorea - 19
„ red softening of, from obstruction of minute arteries by fibrine - 10
„ fibroid tumour in left hemisphere 17
„ waxy or amyloid tumour of - 3
Breast, atrophic scirrhus of - 223
„ cystic tumour of - - 220
Bright's disease, horse-shoe kidney affected with - - 132
Bristowe (Dr.), extreme hypertrophy of heart - - - 32
„ two cases of typhoid fever - 78
„ [seven] cases of acute necrosis, complicated by pyæmia - 188-210
„ *report* on Dr. Dickinson's case of fibroid deposition in wall of the heart - - - 62
„ see *Jardine*.
Broadbent (Dr. W. H.), aneurism of descending thoracic aorta — rupture into pleural cavity - 44
Broadbent, *continued*.
„ Disease of supra-renal capsules—tumour in spinal cord, chorea, and incipient bronzing - - 246
Bronchial tube, abscess opening into it 74
„ dilatation of - - - 28
Brown (Mr. Baker), *per Dr. Gibb*, unilocular ovarian tumour, successfully removed - - 169
Browne (Dr. J. H.), adipose transformation of the kidney, following calculus and abscess, opening through lumbar muscles - 131
Browning (Mr.), vomica of the lung partially lined with bone - 25
Burn, enormous distention of belly from a severe - - - 98
Cadge (Mr.), *per Mr. H. Thompson*, stone in the bladder, lithotomy, death - - - 126
„ *per ditto*, two large calculi, and portion of prostate removed in lithotomy - - - 155
Calculi, renal - - - 139
„ ureter obstructed by three - 158
„ numerous minute, in kidney - 158
„ two large, and portion of prostate removed in lithotomy - 155
Calculus in bladder, lithotomy, death 126
„ fragments of large, broken up by forceps, and removed by lithotomy 134
„ existence and growth of, in urethra for fifty years - - 140
„ impacted into calices of the pelvis of kidney - - - 155
Cancer of lower jaw - - 236
„ of the larynx and œsophagus - 28
„ of the axillary glands and artery—false aneurism, fatal hæmorrhage 229
„ of the ovaries and stomach - 172
„ of the three lower lumbar vertebræ 226
„ of the penis - - - 160
„ of the testicle - - - 166
„ in case of atheromatous aorta 55
„ colloid, of omentum, pancreas, spleen, bladder, cæcum &c. - 90
„ encephaloid, of lower jaw, rapidly developed, etc. - - 215
„ epithelial, of 12 years' standing successfully removed - - 214
„ — of interior of larynx - 23
„ — of the mucous membrane of urethra - - - 167
„ medullary, of the bladder - 157
„ — of liver - - - 100
„ — of stomach, with dropsy - 76

Digitized by Google

Canton (Mr. E.), aneurism and laceration of the ascending arch of the aorta - - - 36
„ syphilitic deposits in liver of an infant - - - 113
„ malposition of left kidney, and sigmoid flexure of colon - 147
„ syphilitic testicle, with nodes on the femur and tibia - - 161
„ genito-urinary organs and pelvis, from a case of Ectopia vesicæ 163
„ myeloid disease of the elbow-joint 213
„ anomalous tumours of the leg, consisting chiefly of extravasated blood - - - 237
„ fibroid degeneration of the capsule of the spleen - - 241
„ chronic rheumatic arthritis of shoulder-joint of a horse - - 270
Cardiac disease—see *Heart*.
Carter (Dr. H. V.), *per Mr. T. Holmes*, on the condition of the nerve-trunks in anæsthetic leprosy 13
Chorea and softening of the brain and spinal cord - - - 19
Circulation, Organs of, diseases etc. of - - 30-65
Cirrhosis of the liver - - 100
Colles' fracture of radius, case of 176-7
Colon, sigmoid flexure of, malposition - - - - 147
„ — perforation of, in typhoid fever 65
„ — stricture of - - 97
Conception, impregnated ovum discharged three to four weeks after 262
Cranium, syphilitic disease of - 8
„ syphilitic induration of bones of 177
Crisp (Dr.), atheromatous aorta, incipient aneurism, and cancerous disease - - - 55
„ perforation of the stomach from simple ulceration - - 93
„ scirrhous enlargement of the pancreas - - - 124
„ alteration of size and structure in the renal capsules - - 248
„ tubercle of spleen, liver, and lungs of an Entellus monkey - 269
„ enlarged renal bodies in a flamingo 271
„ see *Williams*.
Cryptogam, presence of, in case of Alopecia circumscripta - 265
Curgenven (Mr. J. B.), cancer of the ovaries and stomach - - 172
Curgenven, *continued*.
„ cancer of the three lower lumbar vertebræ - - - 226
Cyanosis, in case of malformation of the heart - - - 57
Cyst near bladder, fat removed during life from - - - 148
„ enormous, connected with the kidney, repeatedly tapped - 128
Cystic disease of the testicle - 167
Cysts, etc. - - 213-240
Cysts of echinococcus scoliciparíens in the brain - - - 5
David (Dr.), *per Dr. Gibb*, acute pericarditis, with great cardiac hypertrophy - - - 30
Degeneration, fatty, of heart, etc. 46
„ — of heart and liver, in case of enlarged lymphatic glands - 230
„ fibroid, of capsule of spleen - 241
„ waxy, observations on - 114
Diaphragm, rupture of, etc. - 70
„ syphilitic disease of - - 250
Dickinson (Dr.), syphilitic disease of cranium and dura mater—meningeal apoplexy - - 8
„ red softening of brain from obstruction of minute arteries by fibrine 10
„ fatty degeneration of the heart, with overloaded stomach, fatal at the age of three years - - 46
„ dissecting aneurism of the aorta 48
„ fibroid deposition in wall of the heart and in pulmonary artery 60
„ — *report*, on ditto, by Dr. Bristowe and Dr. Wilks - - 62
„ obstruction of the hepatic duct by hydatids, purpura - - 104
„ large abscess of the liver consequent upon dysentery - - 120
„ kidney distended into a large cyst, subsequently filled with colloid matter, mistaken in life for ovarian disease - - - 137
Digestion, Organs of, diseases, etc. of - - - 65-125
„ 1. Pharynx, œsophagus, stomach, and intestines - 65-100
„ 2. Liver and its appendages 100-125
Dilatation of the bronchial tubes 28
Diphtheria, extensive false membrane in - - - - 259
„ associated with parotitis - 261
„ disease in doves, simulating - 273
Diseases, etc., of the nervous system 1-22
„ of the organs of respiration 23-30
„ of the organs of circulation 30-65
„ of the organs of digestion 65-125

Digitized by Google

Diseases—Digestion, *continued*.
„ — 1. Pharynx, œsophagus, stomach, and intestines - 65-100
„ — 2. Liver and its appendages 100-125
„ of the genito-urinary organs 126-173
„ — 1. Kidneys, bladder, calculi, etc., 126-160
„ — 2. Genital organs, male 160-169
„ — 3. Ditto, female 169-173
„ of the osseous system - 173-211
„ of the organs of special sense 211-213
„ tumours, cysts, etc. - 213-240
„ ductless glands,— 1. The spleen 241-245
„ — 2. Supra-renal capsules 245-248
„ miscellaneous specimens 250-268
„ specimens from the lower animals 269-273
Dislocation, compound, of terminal phalanx of right thumb 180
Distention, enormous, of belly from a severe burn - - - 98
Doves, disease in, simulating diphtheria 273
Dropsy, in case of medullary cancer of stomach - - - 76
Ductus arteriosus, open - - 38
Dura mater, fibrous tumours of - 16
„ syphilitic disease of - - 8
„ syphilitic disease of - - 250
Durham (Mr.) cancerous disease of the testicle - - - 166
„ cystic disease of the testicle - 167
Dysentery, abscess of liver consequent upon - - - 120
Eburnation of the femur after amputation - - - - 175
Ecchymosis of the heart, in poisoning by arsenic - - - 54
Echinococcus scoliciparíens, cysts of, in the brain - - - 5
Ectopia vesicæ, genito-urinary organs from a case of - - 163
Elbow-joint, myeloid disease of - 213
Enchondroma of the lung - 27
„ of metacarpal bone and phalanges of the little finger - 185
Epiphyses, specimens of separation of 186
„ separation of, arrest of growth of radius from - - 264
„ detachment of radial and ulnar, ankylosis of wrist, etc. - 265
„ lower, of radius, separation of 182
„ lower of femur, separation of - 183
Erichsen (Mr.) aneurism of ham, mistaken for abscess - - 63
Excision of the ankle, parts removed in - - - - 181
Eye, bone from the human - 212
Eyeball, encephaloid tumour of - 211
Fat removed during life from a cyst near the bladder - - 148
Fatty degeneration of heart, with overloaded stomach, fatal at age of three years - - - 46
„ — of heart, liver, etc. - 230
Femur, hypertrophy and eburnation of, after amputation - - 175
„ acute necrosis of, pyæmia, death 198, 203, 205
„ separation of the lower epiphysis of 183
„ syphilitic nodes on - - 161
Fibrin, clot of, from right side of the heart - - - 59
„ from valves of the heart, red softening of the brain, from obstruction of minute arteries by - 10
Fibroid disease of the stomach - 83
Flamingo, enlarged renal bodies in 271
Foramen ovale, open - - 42
Forbes (Mr. J. G.) extravasation of blood into brain, with remains of an old coagulum - - 7
Fracture of the os hyoides - 173
„ of the radius, Colles', and of styloid process of ulna - 176-7
„ recent comminuted, of lower end of radius - - - 180
„ transverse, of sternum - 179
„ — of patella, united by ligamentous tissue - - - 178
Garrod (Dr.) *report* on Mr. Barwell's case of rheumatic joint - 185
Gaye (Mr.) *per Mr. H. Thompson*, Urinary organs, from patient a subject of Syme's operation for stricture - - - 169
Generation, Organs of, diseases, etc., of - - - 160-173
„ — male - - 160-169
„ — female - - 169-173
Genito-urinary organs and pelvis from a case of Ectopia vesicæ - 163
Gibb (Dr.), enormous distention of the belly from a severe burn - 98
„ horse-shoe kidney affected with Bright's disease - - 132
„ fracture of os hyoides; faulty osseous union - - - 173
„ constituents of bone, in a case of mollities ossium - - 210
„ hypertrophy of the spleen, with fibrous deposits in its convex surface - - - - 244
„ atrophy of the spleen - 245

Digitized by Google

GIBB, *continued.*
„ diphtheria associated with parotitis 261
„ *report* on Dr. M'Oscar's case of epithelial cancer of larynx - 24
„ see *Brown, David, M'Oscar, M'Whinnie.*
Glands, axillary, cancer of, etc. - 229
„ lymphatic, enlargement of - 227
„ ditto - - - 230
GLANDS, ductless, diseases of 241-248
GOODFELLOW (Dr.), fibroid tumour in brain, with disease of petrous portion of temporal bone - 17
„ chorea, softening of the brain and spinal cord - - - 19
„ atrophy of right kidney, from former distention of pelvis and calices by urine; hypertrophy of left kidney 143
„ left kidney extensively sacculated; minute calculi; obstruction of ureter, etc. - - - 158
Hæmorrhage into peritoneum, death from, in cancer of liver - 100
HARE (Dr.), extensive false membrane in diphtheria - - 259
„ *for Dr. Hearne,* six inches of ileum passed per anum, three months before death, intestines perfectly cicatrized - - - 86
HARLEY (Dr. G.), spontaneous rupture of the heart - - - 51
„ primary softening of the heart 52
„ stomach of a patient who died from the effects of bitter almond oil 95
„ complete obstruction to bile and pancreatic ducts - - 118
„ renal calculi - - - 139
„ uterus and its appendages, at the catamenial period - - 170
„ artificial jaundice - - 257
„ intense bronzing of the skin—healthy supra-renal capsules 262
HART (Mr. Ernest), bone from the human eye - - - 212
„ cystic tumour of the breast - 220
„ *report* on ditto, by Dr. John Ogle 222
„ atrophic scirrhus of the breast 223
HEARNE (Dr.) *per Dr. Hare,* six inches of ileum passed per anum, three months before death; intestines perfectly cicatrized - - 86
Heart, disease of, obstructed circulation, fatal - - - 41
„ ecchymosis of, in poisoning by arsenic - - - 54
Heart, *continued.*
„ fatty degeneration of, with overloaded stomach, fatal at the age of three years - - - 46
„ ditto - - - - 230
„ clot of fibrin from right side of 59
„ fibroid deposition in wall of - 60
„ hypertrophy of, with acute pericarditis - - - - 30
„ extreme hypertrophy of - 32
„ greatly enlarged, without valvular disease - - - 64
„ malformation of the, etc., cyanosis 57
„ spontaneous rupture of - 51
„ primary softening of - - 52
HEATH (Mr. Christopher), cancer of the larynx and œsophagus - 28
„ medullary cancer of the bladder 157
„ Colles' fracture of radius and of styloid process of the ulna - 177
Hepatic duct, obstruction of, by hydatids; purpura - - 104
Hernia, femoral, cast of - - 100
„ — strangulated, artificial anus after operation for - - 95
„ incarcerated, with ovarian tumour 75
HILLIER (Dr.), enlarged kidney with calculus impacted into calices of the pelvis - - - 155
„ enlargement of lymphatic glands and spleen—extreme fatty degeneration of heart and liver - 230
HOLMES (Mr. T.), tubular aneurism of the aorta, innominate and subclavian arteries - - - 50
„ specimens of separation of the epiphyses - - - 186
„ see *Carter.*
HOLT (Mr. B.), stricture of the urethra ruptured after death by the stricture dilator - - - 161
HOLTHOUSE (Mr. C.), transverse fracture of patella, united by ligamentous tissue - - - 178
„ compound incomplete lateral dislocation of terminal phalanx of right thumb - - - 180
„ large cystic tumour of the perinæum 233
„ — *report* on ditto, by Mr. Spencer Wells and Mr. Hulke - 235
„ cast of supposed rupture of rectus abdominis muscle - - 263
Horse, chronic rheumatic arthritis of shoulder-joint of - - 270
HULKE (Mr.), *report* on Mr. Holthouse's case of cystic tumour of perinæum 235

Digitized by Google

Humerus, acute necrosis of, recovery 209
Hutchinson (Mr. Jonathan), portion of bone inhaled into trachea and expectorated four months afterwards - - - 26
„ epithelial cancer of the mucous membrane of the urethra - 167
„ syphilitic induration of bones of the skull; cicatrices in liver 177
„ separation of the lower epiphysis of the radius - - - 182
„ separation of the lower epiphysis of the femur - - - 183
„ contagion between tinea tonsurans in a child, and pityriasis versicolor in a young adult - - 257
„ syphilitic psoriasis of the nails 259
„ diseased conditions of nails from inherited syphilis - - 260
„ arrest of growth of radius, probably from separation of its epiphysis 264
„ detachment of radial and ulnar epiphyses, ankylosis of wrist, arrested growth of bones - 265
„ Alopecia circumscripta, contagion and presence of a cryptogam 265
Hydatids, obstruction of the hepatic duct by; purpura - - 104
„ of liver, bursting into right pleura 111
Hydro-nephrosis, congenital - 151
Hyoid bone, fracture of - - 173
Hypertrophy of the femur, after amputation - - - 175
„ extreme, of heart - - 32
„ cardiac, with acute pericarditis 30
„ of the spleen, with fibrous deposits 244
Ileum, six inches of, passed per anum, intestines perfectly cicatrized 86
Induration of the pancreas - 85
„ syphilitic, of bones of cranium 177
Intestine, intus-suscepted portion of, 99
Jackson (Mr. T. Carr), Hypertrophy and eburnation of the femur after amputation - - 175
Jardine (Mr. J. L.) *per Dr. Bristowe*, disease in doves, simulating diphtheria - - - 273
Jaundice, artificial - - 257
Jaw, lower, cancer of - - 236
„ — encephaloid cancer of - 215
Joint, rheumatic - - - 184
Joints, see *ankle*, *elbow*, *hip*, *knee*.
Kidney, adipose transformation of, following calculus and abscess 131
Kidney, *continued*.
„ enlarged, with calculus impacted into calices of the pelvis - 155
„ ditto, in a flamingo - - 271
„ fatty - - - - 114
„ horse-shoe, affected with Bright's disease - - - 132
„ enormous sac connected with, repeatedly tapped - - 128
„ extensively sacculated, and with minute calculi - - 158
„ distended into a large cyst, subsequently filled with colloid matter 137
„ atrophy of right, and hypertrophy of left, from former distention of pelvis and calices by urine - 143
„ left, malposition of - - 147
„ — rupture of - - 70
Larynx, cancer of - - 28
„ epithelial cancer of interior of - 23
Leared (Dr.), new parasite from heart of the edible turtle - 271
Lee (Mr. H.), rupture of the brachial artery - - - 56
„ fragments of large stone, broken up by forceps and removed by lithotomy from a sacculated bladder 134
„ hereditary (?) syphilitic eruption, appearing first at age of ten years 268
Leg, anomalous tumours of, consisting of extravasated blood - 237
Leprosy, anæsthetic, condition of nerve-trunks in - - - 13
Lithotomy for calculus in bladder, death - - - 126
„ in case of large stone, broken up by forceps - - - 134
„ two large calculi, and portion of prostate removed in - 155
Little (Dr. W. J.) congenital hydro-nephrosis; artificial production of acute albuminous nephritis - 151
„ see *Mackenzie*.
Liver and its appendages, diseases of 100–125
„ commencing disease in, in case of encephaloid cancer of lower-jaw 215
„ abscess of, consequent upon dysentery - - - - 120
„ acute atrophy of, three cases - 107
„ medullary cancer and cirrhosis of 100
„ cavernous growth in - - 122
„ displacement into left pleura - 70
„ fatty degeneration of - - 230
„ fibrous deposit in, obstruction of hepatic veins by - - 122

Digitized by Google

LIVER, *continued.*
„ hydatid of, bursting into right pleura - - - 111
„ rupture of the - - 103
„ syphilitic disease of - - 250
„ waxy or amyloid disease of - 114
„ of an infant, syphilitic deposits in 113
Lung, enchondroma of the - 27
„ vomica of, partially lined with bone 25
Lymphatic glands, enlargement of, etc. 227
„ ditto, ditto - 230
MACKENZIE (Dr.) *per Dr. Little*, fibrous tumours of the dura mater - 16
„ *per ditto*, case of morbus Addisonii 247
McOSCAR (Dr.), *per Dr. Gibb*, epithelial cancer of interior of larynx, communicating with abscess in the neck - - - - 23
„ — *report* on ditto, by Dr. Gibb 24
McWHINNIE, (Mr.) *per Dr. Gibb*, nipple-like tumour removed from the thigh of a female - 218
Malignant disease, rapidly and extensively developed - - 217
Mania, acute, in case of typhoid fever 79
MAUNDER (Mr.) Intus-suscepted portion of the intestine - - 99
„ cast of femoral hernia - 100
„ membranous bag said to have been passed from female bladder - 150
„ — *report* on ditto, by Dr. Murchison and Mr. H. Thompson - 150
„ cancer of the axillary glands, involving the axillary artery; formation of a false aneurism and fatal hæmorrhage - - 229
Meningeal apoplexy - - 1
Menstruation, uterus, etc., at the period of - - - - 170
Metacarpal bone, enchondroma of 185
Mollities ossium, constituents of bone in a case of - - - 210
Monkey, Entellus, tubercle of spleen, liver and lungs of - - 269
MONTGOMERY (Dr. E.) morbus Addisonii - - - - 245
Morbus Addisonii - 245, 247
Mucous membrane of urethra, epithelial cancer of - - 167
MURCHISON (Dr.) cerebral apoplexy from rupture of aneurism of right cerebral artery - - 2
„ waxy or amyloid tumour of brain 3
„ perforation of sigmoid flexure in typhoid fever, with stercoraceous vomiting - - - 65
MURCHISON, *continued.*
„ rupture of diaphragm, displacement of liver and stomach, etc. - 70
„ medullary cancer and cirrhosis of the liver, death from hæmorrhage into peritonæum - - 100
„ two specimens of rupture of the liver - - - - 103
„ waxy or amyloid disease of liver and spleen, and fatty kidneys, etc. 114
„ hydatid of the liver bursting into the right pleura - 111
„ syphilitic disease of dura mater, liver and diaphragm - 250
„ *report* on Mr. Maunder's case of supposed membranous bag from female bladder - - 150
Muscle, rectus abdominis, cast of supposed rupture of - - 263
Myeloid disease of the elbow-joint 213
Nails, diseased conditions of, from inherited syphilis - - 260
„ syphilitic psoriasis of the - 259
Necrosis, cases of acute, complicated by pyæmia - - 188-210
„ of radius, acute, pyæmia, death 201
„ of femur, acute, pyæmia, death 198, 203, 205
„ of tibia, pyæmia, death - 194
„ — death from phthisis - 207
Nephritis, artificial production of acute albuminous - - - 151
Nerve-trunks, condition of, in anæsthetic leprosy - - 13
NERVOUS SYSTEM, diseases, etc., of 1-22
NEWMAN (Dr. W.), see *Harley* (spontaneous rupture of the heart).
NUNN (Mr.), casts of teeth illustrative of hereditary syphilis - 258
NUNNELEY (Mr.), aorta communicating with both ventricles, open foramen ovale, etc. - - - 42
„ rupture of the stomach - 72
„ disease of the appendix vermiformis peritonitis - - 72
„ stricture of œsophagus, with abscess opening into it and bronchial tube 74
„ large inflamed fibro-cystic ovarian tumour with incarcerated hernia 75
„ large epithelial cancer of twelve years' standing, successfully removed - - - 214
„ encephaloid cancer of the lower jaw, rapidly developed, with suppuration and pyelitis - 215

Digitized by Google

NUNNELEY, *continued.*
„ rapidly and extensively developed malignant disease - - 217
Obliteration of the biliary ducts in an infant - - - 119
OBRE (Mr. Henry), clot of fibrin removed from the right side of the heart - - - 59
„ encephaloid tumour of the eyeball 211
Obstruction of the hepatic veins and vena cava by fibrous deposit in liver - - - 122
„ complete, to bile and pancreatic ducts - - - 118
O'CONNOR (Dr.), colloid cancer of omentum, pancreas, spleen, bladder, cæcum, etc. - - 90
Œsophagus, cancer of - - 28
„ stricture of, with abscess opening into it - - - 74
„ infiltrated scirrhous stricture of 71
OGLE (Dr. John), *report* on Mr. E. Hart's case of cystic tumour of the breast - - - 222
Oil, bitter almond, stomach of a patient who died from the effects of 95
ORGANS OF SPECIAL SENSE, diseases, etc., of - - - 211-213
Os hyoides, fracture of, and faulty union - - - 173
OSSEOUS SYSTEM, diseases, etc., of 173-211
Ovarian disease, large cyst of kidney mistaken for, in life - - 137
„ tumour, fibro-cystic, inflamed 75
„ — unilocular, successfully removed 169
„ — removed by ovariotomy - 172
Ovaries, cancer of - - 172
Ovariotomy - - - 172
Ovum, impregnated, discharged three to four weeks after conception 262
Pancreas, induration of the - 85
„ scirrhous enlargement of - 124
Pancreatic ducts, complete obstruction to 118
Parasite, new, from the heart of the edible turtle - - 271
Parotitis, diphtheria associated with 261
PART (Dr.), artificial anus after operation for strangulated femoral hernia - - - 95
PARTRIDGE (Mr.), transverse fracture of sternum, at junction with cartilages of third rib - - 179
„ chronic thickening of anterior part of shaft of tibia - - 179
„ recent comminuted fracture of lower end of radius - - 180
Patella, transverse fracture of, united by ligamentous tissue - 178
PEACOCK (Dr.) open ductus arteriosus 38
„ large aneurism of descending thoracic aorta, pressure on recurrent laryngeal nerve, etc. - 39
„ malformation of the heart, contraction of pulmonary artery, etc., cyanosis - - - 57
„ greatly enlarged heart without valvular disease - - 64
„ stricture of the sigmoid flexure of the colon - - - 97
Pelvis from a case of Ectopia vesicæ 163
Penis, cancer of the - - 160
Perforation of stomach from simple ulceration - - - 93
Pericarditis, acute, with great cardiac hypertrophy - - - 30
Perinæum, large cystic tumour of 233
Peritoneum, death from hæmorrhage into, in cancer of liver - 100
Peritonitis in case of disease of appendix vermiformis - - 72
Phalanges of the little finger, enchondroma of - - - 185
Phalanx of right thumb, compound dislocation of - - 180
Phthisis, death from, in case of necrosis of tibia - - - 207
Pityriasis versicolor in young adult and tinea tonsurans in a child, contagion between - - 257
Pleura, right, hydatid of liver bursting into - - - 111
Prostate, portion of, removed in lithotomy - - - 155
Psoriasis, syphilitic, of the nails - 259
Purpura, in case of obstruction of hepatic duct by hydatids - 104
Pyæmia, complicating cases of acute necrosis - - 188-210
Pyelitis, in case of encephaloid cancer of lower jaw - - - 215
Pylorus, chronic ulcer of - - 85
QUAIN (Dr.), see *Wilkes.*
Radius, arrest of growth of, probably from separation of its epiphysis 264
„ separation of lower epiphysis of 182
„ case of Colles' fracture of - 176-7
„ recent comminuted fracture of lower end of - - - 180
„ acute necrosis of, pyæmia, death 201
RESPIRATION, ORGANS OF, diseases, etc., of - - - 23-30
Rheumatic joint - - 184

Digitized by Google

Robinson (Dr. F.), aneurism of arch of the aorta—fatal by ulceration of trachea - - - 35
„ medullary cancer of stomach, with dropsy - - - 76
Rupture of the brachial artery - 56
„ of diaphragm, etc. - - 70
„ spontaneous, of the heart - 51
„ of the liver - - - 103
„ of the stomach - - 72
Schulhof (Dr.) impregnated ovum discharged three to four weeks after conception - - - 262
Scirrhous enlargement of the pancreas 124
Scirrhus, atrophic, of the breast - 223
Sense, Organs of Special, diseases, etc., of - - 211-213
Septum ventriculorum, deficiency in 57
Shillitoe (Mr. Buxton), infiltrated scirrhous stricture of the œsophagus - - - 71
Sigmoid flexure of colon, malposition of - - - - 147
„ — perforation of, in typhoid fever 65
„ — stricture of - - - 97
Skin, incipient bronzing of, in disease of supra-renal capsules - 246
„ intense bronzing of, healthy supra-renal capsules - - 262
Softening of brain and spinal cord, in chorea - - - 19
„ primary, of the heart - - 52
Specimens, (Miscellaneous), including malformations, effects of poisons, morbid states, diphtheria, etc. - - - 250-268
Specimens from the Lower Animals - - 269-263
Spinal Cord, softening of, in chorea 19
Spleen (The) diseases of 241-245
„ amyloid disease of - - 114
„ atrophy of the - - 245
„ enlargement of, etc. - - 230
„ fibroid degeneration of capsule of 241
„ hypertrophy of, with fibrous deposits on its convex surface - 244
Sternum, transverse fracture of - 179
Stomach of a patient who died from the effects of bitter almond oil - 95
„ cancer of - - - 172
„ medullary cancer of, with dropsy 76
„ displacement into left pleura 70
„ fibroid disease of - - 83
„ perforation of, from simple ulceration - - - - 93
Stomach, *continued.*
„ rupture of - - - 70
„ — ditto - - - 72
Stone—see *Calculi.*
Stricture dilator, character of rupture of stricture by - - 161
„ urinary organs, from a subject of Syme's operation for - 169
„ of sigmoid flexure of the colon 97
„ see *Œsophagus, Rectum, Urethra.*
Supra-renal Capsules, diseases of 245-248
„ disease, chorea and incipient bronzing - - - - 246
„ alteration of size and structure 248
„ healthy, intense bronzing of the skin - - - - 262
Syme's operation for stricture, urinary organs from a subject of - 169
Syphilis, hereditary, casts of teeth illustrative of - - - 258
„ inherited, diseased conditions of nails from - - - 260
Syphilitic deposits in the liver of an infant - - - 113
„ disease of cranium and dura mater 8
„ — of dura mater, liver and diaphragm - - - 250
„ eruption, hereditary (?), appearing first at age of ten years - 268
„ induration of bones of the skull 177
„ psoriasis of the nails - - 259
„ testicle with nodes on the femur and tibia - - - 161
Teeth, casts of diseased - - 255
„ casts of, illustrative of hereditary syphilis - - - 258
Temporal bone, disease of petrous portion - - - - 17
Testicle, cancerous disease of - 166
„ cystic disease of - - 167
„ syphilitic, with nodes on the femur and tibia - - - 161
Thompson (Mr. H.), *report* on Mr. Maunder's case of supposed membranous bag from female bladder 150
„ *report* on Mr. Barwell's case of rheumatic joint - - 185
„ see *Cadge, Gaye, Thompson (Jos.) Trouncer.*
Thompson (Mr. Joseph), *per Mr. H. Thompson*, enormous sac connected with the kidney, repeatedly tapped - - - 128
Thumb, phalanx of right, compound dislocation of - - 180
Tibia, chronic thickening of anterior part of shaft of - - 179

Digitized by Google

Tibia, *continued.*
„ necrosis of, pyæmia, death - 194
„ — death from phthisis - 207
„ syphilitic nodes on - - 161
Tinea tonsurans in a child, and pityriasis versicolor in young adult, contagion between - - 257
Tissue, true ligamentous, union by in fracture of patella - - 178
Trachea, portion of bone inhaled into, and expectorated four months after - - - 26
Trouncer (Dr.) *per Mr. H. Thompson*, cancer of the penis - - 160
Tubercle of spleen, liver and lung, of an Entellus monkey - - 269
Tumours, cysts, hydatids, etc. 213-240
Tumours, anomalous, of leg, consisting chiefly of extravasated blood 237
„ in spinal cord, in disease of suprarenal capsules - - 246
„ nipple-like from the thigh of a female - - - 218
„ of brain, amyloid - - 3
„ cystic, of the breast - - 220
„ large of perinæum - - 233
„ encephaloid, of the eyeball - 211
„ fibroid, in brain, with disease of temporal bone - - 17
„ fibrous, of the dura mater - 16
„ ovarian, removed by ovariotomy 172
„ — unilocular, successfully removed 169
„ — fibro-cystic, large inflamed 75
Turtle, edible, new parasite from the heart of - - - 271
Typhoid fever, two cases of - 78
„ in the seventieth year of age - 68
„ perforation of sigmoid flexure in, 65
Ulcer, chronic, of pylorus, with induration of the pancreas - - 85
Ulceration, perforation of the stomach from simple - - 93
Ulna, fracture of styloid process of 176-7
Ureter, obstructed by three calculi 158
Urethra, existence and growth of calculus in, for fifty years - 140
„ epithelial cancer of mucous membrane of - - - 167
„ stricture of, ruptured after death by the stricture dilator - - 161
Urinary Organs, diseases, etc., of 126-173
„ from patient, a subject of Syme's operation for stricture - 169
Uterus and appendages, at the catamenial period - - 170
Valves, aortic, malformation of - 63
Veins, hepatic, obstruction of, by fibrous deposit - - 122
Vena cava, obstruction of, by fibrous deposit in liver - - 122
Vertebræ, lumbar, cancer of the three lower - - - 226
Viscera, deposits in, in enlargement of lymphatic glands - 227
Vomiting, stercoraceous, in case of perforation of sigmoid flexure 65
Walton (Mr. Haynes), existence and growth of a calculus in urethra for fifty years - - 140
Waxy degeneration, observations on 114
„ disease of liver and spleen - 114
Wells (Mr. Spencer) ovarian tumours removed by ovariotomy - 172
Wilks (Dr. Samuel) enchondroma of the lung - - - 27
„ dilatation of the bronchial tubes 28
„ aneurism of common iliac artery, showing fissures of internal coat 33
„ ecchymosis of the heart, in poisoning by arsenic - - 54
„ typhoid fever in the seventieth year of age - - - 68
„ fibroid disease of the stomach 83
„ cases of acute atrophy of the liver 107
„ obliteration of the biliary ducts in an infant - - - 119
„ obstruction of hepatic veins and vena cava by fibrous deposit in liver - - - 122
„ specimens of cavernous growth in the liver - - - 122
„ fat removed during life from a cyst near the bladder - - 148
„ enlargement of lymphatic glands, with deposits in the viscera—anæmia lymphatica - - 227
„ *report* on Dr. Dickinson's case of fibroid deposition in wall of the heart - - - 62
Wilkes (Mr. W. D.) *per Dr. Quain*, cancer of lower jaw - - 236
Williams (Mr. C.) *per Dr. Crisp*, supposed case of aortitis - 54
„ *per Mr. Barwell*, malformation of aortic valves - - 63
„ *per ditto*, enchondroma of metacarpal bone and phalanges of little finger - - - 185
„ *per ditto*, anæmia lymphatica - 219
Wood (Mr. John), meningeal apoplexy 1
„ Case of Colles' fracture of the radius and of styloid process of ulna 176

Digitized by Google

Digitized by Google

Digitized by Google

UNIVERSITY OF MICHIGAN
3 9015 07021 3361

Digitized by Google

Digitized by Google